



PATIENT

Steele MacKinnon

SPECIES

Canine

BREED

Bernese Mountain
Dog

SEX

F/S

AGE

6 years

WEIGHT

43 kg.

INTERPRETED BY

R. McKenzie Daniel,
DVM, DABVP
(Canine and Feline)

**IMAGING
PERFORMED BY**

Dave Stasiuk RDMS,
RDCS

HOSPITAL NAME

Alpine 24/7

REFERRING VET

Dr. Bruce

INVOICE

15281

DATE

10/27/22

PRESENTING CLINICAL SIGNS

Mast cell tumour on leg. Assess for abdominal mets. Recent diarrhea.

ULTRASONOGRAPHIC EXAMINATION OF THE ABDOMEN

Urinary System

The urinary bladder, trigone, cystourethral junction, and visible pelvic urethra to a depth of 3.0 cm exhibited normal thickness and tone. Anechoic urine was present in the lumen with no uroliths or sediment. The ureteral papillae were normal. The ureters were not visible which is normal. No evidence of inflammatory or neoplastic changes was noted.

The area of the aortic trifurcation was free of pathology including no evidence of medial Iliac or sublumbar lymphadenopathy.

Normal size and margination were present in the kidneys. A normal 1:3 cortex / medulla ratio and normal corticomedullary definition were maintained. The echogenicity of the cortex was similar to or slightly less than normal liver parenchyma while the medulla echogenicity was hypoechoic to the cortex with no evidence of pelvic dilation. The left kidney measured 6.5 cm in length. The right kidney measured 6.7 cm in length.

Adrenal Glands

The left adrenal gland exhibited potential for mild subjective subnormal size, given breed and body weight. The left adrenal gland measured 0.55 cm width at the caudal pole and 0.4 cm width at the cranial pole. This is likely a normal patient variant. The right adrenal gland was not definitively visualized.

Spleen

The spleen exhibited a finely textured and homogenous parenchyma which was hyperechoic to the liver and renal cortical parenchyma. The capsule was smooth and regular without apparent expansion. The splenic vasculature at the hilus was normal in volume with no evidence of congestion or thrombosis. Acute to chronic inflammatory, neoplastic, or benign parenchyma changes were not noted.

Liver/ Gallbladder

The liver was subjectively normal in size, structure, and contour. The liver parenchyma was uniform and hypoechoic to the spleen with a mild coarse echotexture. The hepatic and portal vasculature were normal in appearance without signs of congestion. The gallbladder was non-distended in size with thin walls and primarily anechoic luminal content. The cystic and common bile ducts were normal.

Gastrointestinal

The stomach presented intact wall layering with a normal wall layer ratio. The lumen of the stomach contained mild to moderate ingesta exhibiting mild progressive distal acoustic shadowing, likely consistent with recent meal ingestion.

The small intestine presented intact wall layering with 1:3 muscularis/mucosa ratio. The lumen of the small intestine was empty with no signs of ileus, obstruction, or foreign material.



PATIENT

Steele MacKinnon

Normal visible colon wall layers were present with subjective semi-formed to possible soft fecal matter.

SPECIES

Canine

Pancreas

The parenchyma of the left limb, body, and right limb of the pancreas presented isoechoic to the adjacent omental fat. A normal curvilinear capsule contour of the pancreas was present. The visible pancreatic duct was normal. No signs of active inflammation or neoplastic disease were evident.

BREED

Bernese Mountain Dog

Free Abdomen

No omental masses, lymphadenopathy, or evidence of peritoneal free fluid were noted.

SEX

F/S

ULTRASONOGRAPHIC FINDINGS

- Sonographically unremarkable abdomen

AGE

6 years

INTERPRETATION OF THE FINDINGS & FURTHER RECOMMENDATIONS

No evidence of intraabdominal primary vs. metastatic neoplastic criteria or evidence of gastroenterocolic pathology. Sonographic monitoring of the abdomen based on oncology recommendations is suggested. As-needed GI support and therapy for diarrhea is recommended.

WEIGHT

43 kg.

Although considered unlikely, resting cortisol level to rule out occult Addison's Disease, may be considered if persistent or recurrent diarrhea.

INTERPRETED BY

R. McKenzie Daniel,
DVM, DABVP
(Canine and Feline)

IMAGING PERFORMED BY

Dave Stasiuk RDMS,
RDCS

HOSPITAL NAME

Alpine 24/7

REFERRING VET

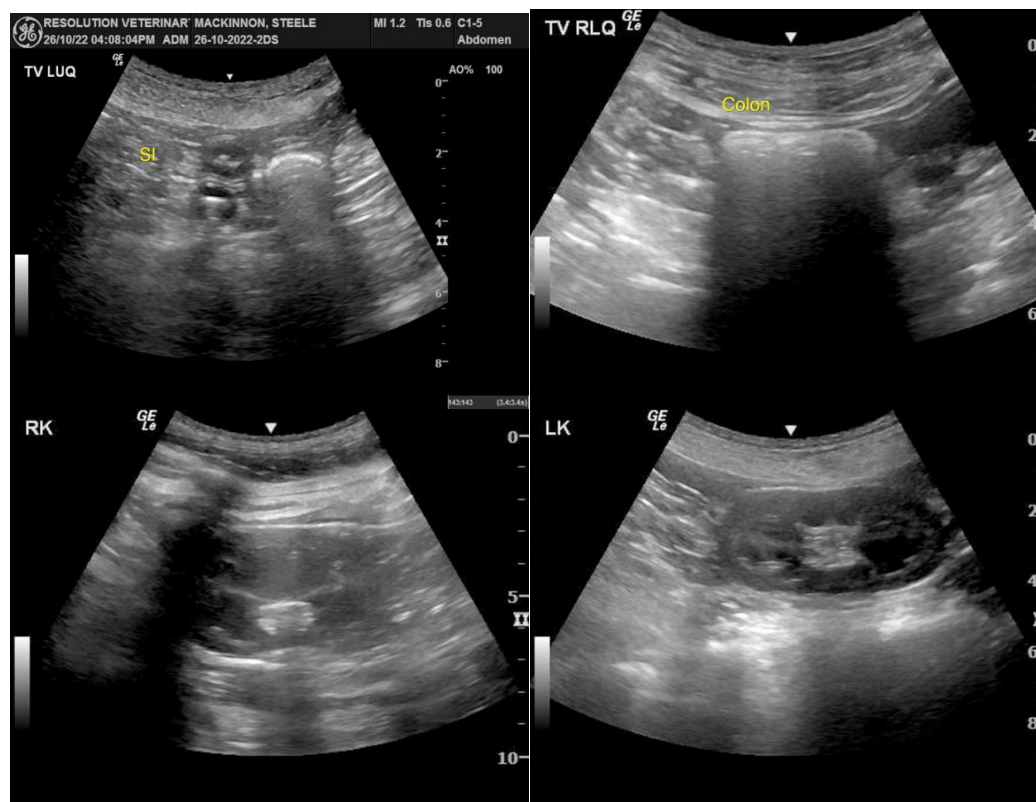
Dr. Bruce

INVOICE

15281

DATE

10/27/22





PATIENT

Steele MacKinnon

SPECIES

Canine

BREED

Bernese Mountain
Dog

SEX

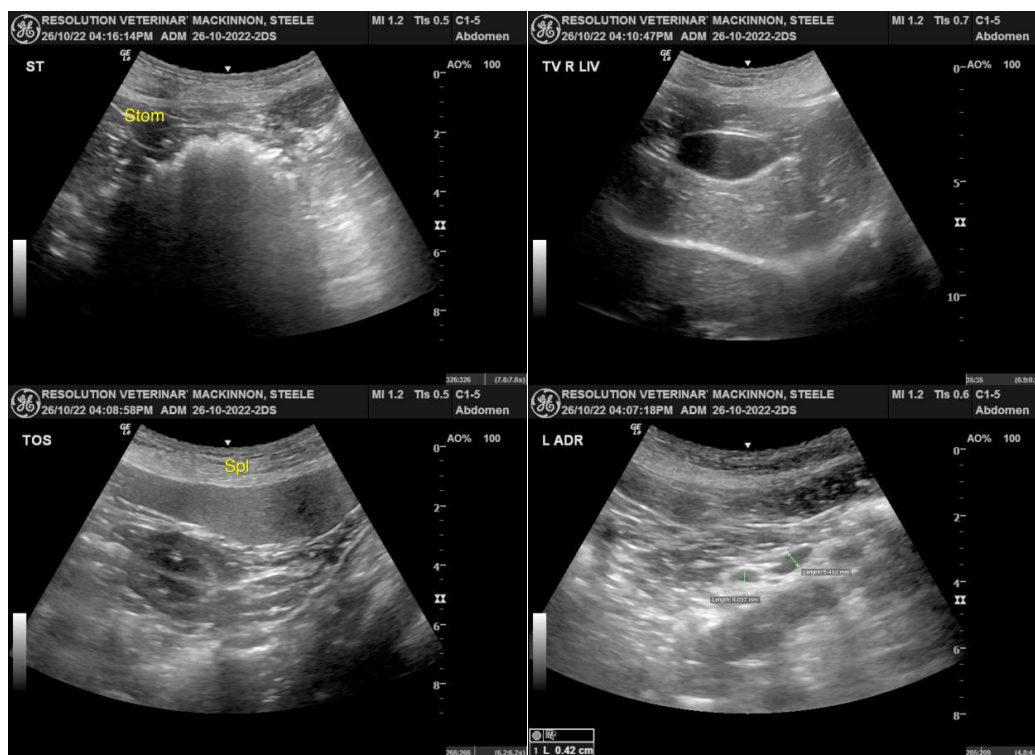
F/S

AGE

6 years

WEIGHT

43 kg.



INTERPRETED BY

R. McKenzie Daniel,
DVM, DABVP
(Canine and Feline)

**IMAGING
PERFORMED BY**

Dave Stasiuk RDMS,
RDMS

HOSPITAL NAME

Alpine 24/7

REFERRING VET

Dr. Bruce

INVOICE

15281

DATE

10/27/22

The information and recommendations provided are based on the images presented by the referring veterinarian/sonographer. No evaluation can be communicated regarding pathology that was not visible in the image/video clips provided.

Thank you for this referral. If the clinical or image interpretation does not parallel your findings or if I can be of any further assistance please contact me.

R. McKenzie Daniel, DVM, DABVP (Canine / Feline Practice)
info@SonoPath.com