



**PATIENT**

Gabby Heabner

**PRESENTING CLINICAL SIGNS**

History: Recheck

Medication: Spironolactone 12.5 BID, PotGlucon 1meq

**SPECIES**

Feline

Current Medications- Spironolactone and Potassium Gluconate

**ULTRASONOGRAPHIC EXAMINATION OF THE ABDOMEN**

**BREED**

Domestic Shorthair

**Urinary System**

The urinary bladder, trigone, cystourethral junction, and visible pelvic urethra to a depth of 2.0 cm exhibited normal thickness and tone. Anechoic urine was present in the lumen with no uroliths or sediment. The ureteral papillae were normal. The ureters were not visible which is normal. No evidence of inflammatory or neoplastic changes was noted.

**SEX**

FS

The area of the aortic trifurcation was free of pathology.

**AGE**

14 years

Normal size and margination were present in the kidneys. A normal 1:3 cortex / medulla ratio was maintained. The medulla and cortices were uniform in texture with some increased echogenicity and moderate loss of corticomedullary symmetry and definition expected for the age of the patient. Focal areas of increased cortex echogenicity, consistent with previously noted cortical infarctions, were present. No evidence of pelvic dilation was present. The left kidney measured 3.3 cm in length. The right kidney measured 3.6 cm in length.

**WEIGHT**

12.4 Pounds

**Adrenal Glands**

The left adrenal gland exhibited subjective static enlargement measuring approximately 1.0 cm in diameter. The left adrenal gland maintained symmetrical capsule contour with primarily homogeneous parenchyma without evidence of parenchymal mineralization.

The right adrenal gland was uniform in size and contour with a uniformly hypoechoic parenchyma. The right adrenal gland measured 0.42 cm width.

**INTERPRETED BY**

R. McKenzie Daniel,  
 DVM, DABVP  
 (Canine and Feline)

**IMAGING PERFORMED BY**

Rebekah Jakum, CVT  
 ARDMS/RVT

**HOSPITAL NAME**

Maple Hills VH

**REFERRING VET**

Dr. Banzhof

**Spleen**

The spleen exhibited a finely textured and homogenous parenchyma which was hyperechoic to the liver and renal cortical parenchyma. The capsule was smooth and regular without apparent expansion. The splenic vasculature at the hilus was normal in volume with no evidence of congestion or thrombosis. Acute to chronic inflammatory, neoplastic, or benign parenchyma changes were not noted.

**Liver/ Gallbladder**

The liver was subjectively normal in size, structure, and contour. The liver parenchyma was mildly nonuniform and hypoechoic to the spleen with a moderate coarse echotexture and subjective mild to benign parenchymal remodeling. The hepatic and portal vasculature were normal in appearance without signs of congestion. The gallbladder was non-distended in size with minor gallbladder debris. The cystic and common bile ducts were normal.

**INVOICE**

12465

**DATE**

10.27.2021



**PATIENT**

Gabby Heabner

***Gastrointestinal***

The stomach presented intact wall layering with a normal wall layer ratio. The lumen of the stomach was empty with no signs of ileus, obstruction, or foreign material. The gastric body wall width measured 0.25 cm.

**SPECIES**

Feline

The small intestine presented intact wall layering with 1:3 muscularis/mucosa ratio. The lumen of the small intestine was empty with no signs of ileus, obstruction, or foreign material. The duodenum wall width measured 0.28 cm.

**BREED**

Domestic Shorthair

Normal visible colon wall layers were present with apparent formed feces in lumen.

**SEX**

FS

***Pancreas***

The pancreas exhibited generalized prominent size with asymmetrical contour. The pancreas presented a heterogeneous to mildly hypoechoic parenchyma noted throughout the pancreas with a previously noted cystic lesion in the mid to distal aspect of the left pancreatic limb. The lesion measured 1.7 cm in diameter. Primarily anechoic content with mild cellular component was present within the cystic lesion. No overt evidence of peripancreatic reactive mesentery was noted.

**AGE**

14 years

***Free Abdomen***

No overt lymphadenopathy or peritoneal effusion was present.

**WEIGHT**

12.4 Pounds

**ULTRASONOGRAPHIC FINDINGS**

**INTERPRETED BY**

R. McKenzie Daniel,  
 DVM, DABVP  
 (Canine and Feline)

***Primary Findings***

- Static chronic renal changes with previously noted small cortical infarctions
- Static, subjectively enlarged left adrenal gland
- Prominent heterogeneous to mildly hypoechoic pancreas with static left limb cystic lesion

**IMAGING PERFORMED BY**

Rebekah Jakum, CVT  
 ARDMS/RVT

**INTERPRETATION OF THE FINDINGS & FURTHER RECOMMENDATIONS**

Assuming normal clotting status, ultrasound-guided FNA of the left pancreatic limb cystic lesion for cytology +/- Centesis with fluid analysis +/- culture and sensitivity, if clinically indicated, could be considered. Neoplastic process associated with the left pancreatic limb is considered unlikely at this time, given the overall static appearance of the cystic lesion without evidence of progression.

**HOSPITAL NAME**

Maple Hills VH

**REFERRING VET**

Dr. Banzhof

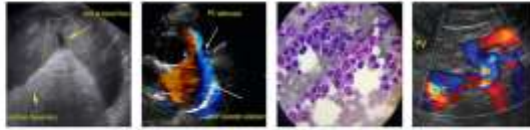
Continued monitoring of systemic blood pressure and/or aldosterone levels if not previously done is suggested, given the difficulty in the management of hypokalemia. Empirically, continued potassium supplementation is indicated. Sonographic monitoring of both the left pancreatic cystic lesion and the left adrenal gland with recheck in 3 months is suggested.

**INVOICE**

12465

**DATE**

10.27.2021



**PATIENT**

Gabby Heabner

**SPECIES**

Feline

**BREED**

Domestic Shorthair

**SEX**

FS

**AGE**

14 years

**WEIGHT**

12.4 Pounds

**INTERPRETED BY**

R. McKenzie Daniel,  
DVM, DABVP  
(Canine and Feline)

**IMAGING PERFORMED BY**

Rebekah Jakum, CVT  
ARDMS/RVT

**HOSPITAL NAME**

Maple Hills VH

**REFERRING VET**

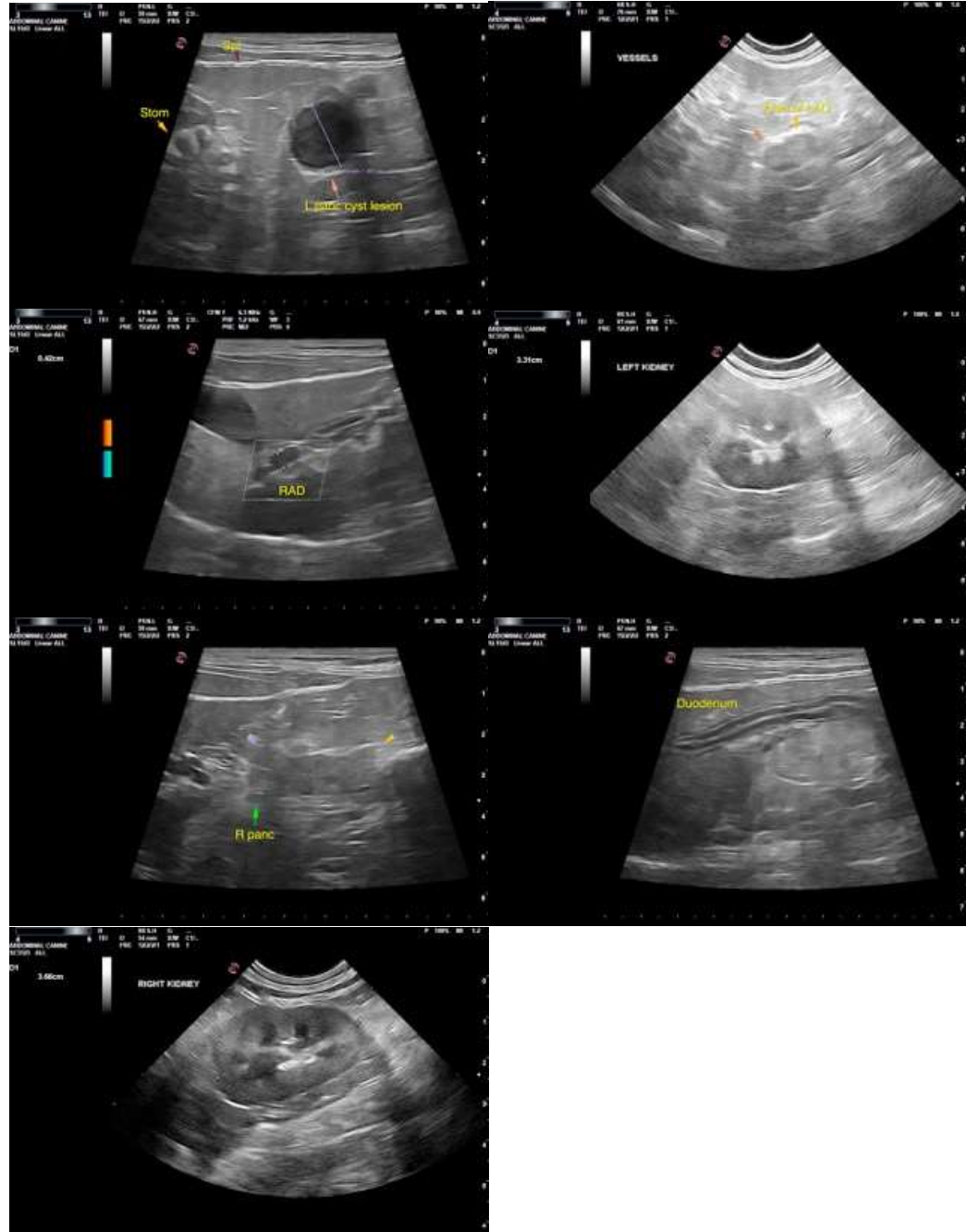
Dr. Banzhof

**INVOICE**

12465

**DATE**

10.27.2021



The information and recommendations provided are based on the images presented by the referring veterinarian. No evaluation can be communicated regarding pathology that was not visible in the image/video clips provided.

Thank you for this referral. If the clinical or image interpretation does not parallel your findings or if I can be of any further assistance please contact me.

**R. McKenzie Daniel, DVM, DABVP (Canine/Feline Practice)**  
[mac.daniel@sonopath.com](mailto:mac.daniel@sonopath.com)