



**PATIENT**

Oliver Danielson

**SPECIES**

Feline

**BREED**

DSH

**SEX**

MN

**AGE**

6

**WEIGHT**

4 kg

**INTERPRETED BY**

R. McKenzie Daniel,  
DVM, DABVP  
(Canine and Feline)

**IMAGING PERFORMED BY**

Dr. Belan,  
Dr. Barthelemy

**HOSPITAL NAME**

Glamorgan Animal  
Clinic

**REFERRING VET**

Dr. MacAulay

**INVOICE**

15248

**DATE**

10/25/22

**PRESENTING CLINICAL SIGNS**

Patient was from a rescue and concern he may be a cryptorchid. Elevated Ca possible PU PD  
Abnormal PE/Chem/CBC/UA Results:      Hypercalcemia T4 normal

**ULTRASONOGRAPHIC EXAMINATION OF THE ABDOMEN**

**Urinary System**

The urinary bladder, trigone, cystourethral junction, and visible pelvic urethra to a depth of 2.0 cm exhibited normal thickness and tone. Anechoic urine was present in the lumen with no calculi, uroliths or sediment. The ureteral papillae were normal. The ureters were not visible which is normal. No evidence of inflammatory or neoplastic changes was noted.

The area of the aortic trifurcation was free of pathology.

Normal size and margination were present in the kidneys. A normal 1:3 cortex / medulla ratio and normal corticomedullary definition were maintained. The echogenicity of the cortex was similar to or slightly less than normal liver parenchyma while the medulla echogenicity was hypoechoic to the cortex with no evidence of pelvic dilation. The left kidney measured 4.5 cm in length. The right kidney measured 4.5 cm in length.

**Adrenal Glands**

The left adrenal gland was uniform in size and contour with a uniformly hypoechoic parenchyma. The left adrenal gland measured 0.36 cm width. The right adrenal gland was uniform in size and contour with a uniformly hypoechoic parenchyma. The right adrenal gland measured 0.37 cm width.

**Spleen**

The spleen exhibited a finely textured and homogenous parenchyma which was hyperechoic to the liver and renal cortical parenchyma. The capsule was smooth and regular without apparent expansion. The splenic vasculature at the hilus was normal in volume with no evidence of congestion or thrombosis. Acute to chronic inflammatory, neoplastic, or benign parenchyma changes were not noted. The spleen measured 0.7 cm width at the level of the hilus.

**Liver/ Gallbladder**

The liver was subjectively normal in size, structure, and contour. The liver parenchyma was uniform and hypoechoic to the spleen with a mild coarse echotexture. The hepatic and portal vasculature were normal in appearance without signs of congestion. The gallbladder was non-distended in size with thin walls and primarily anechoic luminal content. The cystic and common bile ducts were normal.

**Gastrointestinal**

The stomach presented intact wall layering with a normal wall layer ratio. The lumen of the stomach was empty with no signs of ileus, obstruction, or foreign material. The gastric body wall width measured 0.24 cm.



**PATIENT**

Oliver Danielson

The small intestine presented intact wall layering with 1:3 muscularis/mucosa ratio. The lumen of the small intestine was empty with no signs of ileus, obstruction, or foreign material. The duodenum wall measured 0.17 cm width. The ileocolic wall measured 0.40 cm width.

**SPECIES**

Feline

Normal visible colon wall layers were present with apparent formed feces in lumen.

***Pancreas***

**BREED**

DSH

The parenchyma of the left limb, body, and right limb of the pancreas presented isoechoic to the adjacent omental fat. A normal curvilinear capsule contour of the pancreas was present. The visible pancreatic duct was normal. No signs of active inflammation or neoplastic disease were evident.

**SEX**

***Free Abdomen***

MN

Intermittent, mildly prominent, hypoechoic, colic lymph nodes were present. These lymph nodes were homogenous, mildly hypoechoic and smoothly marginated. A normal width: length ratio was maintained (<0.5). An example of lymph node size was 1.0 cm x 0.38 cm. Regional hyperechoic mesentery was noted around the colic lymph nodes and general ileocolic junction. No omental masses or evidence of peritoneal free fluid were noted.

**AGE**

6

**WEIGHT**

4 kg

**ULTRASONOGRAPHIC FINDINGS**

- Overall sonographically unremarkable abdomen
- Intermittent nonspecific yet subjective benign / reactive colic lymphadenopathy

**INTERPRETED BY**

R. McKenzie Daniel,  
DVM, DABVP  
(Canine and Feline)

**INTERPRETATION OF THE FINDINGS & FURTHER RECOMMENDATIONS**

No evidence of significant abdominal visceral pathology, i.e., neoplastic criteria, as a definitive cause of the hypercalcemia. Given the lack of reported gastrointestinal signs or weight loss in this patient, the nonspecific colic lymphadenopathy is suspected to be benign reactive or incidental and potentially indicative of minor lymphoid hyperplasia, lymphadenitis, or anagenic stimulation.

**IMAGING PERFORMED BY**

Dr. Belan,  
Dr. Barthelemy

Further renal staging to include urine C/S and protein: creatinine ratio on sterile urine sample may be considered. A hypercalcemia panel may be considered for further assessment, if not done.

**HOSPITAL NAME**

Glamorgan Animal  
Clinic

A definitive retained inguinal or intraabdominal testicle was not visualized. Gross assessment for the presence/absence of penile spines is recommended. If penile spines are not present, retained testicle would be considered unlikely. However, if penile spines are present, additional diagnostics or imaging would be indicated.

**REFERRING VET**

Dr. MacAulay

**INVOICE**

15248

**DATE**

10/25/22



**PATIENT**

Oliver Danielson

**SPECIES**

Feline

**BREED**

DSH

**SEX**

MN

**AGE**

6

**WEIGHT**

4 kg

**INTERPRETED BY**

R. McKenzie Daniel,  
DVM, DABVP  
(Canine and Feline)

**IMAGING PERFORMED BY**

Dr. Belan,  
Dr. Barthelemy

**HOSPITAL NAME**

Glamorgan Animal  
Clinic

**REFERRING VET**

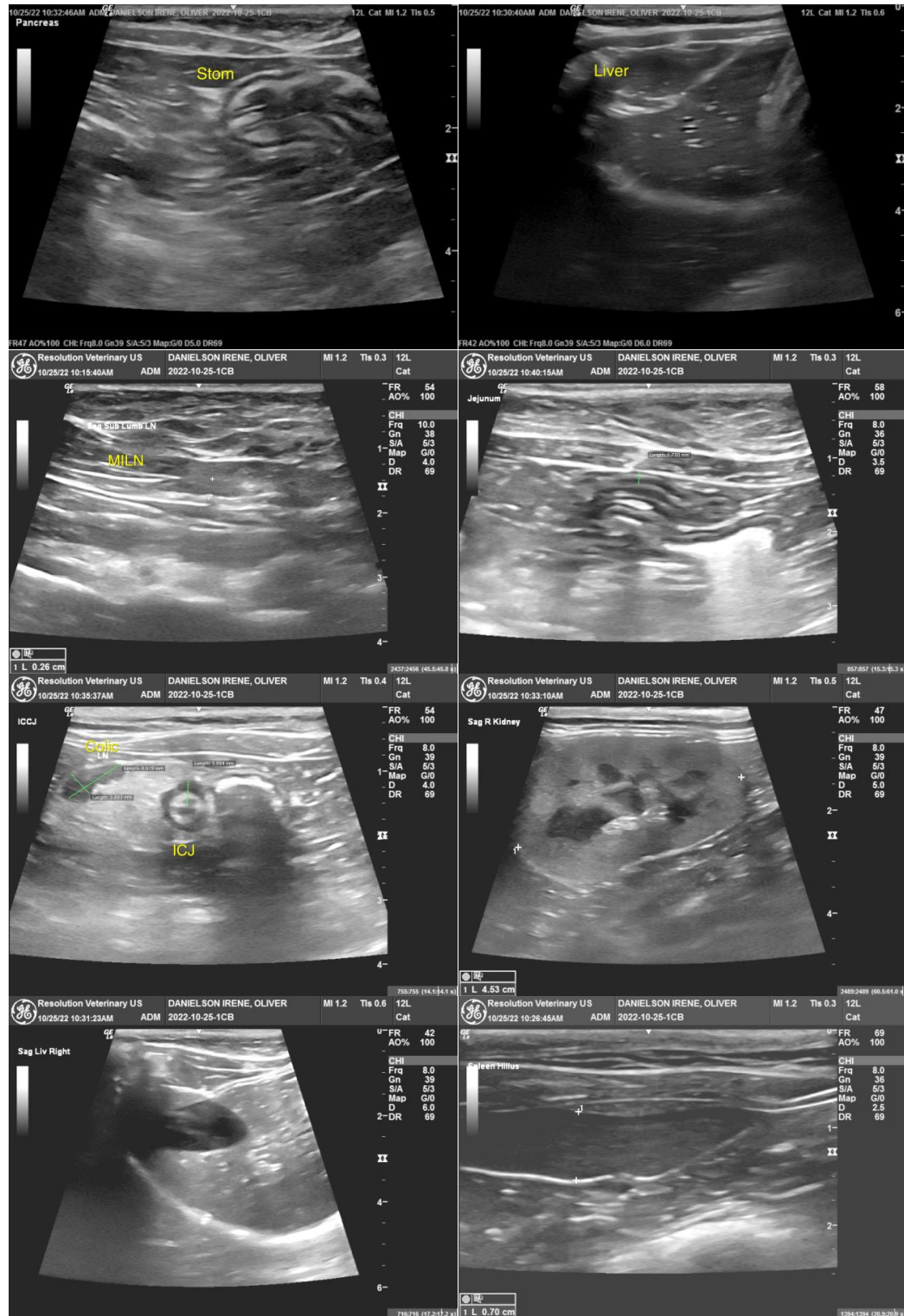
Dr. MacAulay

**INVOICE**

15248

**DATE**

10/25/22





## PATIENT

Oliver Danielson

## SPECIES

Feline

## BREED

DSH

## SEX

MN

## AGE

6

## WEIGHT

4 kg

## INTERPRETED BY

R. McKenzie Daniel,  
DVM, DABVP  
(Canine and Feline)

## IMAGING PERFORMED BY

Dr. Belan,  
Dr. Barthelemy

## HOSPITAL NAME

Glamorgan Animal  
Clinic

## REFERRING VET

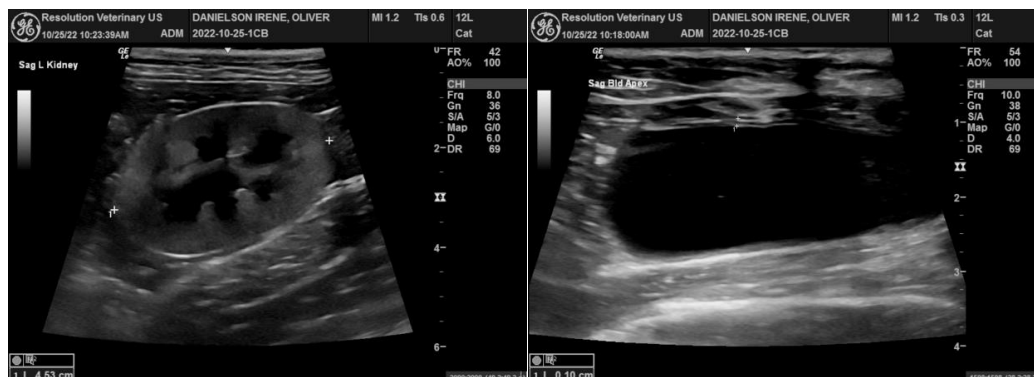
Dr. MacAulay

## INVOICE

15248

## DATE

10/25/22



The information and recommendations provided are based on the images presented by the referring veterinarian/sonographer. No evaluation can be communicated regarding pathology that was not visible in the image/video clips provided.

Thank you for this referral. If the clinical or image interpretation does not parallel your findings or if I can be of any further assistance please contact me.

**R. McKenzie Daniel, DVM, DABVP (Canine / Feline Practice)**  
info@SonoPath.com