



PATIENT

Luna Ferguson

SPECIES

Canine

BREED

Lab Ret

SEX

FI

AGE

1.5 years

WEIGHT

70 lbs.

PRESENTING CLINICAL SIGNS

Chronic urinary tract infections since roughly 6 months of age. Multiple medications have been attempted. Patient has had 2 heat cycles with the last one roughly 1 month ago. Foul odor to urine and multiple attempts to urinate with limited production. Patient constantly licking vulva at home per owner.

Urinalysis- Specific gravity 1.010, PH 8.0, negative protein & glucose, RBC/WBC <1 per high power field, no detected bacteria

ULTRASONOGRAPHIC EXAMINATION OF THE URINARY SYSTEM

The urinary bladder was normal in size and tone. The urinary bladder walls were overtly normal without evidence of inflammatory or neoplastic criteria. Anechoic urine was present with moderate, non-dependent, particulate to dependent hyperechoic sediment to sand. The visible proximal urethra exhibited normal structure and tone to a depth of 3.0 cm. No overt pathology was noted at the level of the ureteral papilla with a definitive ureteral jet visualized.

The uterus was sonographically normal without evidence of luminal fluid accumulation. The left and right ovaries were sonographically normal. The left ovary measured 2.1 cm diameter. The right ovary measured 1.8 cm diameter.

Normal size and margination were present in the kidneys. A normal 1:3 cortex / medulla ratio and normal corticomedullary definition were maintained. The echogenicity of the cortex was similar to or slightly less than normal liver parenchyma while the medulla echogenicity was hypoechoic to the cortex with no evidence of pyelectasia or dysplasia. The left kidney measured 4.9 cm in length. The right kidney measured 5.2 cm in length.

INTERPRETED BY

R. McKenzie Daniel,
DVM, DABVP
(Canine and Feline)

ULTRASONOGRAPHIC FINDINGS

- Moderate urinary bladder non-dependent sediment to dependent sand, sonographically unremarkable visible proximal urethra
- Sonographically normal bilateral kidneys - no evidence of congenital renal disease or pyelonephritis

IMAGING PERFORMED BY

Amanda Lacey-Crook -
SDEP Certified
Sonographer

HOSPITAL NAME

Rivers Edge Pet
Medical Center

INTERPRETATION OF THE FINDINGS & FURTHER RECOMMENDATIONS

REFERRING VET

Dr. Travis Gibson

No overt evidence of congenital lower urinary tract disease i.e., ectopic ureter, urachal remnant, or other. If documented positive infection on pending C/S, antibiotic use, ideally based on C/S results, with potential higher dose/shorter frequency antibiotic regimen with as-needed urinary probiotics to minimize negative effects on urinary bladder flora may prove more effective at eliminating persistent or recurrent infection.

INVOICE

15254

DATE

10/25/22

Assessment of the vulva and vaginal vault for evidence of structural pathology or abnormalities which may predispose to ascending infection could be considered. Cystoscopy may ultimately be indicated. Urinary diet, if evidence of crystalline debris, could be considered.



PATIENT

Luna Ferguson

SPECIES

Canine

BREED

Lab Ret

SEX

FI

AGE

1.5 years

WEIGHT

70 lbs.

INTERPRETED BY

R. McKenzie Daniel,
DVM, DABVP
(Canine and Feline)

IMAGING PERFORMED BY

Amanda Lacey-Crook -
SDEP Certified
Sonographer

HOSPITAL NAME

Rivers Edge Pet Medical Center

REFERRING VET

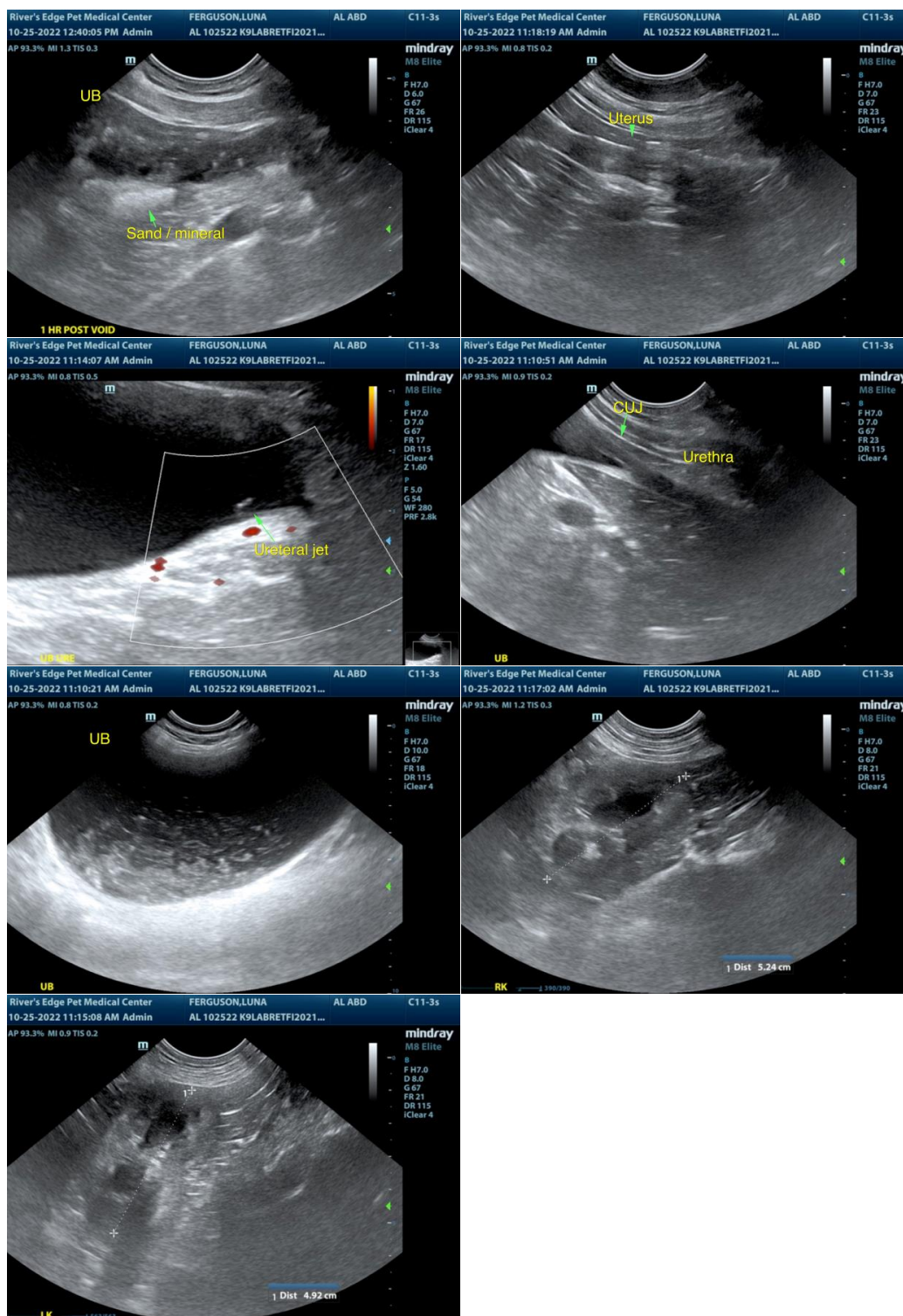
Dr. Travis Gibson

INVOICE

15254

DATE

10/25/22



The information and recommendations provided are based on the images presented by the referring veterinarian/sonographer. No evaluation can be communicated regarding pathology that was not visible in the image/video clips provided.



PATIENT

Luna Ferguson

Thank you for this referral. If the clinical or image interpretation does not parallel your findings or if I can be of any further assistance please contact me.

SPECIES

Canine

R. McKenzie Daniel, DVM, DABVP (Canine / Feline Practice)
info@SonoPath.com

BREED

Lab Ret

SEX

FI

AGE

1.5 years

WEIGHT

70 lbs.

INTERPRETED BY

R. McKenzie Daniel,
DVM, DABVP
(Canine and Feline)

**IMAGING
PERFORMED BY**

Amanda Lacey-Crook -
SDEP Certified
Sonographer

HOSPITAL NAME

Rivers Edge Pet
Medical Center

REFERRING VET

Dr. Travis Gibson

INVOICE

15254

DATE

10/25/22