



**PATIENT**

Gulliver Hayes

**SPECIES**

Feline

**BREED**

Siamese Mix

**SEX**

MN

**AGE**

2015

**WEIGHT**

13.5 lbs.

**PRESENTING CLINICAL SIGNS**

Sporadic vomitus found around the house (multiple cats). Refusing food and lethargic today. Physical unremarkable.

Abnormal PE/Chem/CBC/UA Results: normal labwork

**ULTRASONOGRAPHIC EXAMINATION OF THE ABDOMEN**

**Urinary System**

The urinary bladder, trigone, and cystourethral junction exhibited normal thickness and tone. Anechoic urine was present in the lumen with no uroliths or sediment. The ureteral papillae were normal. The ureters were not visible which is normal. No evidence of inflammatory or neoplastic changes was noted.

The area of the aortic trifurcation was free of pathology.

Normal size and margination were present in the kidneys. A normal 1:3 cortex / medulla ratio and normal corticomedullary definition were maintained. The echogenicity of the cortex was similar to or slightly less than normal liver parenchyma while the medulla echogenicity was hypoechoic to the cortex with no evidence of pelvic dilation. The left kidney measured 4.3 cm in length. The right kidney measured 4.7 cm in length.

**Adrenal Glands**

The left adrenal gland was uniform in size and contour with a uniformly hypoechoic parenchyma. The left adrenal gland measured 0.30 cm width. The area of the right adrenal gland was free of overt pathology.

**Spleen**

The spleen exhibited a finely textured and homogenous parenchyma which was hyperechoic to the liver and renal cortical parenchyma. The capsule was smooth and regular without apparent expansion. The splenic vasculature at the hilus was normal in volume with no evidence of congestion or thrombosis. Acute to chronic inflammatory, neoplastic, or benign parenchyma changes were not noted. The spleen measured 0.95 cm width at the level of the hilus.

**Liver/ Gallbladder**

The liver was subjectively normal in size, structure, and contour. The liver parenchyma was uniform and hypoechoic to the spleen with a mild coarse echotexture. The hepatic and portal vasculature were normal in appearance without signs of congestion. The gallbladder was non-distended in size with minor echogenic luminal debris, likely incidental and suspected to be secondary to fasting given no evidence of cholestasis. The cystic and common bile ducts were normal.

**Gastrointestinal**

The stomach presented intact wall layering with a normal wall layer ratio. The lumen of the stomach was empty with mild luminal gas with no signs of ileus, obstruction, or foreign material.

**INTERPRETED BY**

R. McKenzie Daniel,  
DVM, DABVP  
(Canine and Feline)

**IMAGING PERFORMED BY**

Amanda Lacey-Crook -  
SDEP Certified  
Sonographer

**HOSPITAL NAME**

Rivers Edge Pet  
Medical Center

**REFERRING VET**

Dr. Bridget Hayes

**INVOICE**

15255

**DATE**

10/25/22



## PATIENT

Gulliver Hayes

The small intestine presented intact wall layering with 1:3 muscularis/mucosa ratio. The lumen of the small intestine was empty with no signs of ileus, obstruction, or foreign material. No evidence of pathology was noted at the level of the ileocolic junction.

## SPECIES

Feline

Normal visible colon wall layers were present with apparent formed feces in lumen.

## BREED

Siamese Mix

## Pancreas

The left limb, right limb, and base of the pancreas presented hypoechoic to heterogeneous echogenicity compared to adjacent omental fat. Mild asymmetrical capsule margination was present with mild variable parenchymal swelling and mild peripancreatic reactivity / inflammation. No overt evidence of neoplasia.

## SEX

MN

## Free Abdomen

No evidence of omental masses, overt or significant lymphadenopathy, or evidence of peritoneal free fluid were noted.

## AGE

2015

## ULTRASONOGRAPHIC FINDINGS

## WEIGHT

13.5 lbs.

- Mild to prominent hypoechoic pancreas, evidence of mild peripancreatic reactive mesentery - potential low-grade to mild pancreatitis
- Sonographically unremarkable gastrointestinal tract

## INTERPRETED BY

R. McKenzie Daniel,  
DVM, DABVP  
(Canine and Feline)

## INTERPRETATION OF THE FINDINGS & FURTHER RECOMMENDATIONS

Sonographically, the appearance of the pancreas may suggest low-grade pancreatitis, although not definitive given the lack of cranial abdominal or subxiphoid discomfort on palpation. Correlation with a Spec fPL is suggested.

## IMAGING PERFORMED BY

Amanda Lacey-Crook -  
SDEP Certified  
Sonographer

Dietary intolerance / food allergy, occult parasitism if the patient is indoor/outdoor, low-grade pancreatitis, and structurally insignificant inflammatory gastrointestinal disease are all potentials. Overall, no overt evidence of significant intraabdominal visceral pathology. As-needed GI support is recommended.

## HOSPITAL NAME

Rivers Edge Pet  
Medical Center

## REFERRING VET

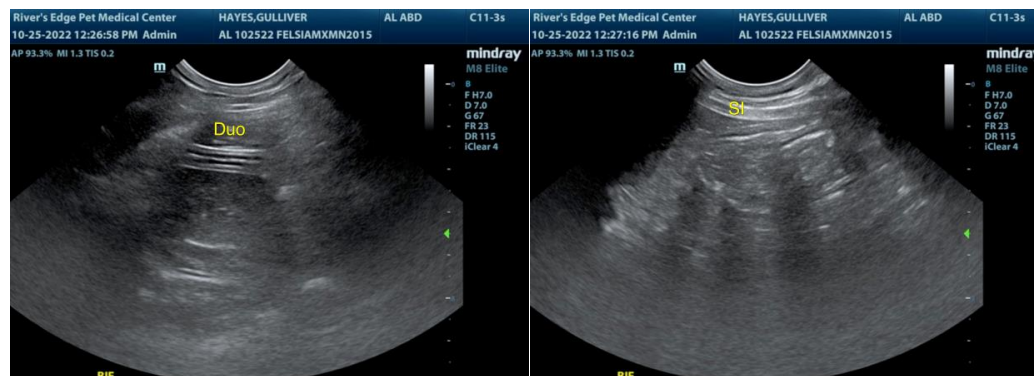
Dr. Bridget Hayes

## INVOICE

15255

## DATE

10/25/22





**PATIENT**

Gulliver Hayes

**SPECIES**

Feline

**BREED**

Siamese Mix

**SEX**

MN

**AGE**

2015

**WEIGHT**

13.5 lbs.

**INTERPRETED BY**

R. McKenzie Daniel,  
DVM, DABVP  
(Canine and Feline)

**IMAGING PERFORMED BY**

Amanda Lacey-Crook -  
SDEP Certified  
Sonographer

**HOSPITAL NAME**

Rivers Edge Pet Medical Center

**REFERRING VET**

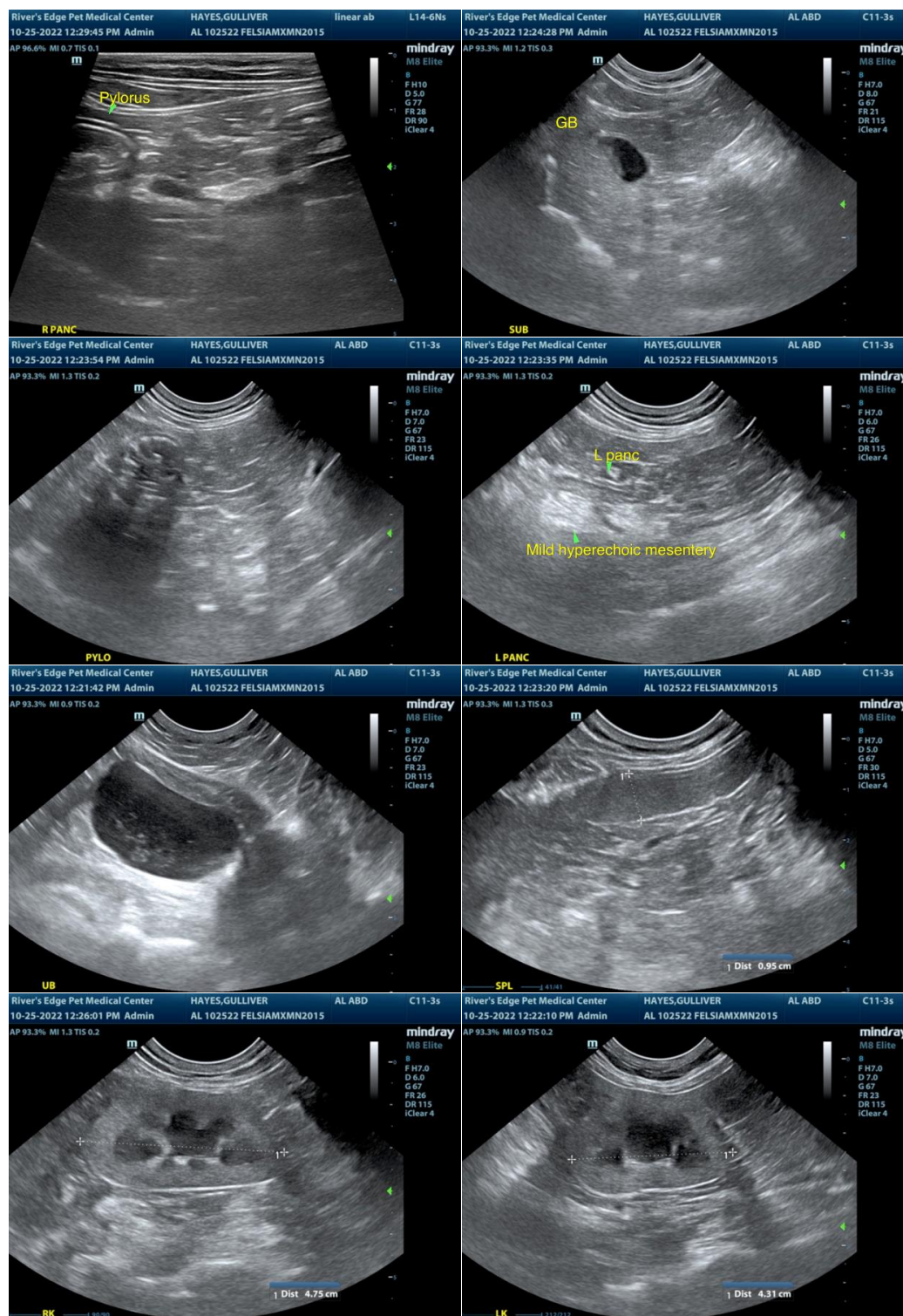
Dr. Bridget Hayes

**INVOICE**

15255

**DATE**

10/25/22



The information and recommendations provided are based on the images presented by the referring veterinarian/sonographer. No evaluation can be communicated regarding pathology that was not visible in the image/video clips provided.



**PATIENT**

Gulliver Hayes

Thank you for this referral. If the clinical or image interpretation does not parallel your findings or if I can be of any further assistance please contact me.

**SPECIES**

Feline

**R. McKenzie Daniel, DVM, DABVP (Canine / Feline Practice)**  
**info@SonoPath.com**

**BREED**

Siamese Mix

**SEX**

MN

**AGE**

2015

**WEIGHT**

13.5 lbs.

**INTERPRETED BY**

R. McKenzie Daniel,  
DVM, DABVP  
(Canine and Feline)

**IMAGING  
PERFORMED BY**

Amanda Lacey-Crook -  
SDEP Certified  
Sonographer

**HOSPITAL NAME**

Rivers Edge Pet  
Medical Center

**REFERRING VET**

Dr. Bridget Hayes

**INVOICE**

15255

**DATE**

10/25/22