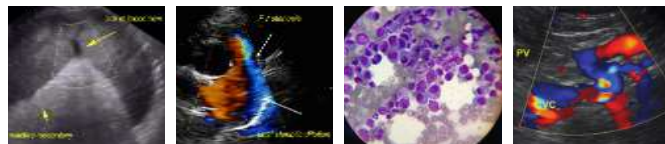




PATIENT	PRESENTING CLINICAL SIGNS
Kaya Niedelman	Pale, SOB, lethargy after boarding Anemia, tachypnea, new HM (grade 3/6) Vaccinated x 2 weeks ago Abnormal PE/Chem/CBC/UA Results: WBC: 27.5 neut: 23 mono: 1.1 bands: 1100 hct 14%
SPECIES	ULTRASONOGRAPHIC EXAMINATION OF THE ABDOMEN
Canine	<i>Urinary System</i>
BREED	The urinary bladder, trigone, cystourethral junction, and visible pelvic urethra to a depth of 3.0 cm exhibited normal thickness and tone. Anechoic urine was present in the lumen with no uroliths or sediment. The ureteral papillae were normal. The ureters were not visible which is normal. No evidence of inflammatory or neoplastic changes were noted.
Siberian Husky	No evidence of pathology in the area of the aortic trifurcation.
SEX	Normal size and margination was present in the kidneys. A normal 1:3 cortex / medulla ratio and normal corticomedullary definition were maintained. The echogenicity of the cortex was similar to or slightly less than normal liver parenchyma while the medulla echogenicity was hypoechoic to the cortex with no evidence of pelvic dilation. The left kidney measured 6.8 cm in length. The right kidney measured 6.9 cm in length.
FS	
AGE	<i>Adrenal Glands</i>
9 Years, 9 Months	The left adrenal gland was uniform in size and contour with a uniformly hypoechoic parenchyma. The left adrenal gland measured 0.42 cm width at the caudal pole and 0.41 cm width at the cranial pole. The right adrenal gland was indistinctly visualized without overt pathology subjectively measuring 0.49 cm width at the caudal pole.
WEIGHT	<i>Spleen</i>
27.9kg	The spleen was normal in size and contour with a finely textured and homogenous parenchyma exhibiting overall normal parenchyma echogenicity. Intermittent primarily non-expansive hypoechoic parenchymal nodules were noted in the spleen with a solitary nodule noted in the splenic tail exhibiting subtle distortion of the adjacent splenic parenchyma without evidence of parenchymal escape. The splenic tail nodules measured 1.1 cm diameter. Splenic mid parenchymal nodules measured 0.7-0.8 cm diameter. The capsule was smooth and regular without apparent expansion. The splenic vasculature at the hilus was normal in volume with no evidence of congestion or thrombosis.
INTERPRETED BY	<i>Liver / Gallbladder</i>
R. McKenzie Daniel, DVM, DABVP (Canine and Feline)	The liver was subjectively normal in size, structure, and contour. The liver parenchyma was mildly nonuniform and hypoechoic to the spleen with a moderate coarse echotexture and subjective mild to benign parenchymal remodeling. The hepatic and portal vasculature were normal in appearance without signs of congestion. Intermittent uniformly echogenic mid parenchymal nodules along with a solitary subtly expansive mildly hypoechoic nodule noted in the ventral aspect of the caudate liver lobe. The caudate liver nodule measured 1.1 cm diameter. An example of a mid-parenchymal echogenic nodule in the liver measured 0.6 cm diameter.
IMAGING PERFORMED BY	
Focused Ultrasound Resources	
HOSPITAL NAME	
Focused Ultrasound Resources	
REFERRING VET	
Dr. Meola DVM	
INVOICE	The gallbladder was non distended in size with mild echogenic, nonmineralized gallbladder debris. The cystic duct and common bile ducts were normal without evidence of dilation.
47935	<i>Gastrointestinal</i>
DATE	The stomach presented intact wall layering with a normal wall layer ratio. Minor retained non-shadowing gastric ingesta/chyme was noted in the stomach.
10-23-21	



PATIENT	The small intestine presented intact wall layering with 1:3 muscularis/mucosa ratio. The lumen of the small intestine was empty with no signs of ileus, obstruction or foreign material.
Kaya Niedelman	Normal visible colon wall layers were present with apparent formed feces in lumen.
SPECIES	<i>Pancreas</i>
Canine	The parenchyma of the left limb, body and right limb of the pancreas presented isoechoic to the adjacent omental fat. A normal curvilinear capsule contour of the pancreas was present. The visible pancreatic duct was normal. No signs of active inflammation or neoplastic disease was evident.
BREED	<i>Free Abdomen</i>
Siberian Husky	No omental masses, lymphadenopathy, or peritoneal effusion was present.
SEX	ULTRASONOGRAPHIC FINDINGS
FS	<ul style="list-style-type: none"> Nonspecific intermittent hypoechoic primarily non-expansive splenic nodules - focal areas of lymphoid hyperplasia, hematopoiesis, splenitis, acute infarction, or emerging neoplastic nodules considered less likely differential diagnoses.
AGE	<ul style="list-style-type: none"> Mild hepatic parenchymal remodeling with intermittent echogenic mid parenchymal to focal subtly expansive hypoechoic caudate lobe nodule - intermittent areas of nodular to regenerative hyperplasia, small lipogranulomas, or other benign nodular process with emerging hepatic neoplastic nodules considered less likely differential diagnoses.
9 Years, 9 Months	<ul style="list-style-type: none"> Mild gallbladder debris (nonmucocele).
WEIGHT	INTERPRETATION OF THE FINDINGS & FURTHER RECOMMENDATIONS
27.9kg	Assuming normal clotting status, splenic nodule and if accessible, caudate hepatic nodule FNA for screening cytology and further clarification could be considered. Sonographic monitoring of the hepatic/splenic nodules would a more conservative approach. Overall, the hepatosplenic nodules were not overly consistent with neoplastic criteria as a potential cause of the patient's clinical signs and anemia.
INTERPRETED BY	Alternative causes of anemia i.e., infectious or immune mediated disease, may be considered. Assessment for autoagglutination as well as infectious disease serology may be considered. Three view chest radiographs, if not done, recommended to ruled out occult thoracic pathology and assess cardiopulmonary status.
R. McKenzie Daniel, DVM, DABVP (Canine and Feline)	Empirically, some or all of the following protocol may be considered based on the clinical impression of the patient:
IMAGING PERFORMED BY	IMHA/Infectious Anemia/Thrombocytopenia/Evans Syndrome
Focused Ultrasound Resources	<i>(Note: ensure no underlying neoplasia as IMHA/Evans syndrome can occur as paraneoplastic manifestation especially in lymphoma/round cell neoplasia)</i>
HOSPITAL NAME	Anemia +/- thrombocytopenia with spherocytes/autoagglutination in dogs and hyperbilirubinemia, bilirubinuria. <i>(NOTE: cats do not get spherocytes in IMHA)</i>
Focused Ultrasound Resources	Consider Onion/Garlic derivative ingestion if Heinz bodies present.
REFERRING VET	INVOICE
Dr. Meola DVM	47935
	Prednisone (K9) Prednisolone (Feline): 2 mg/kg Sid/Bid initially x 3 weeks then attempt taper
	Aspirin 0.5 mg/kg Sid owing to hypercoagulable state
	Sucralfate 0.5-1 g po tid dogs, 0.5 g bid cats in slurry
	Doxycycline if infectious suspected clinically or based on CBC path review:
	Dogs, Cats: 10 mg/kg p.o. q24h with food or water bolus in cats
INVOICE	DATE
47935	10-23-21



PATIENT

Kaya Niedelman

SPECIES

Canine

BREED

Siberian Husky

SEX

FS

AGE

9 Years, 9 Months

WEIGHT

27.9kg

INTERPRETED BY

R. McKenzie Daniel,
DVM, DABVP
(Canine and Feline)

IMAGING PERFORMED BY

Focused Ultrasound
Resources

HOSPITAL NAME

Focused Ultrasound
Resources

REFERRING VET

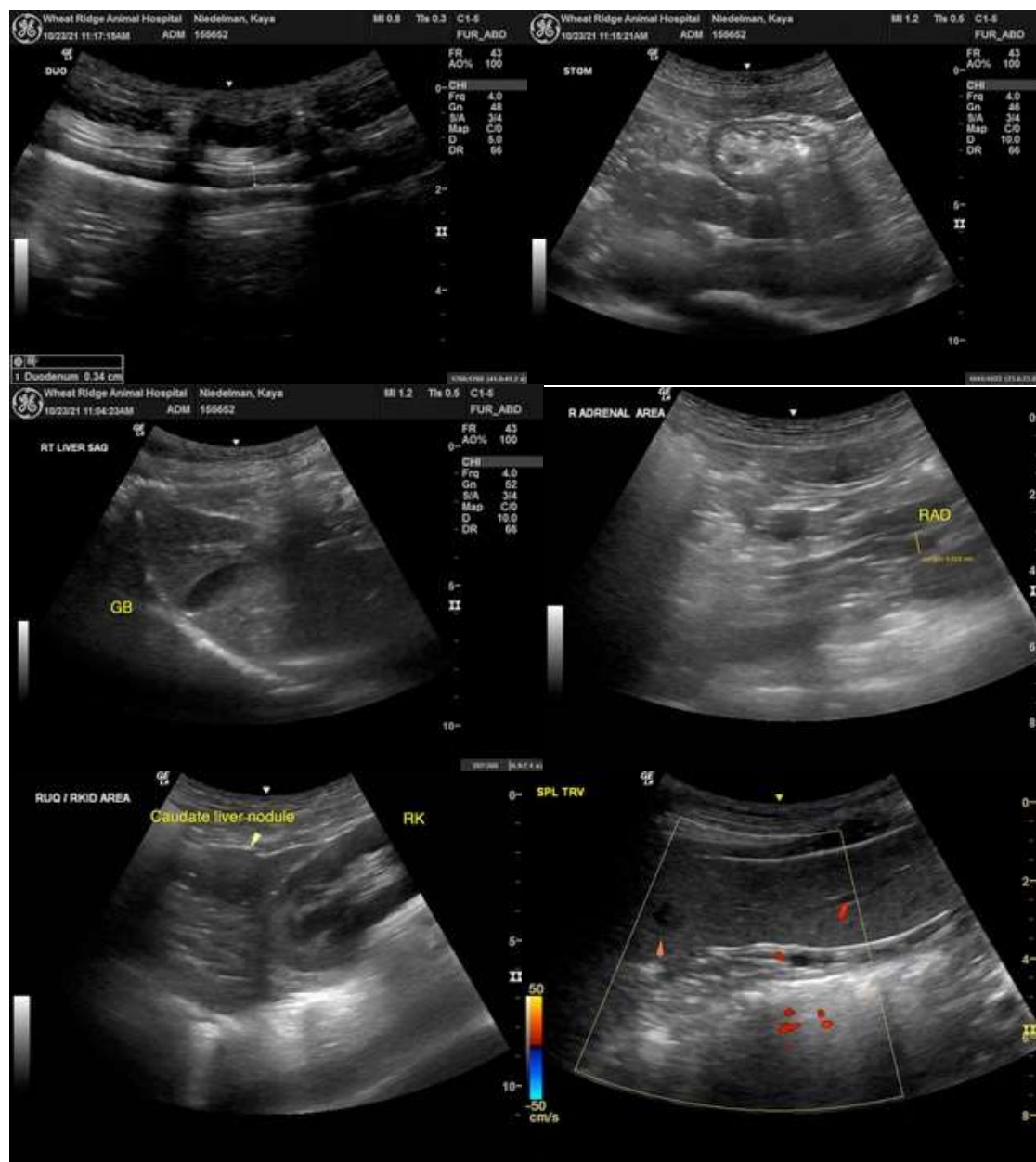
Dr. Meola DVM

INVOICE

47935

DATE

10-23-21





PATIENT

Kaya Niedelman

SPECIES

Canine

BREED

Siberian Husky

SEX

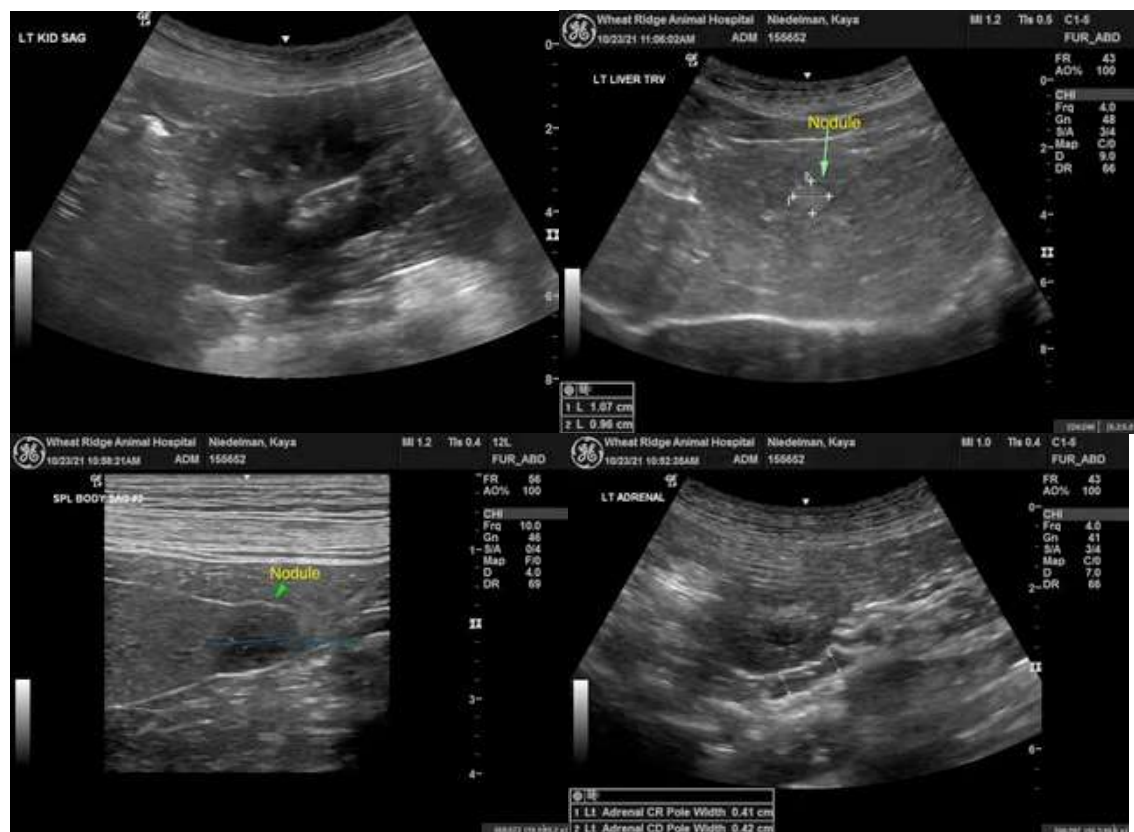
FS

AGE

9 Years, 9 Months

WEIGHT

27.9kg



INTERPRETED BY

R. McKenzie Daniel,
DVM, DABVP
(Canine and Feline)

IMAGING PERFORMED BY

Focused Ultrasound
Resources

HOSPITAL NAME

Focused Ultrasound
Resources

REFERRING VET

Dr. Meola DVM

The information and recommendations provided are based on the images presented by the referring veterinarian. No evaluation can be communicated regarding pathology that was not visible in the image/video clips provided.

Thank you for this referral. If the clinical or image interpretation does not parallel your findings or if I can be of any further assistance please contact me.

R. McKenzie Daniel, DVM, DABVP (Canine / Feline Practice)
info@SonoPath.com

INVOICE

47935

DATE

10-23-21