



PATIENT PRESENTING CLINICAL SIGNS

Shadow Garcia Heart murmur grade 5/6. No reported current meds.

SPECIES ULTRASONOGRAPHIC EXAMINATION OF THE HEART

Canine

BREED

Miniature Poodle

SEX

Intact Male

AGE

11 Years

WEIGHT

6.8 Pounds

CANINE CARDIAC PARAMETERS	MR VMAX (m/s)	TR VMAX (m/s)	LA/AO (Boon method)	LA/AO (Heart Base; Swe)	FS (%)	EF (%)	EPSS (cm)
NORMAL PARAMETER	4.5-5.5	<2.7	1.3	<1.6	28-40	40-100	<0.6
PATIENT	5.5	2.2	NM	1.4	52.4	87.3	0.2
CANINE CARDIAC PARAMETERS	HR (BPM)	AV VMAX (m/s)	PV MAX (m/s)	BODY WEIGHT (kg)	LA 2D short axis Base view (cm)	LVIDd Avg; 2D and m-mode short axis (cm)	LVIDs Avg; 2D and m-mode short axis (cm)
NORMAL PARAMETER	50-100	0.7-1.7	0.7-1.6				
PATIENT	110	1.0	0.85		2.38	2.0	

Cardiac Presentation

The echocardiogram in this patient demonstrated normal **left atrial** size based on 3 different LA measurement methods. Chamber volumes and echogenicity were normal. The cranial and caudal **mitral** valve leaflets presented vegetative thickening consistent with endocardiosis. Doppler indicated measurable eccentric insufficiency. The **left ventricle** presented thicknesses with linear contour and was not dilated nor restricted. The **myocardium** presented normal echogenicity without subjective evidence of significant fibrotic or ischemic disease. **Contractility** of the ventricular walls was adequate and in normal range for this patient evidenced by the fractional shortening measurement and subjective evaluation of the different regions of the myocardium. The **left ventricular outflow** tract demonstrated normal laminar flow and subjective structural integrity. The **right atrium** and auricle revealed normal size, structure and content. No evidence of masses was noted or chamber overload. **Tricuspid** valvular assessment demonstrated adequate linear morphology. Tricuspid valve insufficiency noted on color doppler assessment. The **right ventricle** was of normal size (1/3 diameter of LV), chordae structure, myocardial echogenicity and thickness. **Pulmonic** tract assessment revealed normal valve structure, laminar flow, and diameter (approx. 1:1 pa/ao ratio). No visible **pericardial** or free pleura fluid was noted. No echographically detectable evidence of infiltrative disease was visible. The cranial **mediastinum** and **pericardial regions** were free of masses in the visible window.

INTERPRETED BY

R. McKenzie Daniel, DVM, DABVP (Canine and Feline)

IMAGING PERFORMED BY

Kelly Vazquez

HOSPITAL NAME

Animal Paradise Hospital

REFERRING VET

Dr. Hellworth

INVOICE ULTRASONOGRAPHIC FINDINGS

26598

- Chronic mitral valve disease (ACVIM B1)
- Tricuspid valve insufficiency - estimated pulmonary pressure gradient not consistent with clinical pulmonary hypertension.

DATE

10/21/21



PATIENT

Shadow Garcia

SPECIES

Canine

BREED

Miniature Poodle

SEX

Intact Male

AGE

11 Years

WEIGHT

6.8 Pounds

INTERPRETED BY

R. McKenzie Daniel,
DVM, DABVP
(Canine and Feline)

IMAGING PERFORMED BY

Kelly Vazquez

HOSPITAL NAME

Animal Paradise
Hospital

REFERRING VET

Dr. Hellworth

INVOICE

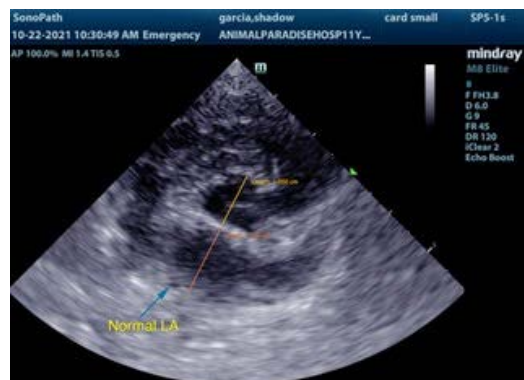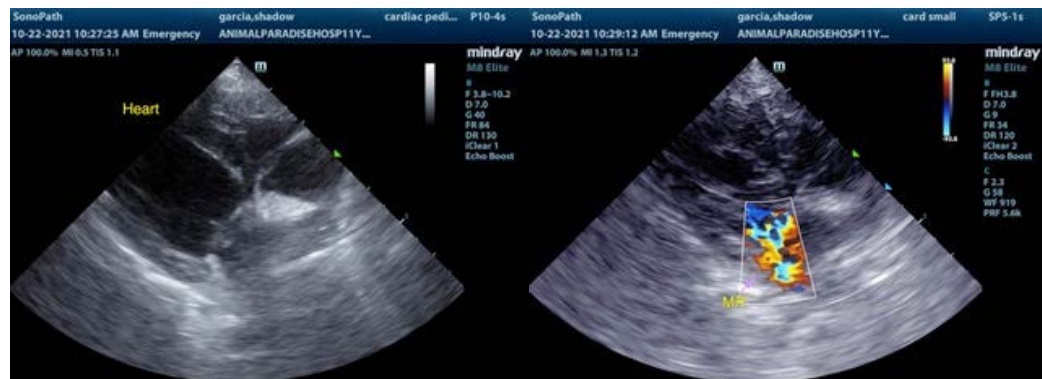
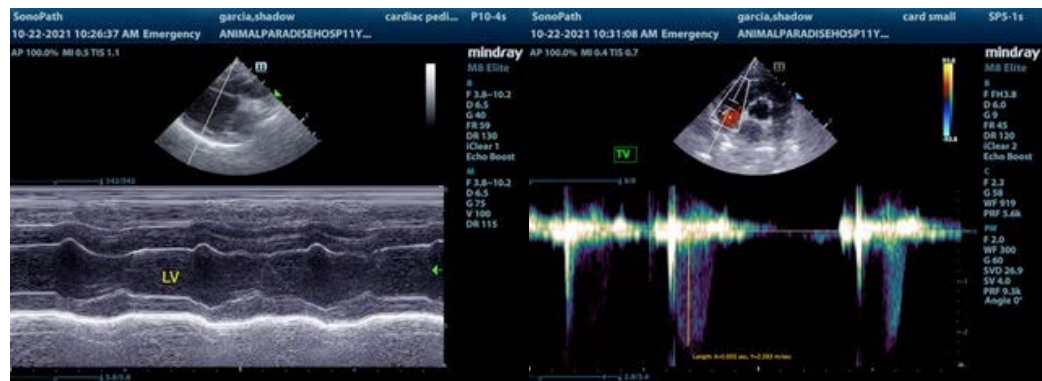
26598

DATE

10/21/21

INTERPRETATION OF THE FINDINGS & FURTHER RECOMMENDATIONS

The cause of the murmur is chronic degenerative valvular changes with secondary eccentric mitral valve insufficiency. The lack of left atrial enlargement implies that the risk of complication secondary to mitral valve insufficiency is relatively low at this time, although prognosis is highly variable. Without current clinical signs, specific medical therapy is not required. Conservative monitoring at this stage would be appropriate recheck echocardiogram in 6 months, sooner if clinical signs suggestive of heart disease develop.





PATIENT

Shadow Garcia

The information and recommendations provided are based on the images presented by the referring veterinarian. No evaluation can be communicated regarding pathology that was not visible in the image/video clips provided.

SPECIES

Canine

Thank you for this referral. If the clinical or image interpretation does not parallel your findings or if I can be of any further assistance please contact me.

BREED

Miniature Poodle

R. McKenzie Daniel, DVM, DABVP (Canine / Feline Practice)
info@SonoPath.com

SEX

Intact Male

AGE

11 Years

WEIGHT

6.8 Pounds

INTERPRETED BY

R. McKenzie Daniel,
DVM, DABVP
(Canine and Feline)

**IMAGING
PERFORMED BY**

Kelly Vazquez

HOSPITAL NAME

Animal Paradise
Hospital

REFERRING VET

Dr. Hellworth

INVOICE

26598

DATE

10/21/21