

PATIENT PRESENTING CLINICAL SIGNS

PATIENT Jake Atwood
SPECIES Canine
BREED Shepard Mix
SEX MN
AGE 10 Years
WEIGHT Unknown

P has hx of intrathoracic mass and several dermal masses (and allergic skin disease). Recent weight loss of ~20lbs over last seven months, abdominal distension. Current Medications prednisolone and cephalexin for allergic skin disease/pyoderma
Abnormal PE/Chem/CBC/UA Results: mature neutrophilia, lymphocytosis, monocytosis

ULTRASONOGRAPHIC EXAMINATION OF THE ABDOMEN

Urinary System

The urinary bladder, trigone, cystourethral junction, and visible pelvic urethra to a depth of 3.0 cm exhibited normal thickness and tone. Anechoic urine was present in the lumen with no uroliths or sediment. The ureteral papillae were normal. The ureters were not visible which is normal. No evidence of inflammatory or neoplastic changes were noted.

The residual prostate was symmetrically normal in size with uniform parenchyma and slight coarse echotexture measuring 1.4 cm in diameter.

No evidence of pathology in the area of the aortic trifurcation.

Normal size and margination was present in the kidneys. A normal 1:3 cortex / medulla ratio was maintained. The medulla and cortices were uniform in texture with some increased echogenicity and mild loss of corticomedullary symmetry and definition expected for the age of the patient. No evidence of pelvic dilation was present. The left kidney measured 7.4 cm in length. The right kidney measured 8.0 cm in length.

Adrenal Glands

The left adrenal gland was uniform in size and contour with a uniformly hypoechoic parenchyma. The left adrenal gland measured 2.6 cm length x 0.49 cm width at the caudal pole. The right adrenal gland was uniform in size and contour with a uniformly hypoechoic parenchyma. The right adrenal gland measured 2.7 cm length x 1.0 cm width at the caudal pole.

Spleen

The spleen exhibited a finely textured and homogenous parenchyma which was hyperechoic to the liver and renal cortical parenchyma. The capsule was smooth and regular without apparent expansion. The splenic vasculature at the hilus was normal in volume with no evidence of congestion or thrombosis. Acute to chronic inflammatory, neoplastic, or benign parenchyma changes were not noted.

Liver

The liver presented markedly enlarged in size with symmetrical yet swollen contour. The parenchyma exhibited conserved uniform parenchyma with normal echogenicity isoechoic to the spleen and falciform fat. The hepatic vasculature was mildly dilated in appearance, most notable at the level of the hepatic vein / caudal vena cava junction, without evidence of thrombosis.

The gallbladder was non distended in size with nondependent yet nonorganized echogenic subjectively mobile gallbladder debris. The cystic duct and common bile ducts were normal without evidence of dilation.

Gastrointestinal

INTERPRETED BY

R. McKenzie Daniel,
DVM, DABVP
(Canine and Feline)

IMAGING PERFORMED BY

Jenna Walsh, CVT

HOSPITAL NAME

South Willamette
Veterinary Clinic

REFERRING VET

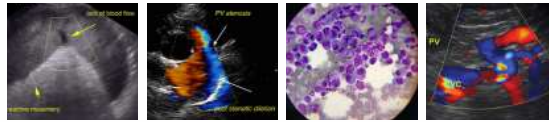
Dr. Willaman

INVOICE

47914

DATE

10-22-21



PATIENT

Jake Atwood

The stomach presented intact wall layering with a normal wall layer ratio. The lumen of the stomach was empty with no signs of ileus, obstruction or foreign material.

SPECIES

Canine

The small intestine presented intact wall layering with 1:3 muscularis/mucosa ratio. The lumen of the small intestine was empty with no signs of ileus, obstruction or foreign material.

BREED

Shepard Mix

Normal visible colon wall layers were present with apparent formed feces in lumen.

SEX

MN

Pancreas

The parenchyma of the left limb, body and right limb of the pancreas presented isoechoic to the adjacent omental fat. A normal curvilinear capsule contour of the pancreas was present. The visible pancreatic duct was normal. No signs of active inflammation or neoplastic disease was evident.

AGE

10 Years

Free Abdomen

No overt lymphadenopathy was present.

WEIGHT

Unknown

A small pocket of scant ascites was noted around the ventral liver.

Brief sonographic assessment of the thorax revealed nonhomogeneous thoracic mass adjacent to the heart along with concurrent pleural effusion. No overt evidence of pericardial effusion or obvious left or right chamber enlargement.

ULTRASONOGRAPHIC FINDINGS

INTERPRETED BY

R. McKenzie Daniel,
DVM, DABVP
(Canine and Feline)

Primary

- Hepatomegaly with subjective mild hepatic vasculature dilation.
- Moderate gallbladder debris (nonmucocele).
- Thoracic mass.
- Pleural effusion with concurrent scant ascites.

IMAGING PERFORMED BY

Jenna Walsh, CVT

INTERPRETATION OF THE FINDINGS & FURTHER RECOMMENDATIONS

The abdominal distension on this patient is suspected to be primarily owing to hepatomegaly. Congestive hepatopathy is suspected although potential primary hepatic parenchymal disease i.e., vacuolar hepatic changes, hepatic parenchymal or hepatobiliary inflammation, or neoplasia cannot be definitively excluded. The hepatic congestion may be owing to the thoracic mass or nonobvious right heart disease, elevated pulmonary pressures, or other. Aside from the hepatomegaly, no overt evidence of significant visceral pathology as an obvious cause of the patient's weight loss. This may indicate primary cause of weight loss within the thoracic cavity related to the thoracic mass.

HOSPITAL NAME

South Willamette
Veterinary Clinic

Assuming normal clotting status, screening hepatic FNA to ensure only benign changes are present and rule out potential for hepatic neoplasia may be considered.

REFERRING VET

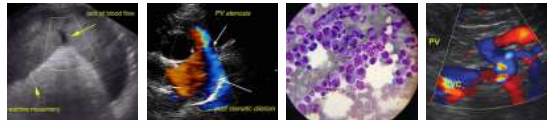
Dr. Willaman

INVOICE

47914

DATE

10-22-21



PATIENT

Jake Atwood

SPECIES

Canine

BREED

Shepard Mix

SEX

MN

AGE

10 Years

WEIGHT

Unknown

INTERPRETED BY

R. McKenzie Daniel,
DVM, DABVP
(Canine and Feline)

IMAGING PERFORMED BY

Jenna Walsh, CVT

HOSPITAL NAME

South Willamette
Veterinary Clinic

REFERRING VET

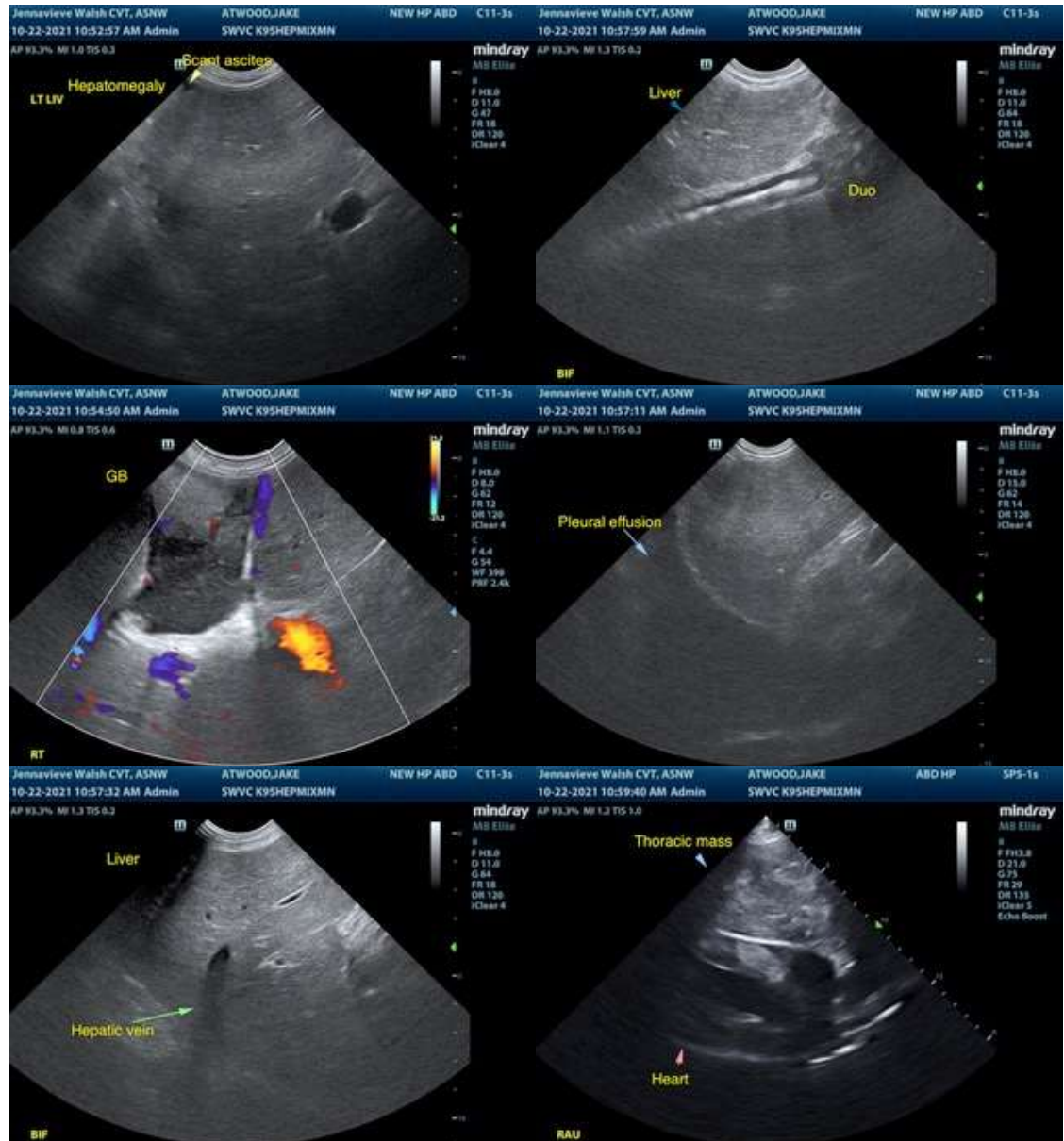
Dr. Willaman

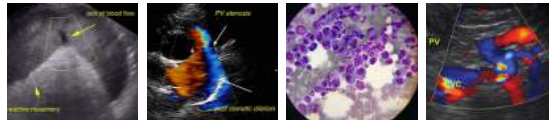
INVOICE

47914

DATE

10-22-21





PATIENT

Jake Atwood

SPECIES

Canine

BREED

Shepard Mix

SEX

MN

AGE

10 Years

WEIGHT

Unknown

INTERPRETED BY

R. McKenzie Daniel,
DVM, DABVP
(Canine and Feline)

IMAGING PERFORMED BY

Jenna Walsh, CVT

HOSPITAL NAME

South Willamette
Veterinary Clinic

REFERRING VET

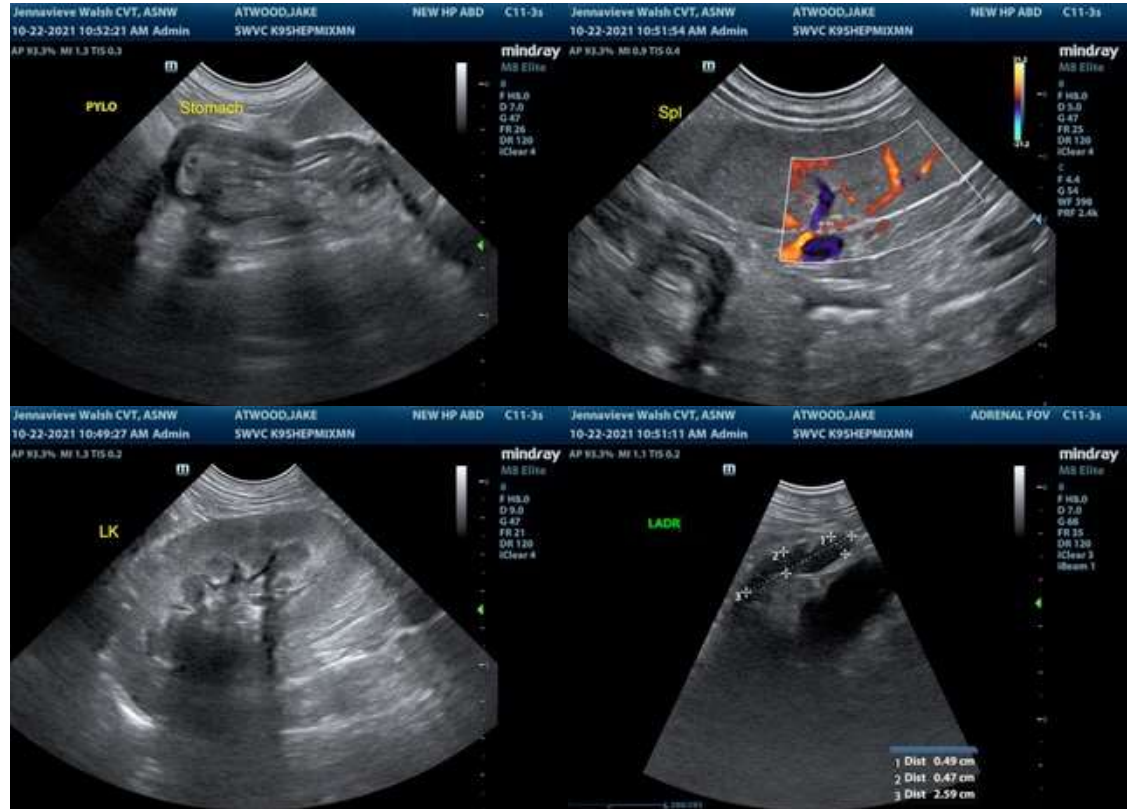
Dr. Willaman

INVOICE

47914

DATE

10-22-21



The information and recommendations provided are based on the images presented by the referring veterinarian. No evaluation can be communicated regarding pathology that was not visible in the image/video clips provided.

Thank you for this referral. If the clinical or image interpretation does not parallel your findings or if I can be of any further assistance please contact me.

R. McKenzie Daniel, DVM, DABVP (Canine / Feline Practice)
info@SonoPath.com