



PATIENT

Jack Polley

PRESENTING CLINICAL SIGNS

reoccurring hematuria, Left kidney enlargement seen on radiographs. UA culture no growth.

SPECIES

Canine

ULTRASONOGRAPHIC EXAMINATION OF THE ABDOMEN

Urinary System

The urinary bladder, trigone, cystourethral junction, and visible pelvic urethra was sonographically unremarkable to a depth of 2.0 cm. Anechoic urine was present in the lumen with no uroliths or sediment. The ureteral papillae were normal. The ureters were not visible which is normal. No evidence of inflammatory or neoplastic changes were noted.

BREED

Boxer

The residual prostate was symmetrically normal in size with uniform parenchyma and slight coarse echotexture measuring 1.4 cm in width.

SEX

No evidence of pathology in the area of the aortic trifurcation.

MN

The left kidney was mildly enlarged in size. Mild to moderate loss of corticomedullary border demarcation with pinpoint to focal areas of medullary mineral noted. No evidence of pyelectasia or evidence of left retroperitoneal inflammation or effusion. A small cortical cyst was noted. The left kidney measures 7.8 cm length.

AGE

11 Years

The right kidney was subnormal in size and indistinctly visualized exhibiting asymmetrical contour, marked loss of corticomedullary border demarcation, and reduced medullary volume. No evidence of right kidney pyelectasia or right retroperitoneal inflammation or effusion. The right kidney measured 4.2 cm length.

WEIGHT

67.6

Adrenal Glands

The bilateral adrenal glands were normal in size. Mild parenchyma heterogeneity and mild capsule asymmetry was present without suspicion for overt neoplasia. The left adrenal gland measured 0.73 cm width at the caudal pole and 0.57 cm width at the cranial pole. The right adrenal gland measured 0.58 cm width at the caudal pole and 0.75 cm width at the cranial pole.

INTERPRETED BY

R. McKenzie Daniel,
DVM, DABVP
(Canine and Feline)

Spleen

The spleen exhibited primarily finely textured parenchyma which was hyperechoic to the liver and renal cortical parenchyma. Mild generalized parenchyma heterogeneity was present without evidence of nodular changes. The capsule was smooth and regular without apparent expansion. The splenic vasculature at the hilus was normal in volume with no evidence of congestion or thrombosis. The parenchymal heterogeneity is likely consistent with benign changes such as extramedullary hematopoiesis or age related remodeling with minor potential for inflammatory or neoplastic disease.

IMAGING PERFORMED BY

Kim Liedberg

HOSPITAL NAME

SVS Imaging WI

Liver / Gallbladder

The liver was subjectively normal in size, structure, and contour. The liver parenchyma was uniform and hypoechoic to the spleen with a mild coarse echotexture. The hepatic and portal vasculature were normal in appearance without signs of congestion. The gallbladder was non-distended in size with thin walls and primarily anechoic luminal content. The cystic and common bile ducts were normal.

REFERRING VET

Dr Kreier, Badger
Veterinary Hospital
Janesville

INVOICE

47912

Gastrointestinal

The stomach presented intact wall layering with a normal wall layer ratio. The lumen of the stomach was empty with no signs of ileus, obstruction or foreign material.

DATE

10-22-21



PATIENT

Jack Polley

The small intestine presented intact wall layering with 1:3 muscularis/mucosa ratio. The lumen of the small intestine was empty with no signs of ileus, obstruction or foreign material.

Normal visible colon wall layers were present with apparent formed feces in lumen.

SPECIES

Canine

Pancreas

The parenchyma of the left limb, body and right limb of the pancreas presented isoechoic to the adjacent omental fat. A normal curvilinear capsule contour of the pancreas was present. The visible pancreatic duct was normal. No signs of active inflammation or neoplastic disease was evident.

BREED

Boxer

Free Abdomen

Focal subjectively reactive to benign mesenteric lymph node with potential for focal area of nodular fat necrosis noted. This is considered incidental.

SEX

MN

No overt peritoneal effusion was present.

ULTRASONOGRAPHIC FINDINGS

AGE

11 Years

Primary

- Sonographically unremarkable urinary bladder, residual prostate, and visible proximal urethra.
- Left kidney mild enlargement with moderate chronic renal changes and pinpoint to focal medullary mineral.
- Right kidney subnormal size with marked chronic degenerative changes.

WEIGHT

67.6

INTERPRETATION OF THE FINDINGS & FURTHER RECOMMENDATIONS

INTERPRETED BY

R. McKenzie Daniel,
DVM, DABVP
(Canine and Feline)

The right kidney is consistent with advanced chronic degenerative changes potentially owing to progressive CRD, nonspecific chronic nephritis, or dysplasia.

The left kidney is suggestive of suspected compensatory hypertrophy given the suspected lack of right kidney functionality yet exhibiting chronic renal changes expected for age and without evidence of neoplastic criteria.

IMAGING PERFORMED BY

Kim Liedberg

Given the lack of lower urinary tract pathology, i.e., neoplasia, calculi, etc., the recurring hematuria is most likely renal in origin. Given lack of evidence for underlying infection, conservative therapy for chronic renal disease and assessment of systemic blood pressure recommended.

HOSPITAL NAME

SVS Imaging WI

REFERRING VET

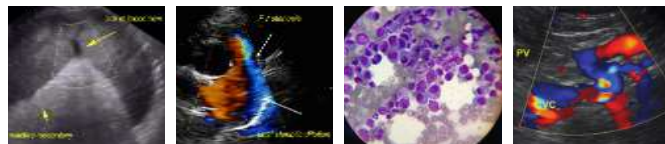
Dr Kreier, Badger
Veterinary Hospital
Janesville

INVOICE

47912

DATE

10-22-21



PATIENT

Jack Polley

SPECIES

Canine

BREED

Boxer

SEX

MN

AGE

11 Years

WEIGHT

67.6

INTERPRETED BY

R. McKenzie Daniel,
DVM, DABVP
(Canine and Feline)

IMAGING PERFORMED BY

Kim Liedberg

HOSPITAL NAME

SVS Imaging WI

REFERRING VET

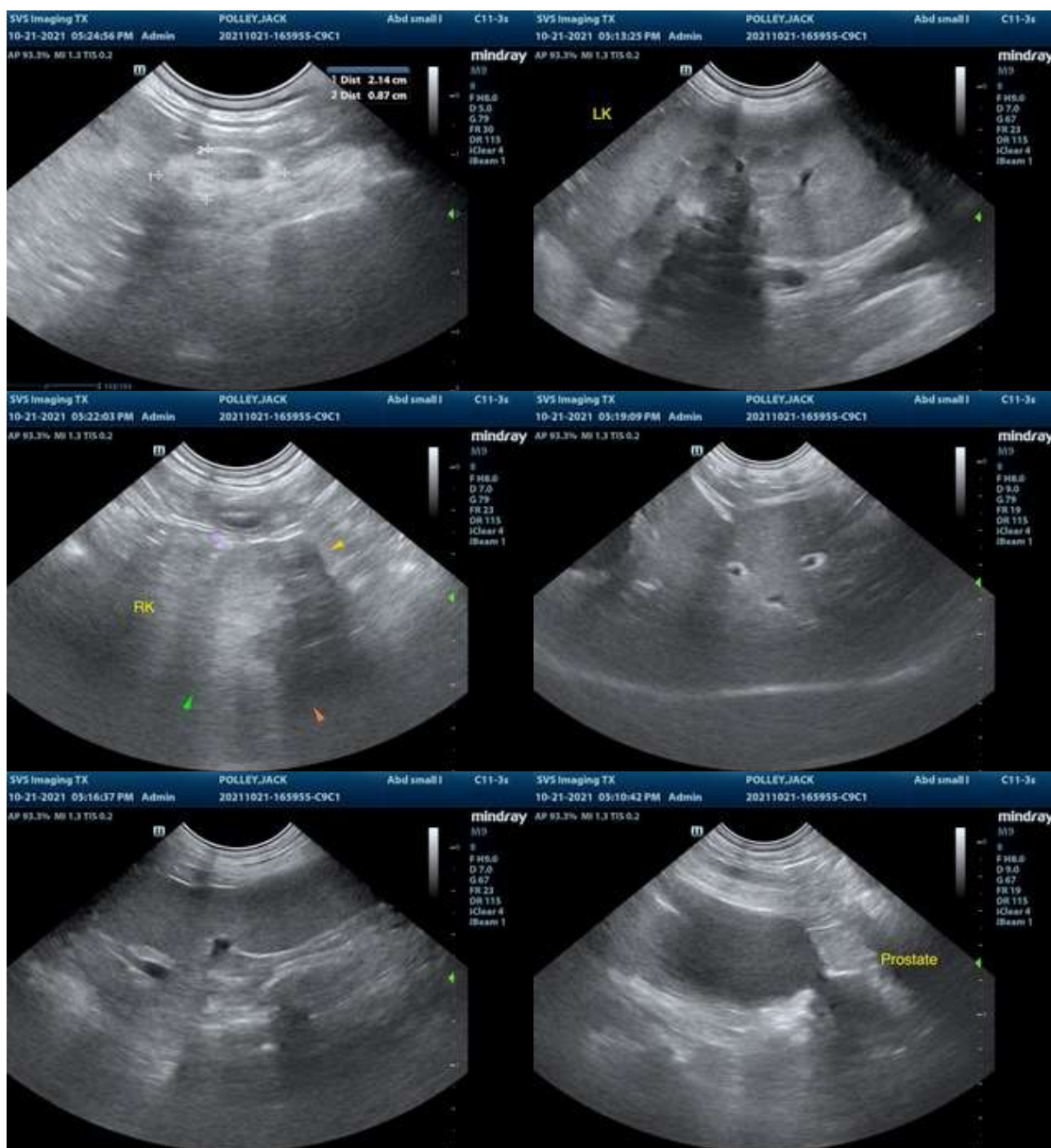
Dr Kreier, Badger
Veterinary Hospital
Janesville

INVOICE

47912

DATE

10-22-21





PATIENT

Jack Polley

SPECIES

Canine

BREED

Boxer

SEX

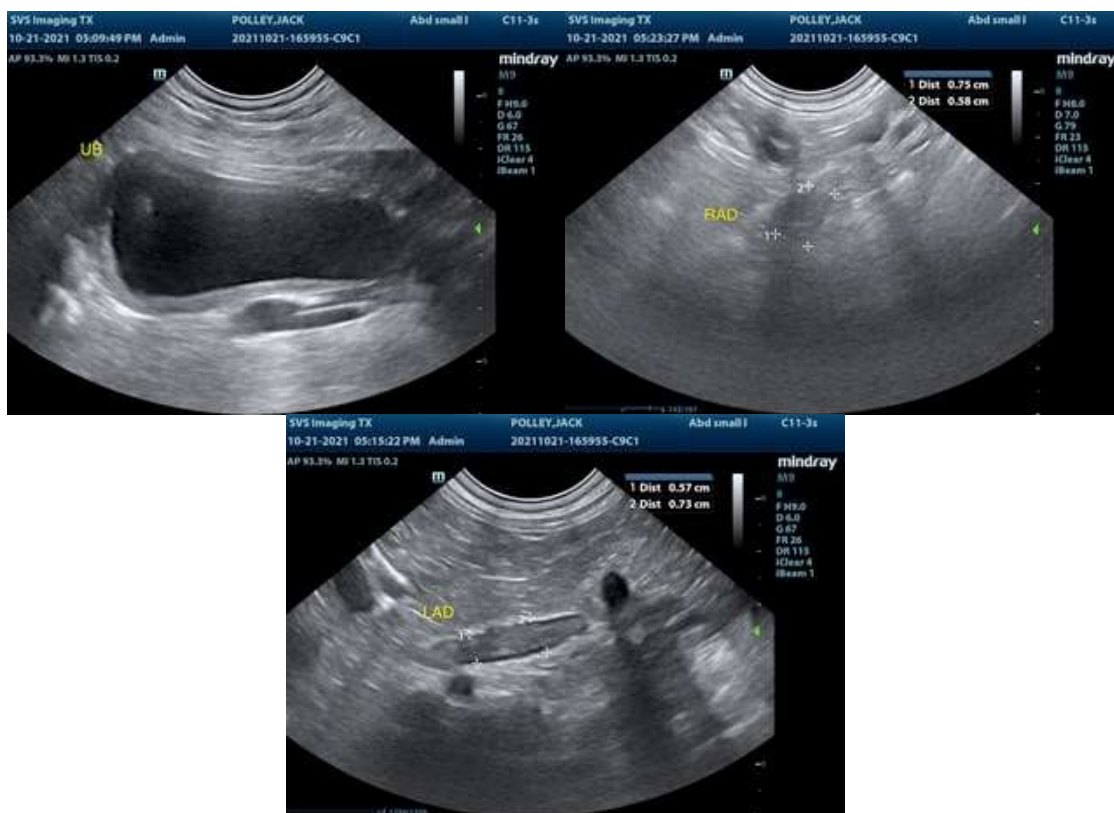
MN

AGE

11 Years

WEIGHT

67.6



INTERPRETED BY

R. McKenzie Daniel,
DVM, DABVP
(Canine and Feline)

IMAGING PERFORMED BY

Kim Liedberg

HOSPITAL NAME

SVS Imaging WI

REFERRING VET

Dr Kreier, Badger
Veterinary Hospital
Janesville

INVOICE

47912

DATE

10-22-21

The information and recommendations provided are based on the images presented by the referring veterinarian. No evaluation can be communicated regarding pathology that was not visible in the image/video clips provided.

Thank you for this referral. If the clinical or image interpretation does not parallel your findings or if I can be of any further assistance please contact me.

R. McKenzie Daniel, DVM, DABVP (Canine / Feline Practice)
info@SonoPath.com