

PATIENT PRESENTING CLINICAL SIGNS

Gabriela Hogan Appetite off, o felt was "bloating" looking yesterday. No V/D. Slightly tender cranial abdomen, full palpation difficult due to patient size.

SPECIES Abnormal PE/Chem/CBC/UA Results: CBC: PCV 33.5 %, WBC 17,800. Anemia hypochromic, poorly regenerative. Chem: Albumin 2.4, CK 396. Rest WNL U/A unremarkable, T4 0.9

Canine

ULTRASONOGRAPHIC EXAMINATION OF THE ABDOMEN

BREED *Urinary System*

Mastiff The urinary bladder was mildly subnormal in size owing to lack of urine distension. The urinary bladder, trigone, cystourethral junction, and visible pelvic urethra to a depth of 4.0 cm exhibited normal thickness and tone. No evidence of calculi or sediment. The ureteral papillae were normal. The ureters were not visible which is normal. No evidence of inflammatory or neoplastic changes were noted.

SEX

FS

No evidence of pathology in the area of the aortic trifurcation.

AGE

10 Years

Normal size and margination was present in the kidneys. A normal 1:3 cortex / medulla ratio was maintained. The medulla and cortices were uniform in texture with some increased echogenicity and mild loss of corticomedullary symmetry and definition expected for the age of the patient. No evidence of pelvic dilation was present. The left kidney measured 7.7 cm in length. The right kidney measured 9.2 cm in length.

WEIGHT

134 lbs

Adrenal Glands

INTERPRETED BY

R. McKenzie Daniel,
DVM, DABVP
(Canine and Feline)

The left adrenal gland exhibited mid to cranial enlargement with associated asymmetrical contour and parenchyma expansion yet without evidence of overt parenchymal escape or vascular invasion. Generalized left adrenal nonhomogeneous yet nonmineralized parenchyma was noted. The left adrenal gland measured 4.8 cm length x 2.6 cm width at the cranial pole and 0.85 cm width at the caudal pole. The area of mid to cranial left adrenal enlargement measured 3.6 x 2.7 cm.

IMAGING PERFORMED BY

Jenna Walsh, CVT

The right adrenal gland was not definitively visualized given the patient's size and conformation.

Spleen

HOSPITAL NAME

Cottage Grove
Veterinary Clinic

The discernible to visualized spleen exhibited primarily finely textured parenchyma which was hyperechoic to the liver and renal cortical parenchyma. Mild generalized parenchyma heterogeneity was present without evidence of nodular changes. The capsule was smooth and regular without apparent expansion. The splenic vasculature at the hilus was normal in volume with no evidence of congestion or thrombosis. The parenchymal heterogeneity is likely consistent with benign changes such as extramedullary hematopoiesis or age related remodeling with minor potential for inflammatory or neoplastic disease.

REFERRING VET

Dr. Damewood

Liver

INVOICE

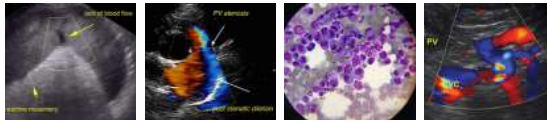
47926

The liver was subjectively normal in size, structure, and contour. The liver parenchyma was mildly nonuniform and hypoechoic to the spleen with a moderate coarse echotexture and subjective mild to benign parenchymal remodeling. The hepatic and portal vasculature were normal in appearance without signs of congestion.

DATE

10-22-21

The gallbladder was non-distended in size with thin walls and primarily anechoic luminal content. The cystic and common bile ducts were normal.



PATIENT *Gastrointestinal*

Gabriela Hogan The stomach presented intact wall layering with a normal wall layer ratio. The lumen of the stomach contained mild retained echogenic, non-shadowing ingesta and luminal gas without signs of obstruction or foreign material.

SPECIES

Canine The visualized small intestine presented intact wall layering with 1:3 muscularis/mucosa ratio. The lumen of the small intestine was empty with no signs of ileus, obstruction or foreign material.

BREED

Mastiff Normal visible colon wall layers were present with apparent formed feces in lumen.

SEX

FS

The parenchyma of the left limb, body and right limb of the pancreas presented isoechoic to the adjacent omental fat. A normal curvilinear capsule contour of the pancreas was present. The visible pancreatic duct was normal. No signs of active inflammation or neoplastic disease was evident.

AGE

10 Years

Free Abdomen

Large mid abdominal mildly hypoechoic to nonhomogeneous mass lesion was present with associated peripheral to regional echogenic mesentery with potential for adhesions. The mass measured approximately 10.0 cm in diameter. Potential for small amounts of scant associated peritoneal free fluid possible although no overt evidence of significant peritoneal effusion or concurrent lymphadenopathy. The mass was noted directly adjacent yet not overtly in contact or originating from the spleen as well as directly adjacent to and potentially involving adjacent small intestinal segments. The mass did not overly appear to involve the liver or bilateral kidneys.

WEIGHT

134 lbs

INTERPRETED BY

R. McKenzie Daniel,
DVM, DABVP
(Canine and Feline)

Brief sonographic assessment of the heart revealed no overt evidence of pericardial effusion or tumors.

ULTRASONOGRAPHIC FINDINGS

Primary

- Abdominal mass with regional reactive / inflamed mesentery and potential for adhesions.
- Hepatic parenchymal remodeling.
- Bilateral mild chronic renal changes.
- Cranial left adrenomegaly.

HOSPITAL NAME

Cottage Grove
Veterinary Clinic

REFERRING VET

Dr. Damewood

INTERPRETATION OF THE FINDINGS & FURTHER RECOMMENDATIONS

Although sampling or histopathology is required for further clarification, the abdominal mass is suggestive of neoplastic criteria with less likely potential for non-neoplastic etiologies. Given the size of the mass, as well as size of the patient, definitive origin of the mass was not overly evident. Non-obvious splenic or intestinal origin of the mass is considered probable although lymphatic, omental, or other origin possible.

INVOICE

47926

DATE

10-22-21

The cranial left adrenomegaly may indicate adenomatous change, benign hyperplasia with potential for primary or metastatic neoplasia. Screening blood pressure recommended.

Ultrasound guided FNA of the mass, assuming normal clotting status, could be considered for screening cytology and potential further clarification. If surgical options are a possibility, abdominal CT for further assessment of both the mass and the left adrenal gland as well as surgical planning, recommended. Three view chest radiographs suggested if not done.



PATIENT

Gabriela Hogan

SPECIES

Canine

BREED

Mastiff

SEX

FS

AGE

10 Years

WEIGHT

134 lbs

INTERPRETED BY

R. McKenzie Daniel,
DVM, DABVP
(Canine and Feline)

IMAGING PERFORMED BY

Jenna Walsh, CVT

HOSPITAL NAME

Cottage Grove
Veterinary Clinic

REFERRING VET

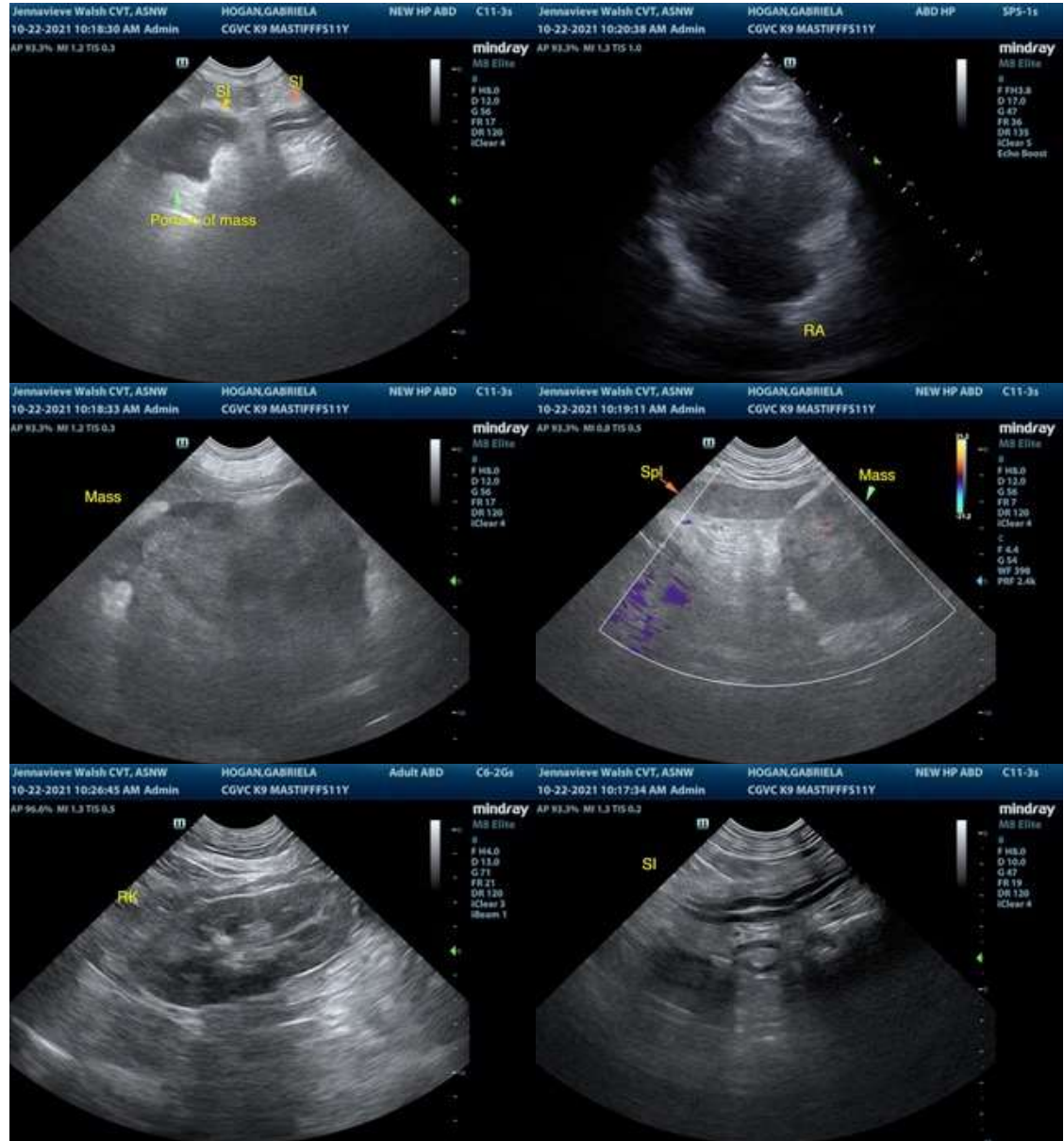
Dr. Damewood

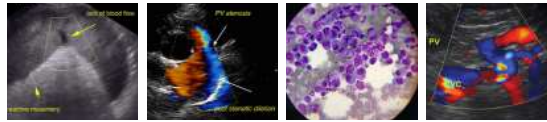
INVOICE

47926

DATE

10-22-21





PATIENT

Gabriela Hogan

SPECIES

Canine

BREED

Mastiff

SEX

FS

AGE

10 Years

WEIGHT

134 lbs

INTERPRETED BY

R. McKenzie Daniel,
DVM, DABVP
(Canine and Feline)

IMAGING PERFORMED BY

Jenna Walsh, CVT

HOSPITAL NAME

Cottage Grove
Veterinary Clinic

REFERRING VET

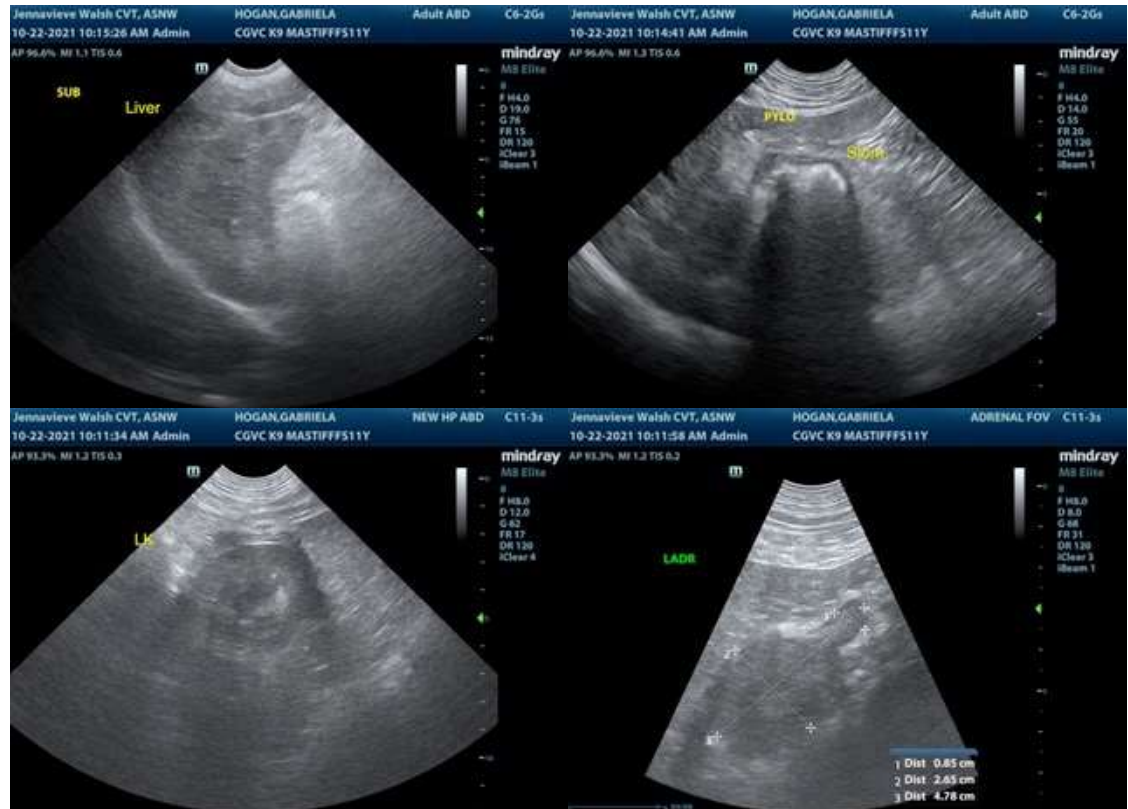
Dr. Damewood

INVOICE

47926

DATE

10-22-21



The information and recommendations provided are based on the images presented by the referring veterinarian. No evaluation can be communicated regarding pathology that was not visible in the image/video clips provided.

Thank you for this referral. If the clinical or image interpretation does not parallel your findings or if I can be of any further assistance please contact me.

R. McKenzie Daniel, DVM, DABVP (Canine / Feline Practice)
info@SonoPath.com