



PATIENT

Charlie Marzi

PRESENTING CLINICAL SIGNS

recheck ultrasound for wt loss and vomiting; dog is now stable and doing well

SPECIES

Canine

ULTRASONOGRAPHIC EXAMINATION OF THE ABDOMEN

Urinary System

The urinary bladder, trigone, cystourethral junction, and visible pelvic urethra to a depth of 4.0 cm exhibited normal thickness and tone. Anechoic urine was present in the lumen with no uroliths or sediment. The ureteral papillae were normal. The ureters were not visible which is normal. No evidence of inflammatory or neoplastic changes were noted.

BREED

Labrador Retriever X

No evidence of pathology in the area of the residual prostate or aortic trifurcation.

SEX

Neutered Male

Normal size and margination were present in the kidneys. A normal 1:3 cortex / medulla ratio and normal corticomedullary definition were maintained. The echogenicity of the cortex was similar to or slightly less than normal liver parenchyma while the medulla echogenicity was hypoechoic to the cortex with no evidence of pelvic dilation. The left kidney measured 6.9 cm. The right kidney measured 7.2 cm.

AGE

8 Years

Adrenal Glands

The adrenal glands were uniform in size and contour with a uniformly hypoechoic parenchyma. The left adrenal gland measured 2.0 cm length x 0.60 cm at the caudal pole. The right adrenal gland measured 2.6 cm length x 0.69 cm at the caudal pole.

WEIGHT

76 Pounds

Spleen

The spleen exhibited a finely textured and homogenous parenchyma which was hyperechoic to the liver and renal cortical parenchyma. The capsule was smooth and regular without apparent expansion. The splenic vasculature at the hilus was normal in volume with no evidence of congestion or thrombosis. Acute to chronic inflammatory, neoplastic, or benign parenchyma changes were not noted.

INTERPRETED BY

R. McKenzie Daniel,
DVM, DABVP
(Canine and Feline)

Liver

The liver was subjectively normal in size, structure, and contour. The liver parenchyma was uniform and hypoechoic to the spleen with a mild coarse echotexture. The hepatic and portal vasculature were normal in appearance without signs of congestion. The gallbladder was non-distended in size with thin walls and primarily anechoic luminal content. The cystic and common bile ducts were normal.

IMAGING PERFORMED BY

Diane McFadden

Gastrointestinal

The stomach presented intact wall layering with a normal wall layer ratio. Minor retained echogenic ingesta and chyme present. Gastric body wall measured 0.62 cm. Pylorus wall measured 0.66 cm.

HOSPITAL NAME

Rockaway AH

The small intestine presented intact wall layering with 1:3 muscularis/mucosa ratio. The lumen of the small intestine was empty with no signs of ileus, obstruction or foreign material.

REFERRING VET

Dr. Maniar

Normal visible colon wall layers were present with apparent formed feces in lumen.

INVOICE

26599

Pancreas

The parenchyma of the left limb, body and right limb of the pancreas presented isoechoic to the adjacent omental fat. A normal curvilinear capsule contour of the pancreas was present. The visible pancreatic duct was normal. No signs of active inflammation or neoplastic disease was evident.

DATE

10/22/21



PATIENT

Charlie Marzi

ULTRASONOGRAPHIC FINDINGS

- Sonographically unremarkable abdomen
- Minor ingesta and chyme present in stomach

SPECIES

Canine

INTERPRETATION OF THE FINDINGS & FURTHER RECOMMENDATIONS

The appearance of the stomach was similar to the previous ultrasound with minor retained ingesta and chyme and without evidence of gastrointestinal foreign material or structural mural pathology. The minor retained gastric ingesta is non-specific, yet not overtly consistent with persistent gastric stasis or delayed gastric emptying given the mild amount of retained ingesta and chyme. Given the patient's current stable clinical state, continued as needed supportive care is recommended.

BREED

Labrador Retriever X

SEX

Neutered Male

AGE

8 Years

WEIGHT

76 Pounds

INTERPRETED BY

R. McKenzie Daniel,
DVM, DABVP
(Canine and Feline)

IMAGING PERFORMED BY

Diane McFadden

HOSPITAL NAME

Rockaway AH

REFERRING VET

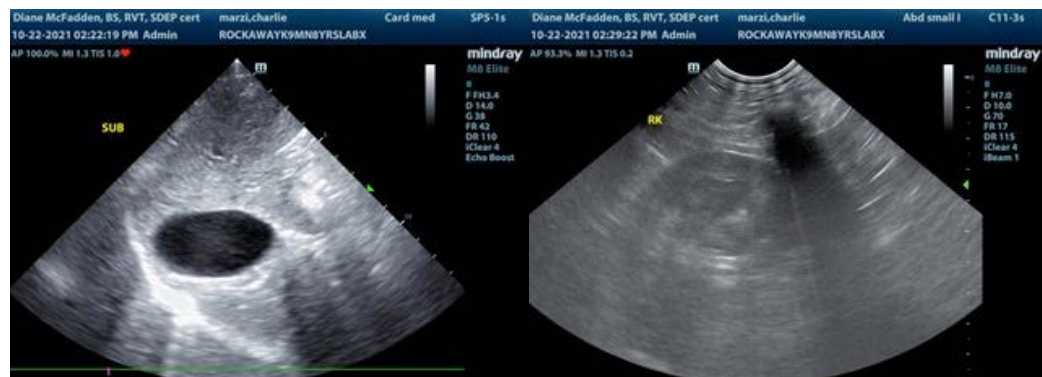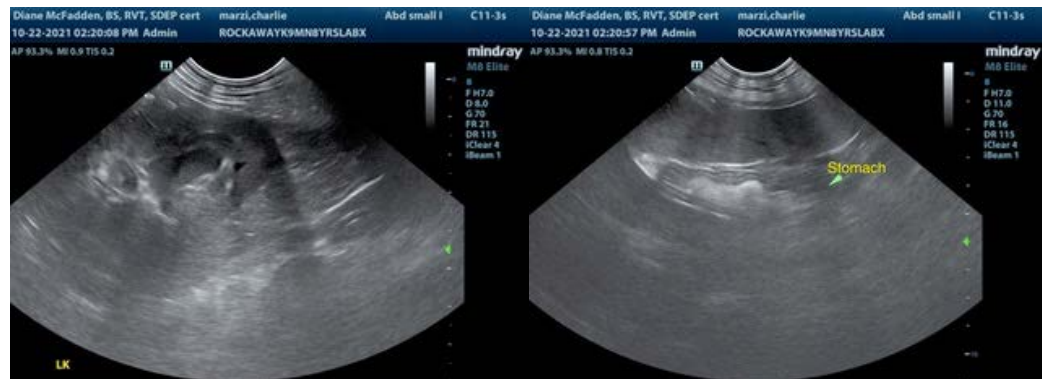
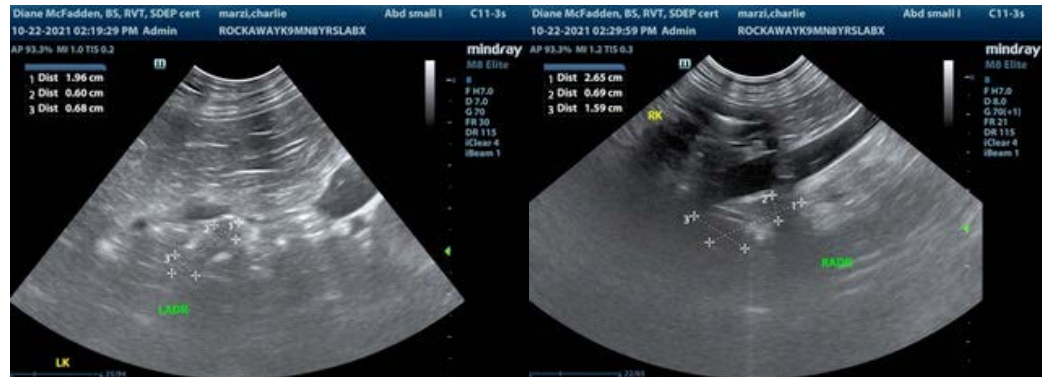
Dr. Maniar

INVOICE

26599

DATE

10/22/21





PATIENT

Charlie Marzi

SPECIES

Canine

BREED

Labrador Retriever X

SEX

Neutered Male

AGE

8 Years

WEIGHT

76 Pounds

INTERPRETED BY

R. McKenzie Daniel,
DVM, DABVP
(Canine and Feline)

IMAGING PERFORMED BY

Diane McFadden

HOSPITAL NAME

Rockaway AH

REFERRING VET

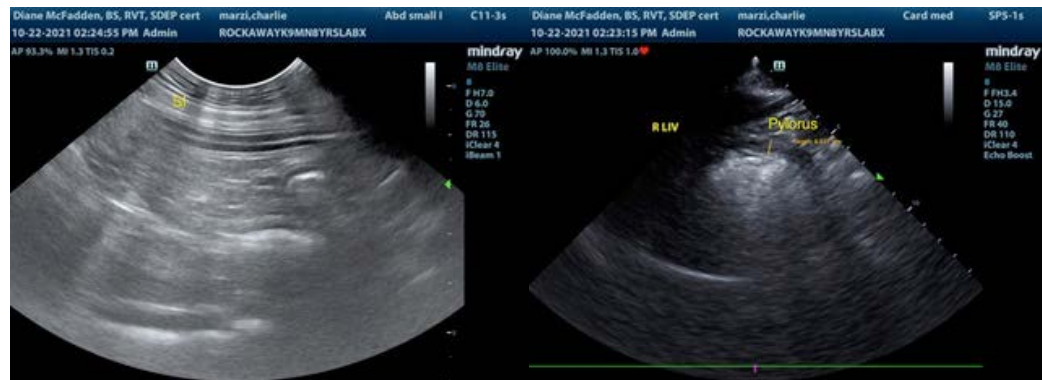
Dr. Maniar

INVOICE

26599

DATE

10/22/21



The information and recommendations provided are based on the images presented by the referring veterinarian. No evaluation can be communicated regarding pathology that was not visible in the image/video clips provided.

Thank you for this referral. If the clinical or image interpretation does not parallel your findings or if I can be of any further assistance please contact me.

R. McKenzie Daniel, DVM, DABVP (Canine / Feline Practice)
info@SonoPath.com