



**PATIENT**

Sam Schwartz

**SPECIES**

Canine

**BREED**

Poodle Mix

**SEX**

MN

**AGE**

12 years

**WEIGHT**

27.8 lbs

**INTERPRETED BY**

R. McKenzie Daniel,  
DVM, DABVP  
(Canine and Feline)

**IMAGING PERFORMED BY**

Kim Liedberg

**HOSPITAL NAME**

SVS Imaging WI

**REFERRING VET**

Dr Wiegel, Elkorn  
Veterinary Clinic

**INVOICE**

12424

**DATE**

10/21/21

**PRESENTING CLINICAL SIGNS**

weight loss, elevated liver enzymes still eating

Abnormal PE/Chem/CBC/UA Results: ALP 238 AST69 ALT 1115 PI WNL CBC WNL Bilirubin, GGT all normal,

**ULTRASONOGRAPHIC EXAMINATION OF THE ABDOMEN**

**Urinary System**

The urinary bladder, trigone, cystourethral junction, and visible pelvic urethra to a depth of 3.0 cm exhibited normal thickness and tone. Anechoic urine was present in the lumen with no uroliths or sediment. The ureteral papillae were normal. The ureters were not visible which is normal. No evidence of inflammatory or neoplastic changes was noted.

The residual prostate was symmetrically normal in size with uniform parenchyma and slight coarse echotexture measuring 0.79 cm in diameter.

The area of the aortic trifurcation was free of pathology.

Normal size and margination were present in the kidneys. A normal 1:3 cortex / medulla ratio was maintained. The medulla and cortices were uniform in texture with some increased echogenicity and moderate loss of corticomedullary symmetry and definition expected for the age of the patient. Small cortical cysts were present. No evidence of pelvic dilation was present. The left kidney measured 5.7 cm in length. The right kidney measured 5.7 cm in length.

**Adrenal Glands**

The left adrenal gland was uniform in size and contour with a uniformly hypoechoic parenchyma. The left adrenal gland measured 0.58 cm width at the caudal pole and 0.72 cm width at the cranial pole. The right adrenal gland was uniform in size and contour with a uniformly hypoechoic parenchyma. The right adrenal gland measured 0.68 cm width at the caudal pole and 0.78 cm width at the cranial pole.

**Spleen**

The spleen exhibited primarily finely textured parenchyma which was hyperechoic to the liver and renal cortical parenchyma. Mild generalized parenchyma heterogeneity was present without evidence of nodular changes. The capsule was smooth and regular without apparent expansion. The splenic vasculature at the hilus was normal in volume with no evidence of congestion or thrombosis. The parenchymal heterogeneity is likely consistent with benign changes such as extramedullary hematopoiesis or age-related remodeling with minor potential for inflammatory or neoplastic disease.

**Liver/ Gallbladder**

The liver was subjectively normal in size, structure, and contour. The liver exhibited generalized nonhomogeneous to mildly mixed echogenic parenchyma with a moderate coarse echotexture. The hepatic and portal vasculature were normal in appearance without signs of congestion. A moderately sized, nonuniform to mild mixed echogenic mass occupying the majority of the mid to right liver was present, extending caudally to the approximate level of the gastric axis. The mass measured approximately 10.0 cm in diameter. Multifocal cystic areas within the areas of the mass were noted.



**PATIENT**

Sam Schwartz

The gallbladder was non-distended in size with mild gallbladder debris. No evidence of peripheral inflammation. The common bile duct was sonographically unremarkable.

**SPECIES**

Canine

**Gastrointestinal**

The stomach presented intact wall layering with a normal wall layer ratio. The lumen of the stomach was empty with no signs of ileus, obstruction, or foreign material.

**BREED**

Poodle Mix

The small intestine presented intact wall layering with 1:3 muscularis/mucosa ratio. Intermittent minor jejunal mucosal speckling was noted. The lumen of the small intestine was empty with no signs of ileus, obstruction, or foreign material. The duodenum wall width measured 0.39 cm.

**SEX**

MN

Normal visible colon wall layers were present with apparent formed feces in lumen.

**AGE**

12 years

**Pancreas**

The pancreas was normal in size and contour with isoechoic to heterogeneous parenchyma compared to adjacent omentum. No signs of active inflammation or neoplasia.

**WEIGHT**

27.8 lbs

**Free Abdomen**

No overt lymphadenopathy or peritoneal effusion was present.

**ULTRASONOGRAPHIC FINDINGS**

**Primary Findings**

- Chronic hepatopathy with mid to right mass
- Mild gallbladder debris (non-mucocele)
- Bilateral chronic renal changes with cortical cysts
- Possible minor enteritis

**INTERPRETED BY**

R. McKenzie Daniel,  
DVM, DABVP  
(Canine and Feline)

**INTERPRETATION OF THE FINDINGS & FURTHER RECOMMENDATIONS**

**IMAGING PERFORMED BY**

Kim Liedberg

Assuming normal clotting status, ultrasound guided FNA of the mid to right hepatic mass is warranted for further clarification. Neoplasia is favored, given the patient's weight loss, yet potential for benign etiologies is possible.

**HOSPITAL NAME**

SVS Imaging WI

**REFERRING VET**

Dr Wiegel, Elkorn  
Veterinary Clinic

A GI panel to include PLI/TLI/Cobalamin/Folate may be considered for assessment for concurrent gastrointestinal disease in light of the patient's weight loss. Three view chest radiographs are recommended.

**INVOICE**

12424

**DATE**

10/21/21



**PATIENT**

Sam Schwartz

**SPECIES**

Canine

**BREED**

Poodle Mix

**SEX**

MN

**AGE**

12 years

**WEIGHT**

27.8 lbs

**INTERPRETED BY**

R. McKenzie Daniel,  
DVM, DABVP  
(Canine and Feline)

**IMAGING PERFORMED BY**

Kim Liedberg

**HOSPITAL NAME**

SVS Imaging WI

**REFERRING VET**

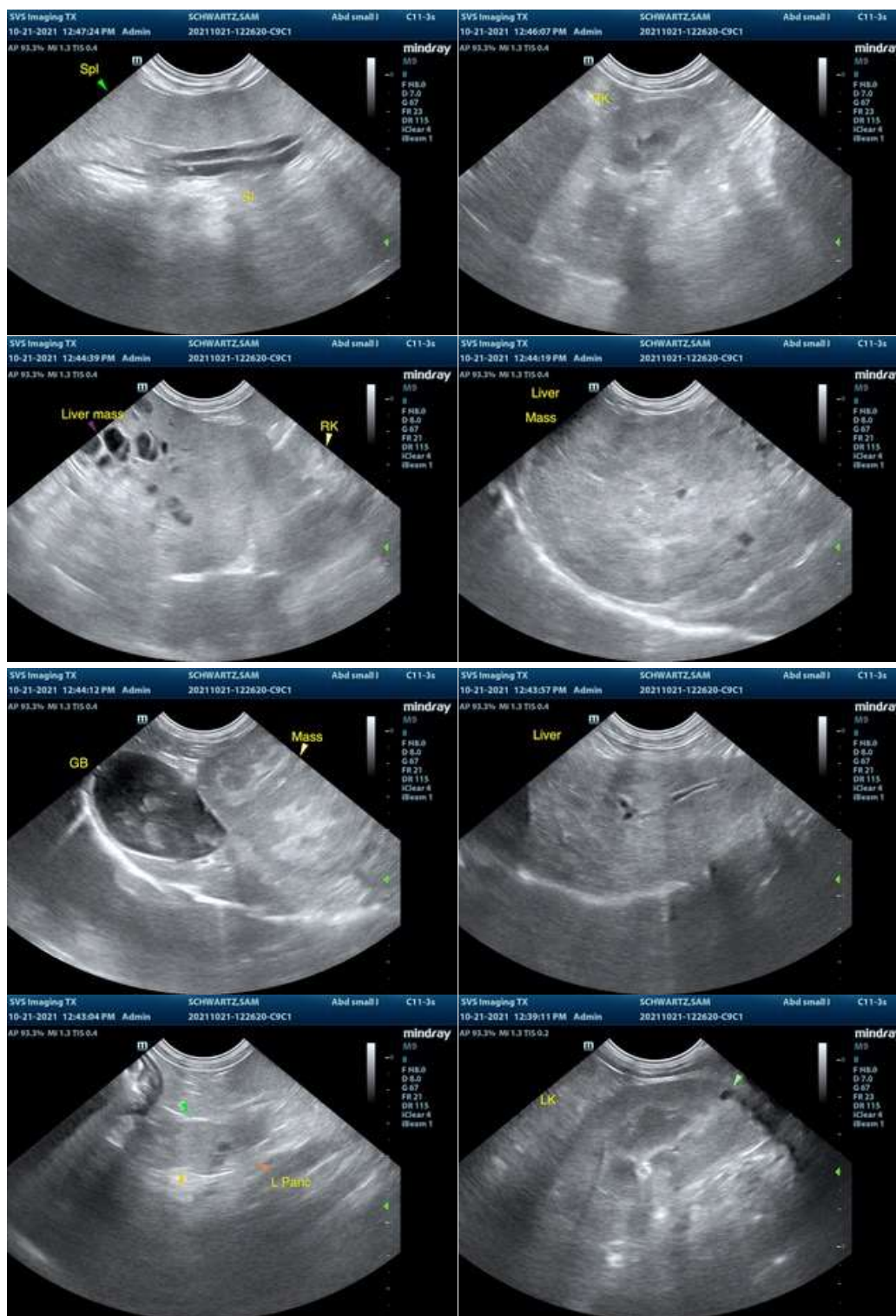
Dr Wiegel, Elkorn  
Veterinary Clinic

**INVOICE**

12424

**DATE**

10/21/21



2.7



**PATIENT**

Sam Schwartz

**SPECIES**

Canine

**BREED**

Poodle Mix

**SEX**

MN

**AGE**

12 years

**WEIGHT**

27.8 lbs

**INTERPRETED BY**

R. McKenzie Daniel,  
DVM, DABVP  
(Canine and Feline)

**IMAGING PERFORMED BY**

Kim Liedberg

**HOSPITAL NAME**

SVS Imaging WI

**REFERRING VET**

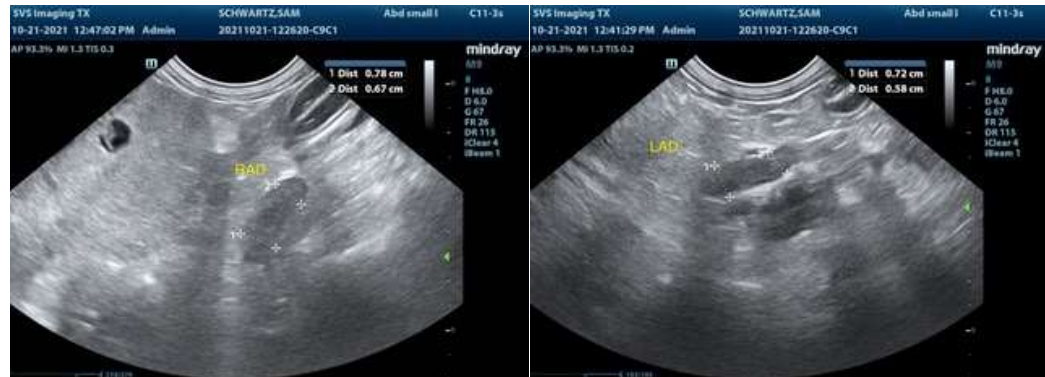Dr Wiegel, Elkorn  
Veterinary Clinic

**INVOICE**

12424

**DATE**

10/21/21



The information and recommendations provided are based on the images presented by the referring veterinarian. No evaluation can be communicated regarding pathology that was not visible in the image/video clips provided.

Thank you for this referral. If the clinical or image interpretation does not parallel your findings or if I can be of any further assistance please contact me.

**R. McKenzie Daniel, DVM, DABVP (Canine / Feline Practice)**  
info@SonoPath.com