

**PATIENT**

Bella Hojnacki

SPECIES

Canine

BREED

Shih Tzu

SEX

SF

AGE

7 years

WEIGHT

14 lbs.

INTERPRETED BY

R. McKenzie Daniel,
DVM, DABVP
(Canine and Feline)

IMAGING PERFORMED BY

Sarah Pender, CVT

HOSPITAL NAME

SVS Imaging QC

REFERRING VET

Dr. Sullivan

INVOICE

12402

DATE

10/21/21

PRESENTING CLINICAL SIGNS

Presented in beginning of September for diarrhea of 1 week duration, improved on metronidazole and proviable; returned at beginning of October and was refilled but did not improve and began vomiting. Returned today for recheck examination due to occasional vomiting and inappetence. Abnormal PE/Chem/CBC/UA Results: Fecal negative; lost 3# in past month; mass palpable in cranial abdomen and visible on radiographs. Have not performed blood work yet.

ULTRASONOGRAPHIC EXAMINATION OF THE ABDOMEN**Urinary System**

The urinary bladder, trigone, cystourethral junction, and visible pelvic urethra to a depth of 2.0 cm exhibited normal thickness and tone. Anechoic urine was present in the lumen with no uroliths or sediment. The ureteral papillae were normal. The ureters were not visible which is normal. No evidence of inflammatory or neoplastic changes was noted.

The area of the aortic trifurcation was free of pathology.

Normal size and margination were present in the kidneys. A normal 1:3 cortex / medulla ratio was maintained. The medulla and cortices were uniform in texture with some increased echogenicity and mild loss of corticomedullary symmetry and definition expected for the age of the patient. Nonobstructive areas of medullary mineralization, primarily in the lateral diverticuli of both kidneys, were noted. No evidence of pelvic dilation was present. The left kidney measured 4.2 cm in length. The right kidney measured 4.8 cm in length.

Adrenal Glands

The left adrenal gland was uniform in size and contour with a uniformly hypoechoic parenchyma. The left adrenal gland measured 2.4 cm length x 0.51 cm width at the caudal pole. The right adrenal gland was uniform in size and contour with a uniformly hypoechoic parenchyma. The right adrenal gland measured 1.8 cm length x 0.43 cm width at the caudal pole.

Spleen

The spleen exhibited a finely textured and homogenous parenchyma which was hyperechoic to the liver and renal cortical parenchyma. The capsule was smooth and regular without apparent expansion. The splenic vasculature at the hilus was normal in volume with no evidence of congestion or thrombosis. Acute to chronic inflammatory, neoplastic, or benign parenchyma changes were not noted.

Liver/ Gallbladder

The liver presented normal in size. The hepatic parenchyma revealed diffuse reduced echogenicity compared to the spleen and renal cortical parenchyma with a mild coarse echotexture. Increased portal vein prominence was evident. The capsule of the liver was normal in margination. Distinct masses or nodules were not evident. The hepatic and portal vasculature were normal in appearance. The gallbladder was non-distended in size with primarily anechoic luminal content. The cystic and common bile ducts were normal.

**PATIENT**

Bella Hojnacki

SPECIES

Canine

BREED

Shih Tzu

SEX

SF

AGE

7 years

WEIGHT

14 lbs.

INTERPRETED BYR. McKenzie Daniel,
DVM, DABVP
(Canine and Feline)**IMAGING
PERFORMED BY**

Sarah Pender, CVT

HOSPITAL NAME

SVS Imaging QC

REFERRING VET

Dr. Sullivan

INVOICE

12402

DATE

10/21/21

Gastrointestinal

The stomach presented wall thickening secondary to echogenic mucosa hypertrophy. Intact wall layering was maintained and distinct. The pylorus wall measured 0.45 cm width. Mild gastric distension was present. Minor retained anechoic fluid was present in the lumen without evidence of retained ingesta or foreign material.

Moderately sized to large, expansive intestinal mural mass exhibiting marked mural hypertrophy, decreased mural echogenicity and loss of distinct wall layering was present in the mid to cranial abdomen. Concurrent thickened intestine exhibiting intact to indistinct wall layering and variable mural hypertrophy was noted adjacent to and potentially entering the intestinal mural mass. The duodenum and additional segments of jejunum exhibited intact, sonographically unremarkable wall layering. The duodenum wall width measured 0.39 cm. Normal-appearing jejunum wall width measured 0.36 cm. The intestinal mural mass potentially measured 7.0-8.0 cm in length with the bulk of the mass measuring 6.5 cm x 4.7 cm, exhibiting wall width measuring up to 2.2 cm.

The visualized colon was sonographically unremarkable exhibiting intact wall layering with subjective semi-formed to soft feces.

Pancreas

The parenchyma of the left limb, body, and right limb of the pancreas presented isoechoic to the adjacent omental fat. A normal curvilinear capsule contour of the pancreas was present. The visible pancreatic duct was normal. No signs of active inflammation or neoplastic disease were evident.

Free Abdomen

Regional echogenic mesentery was noted around the intestinal mass along with concurrent mildly swollen to hypoechoic peri intestinal lymphadenopathy and small pockets of scant free fluid. An example of a lymph node measured 2.5 cm x 1.1 cm.

ULTRASONOGRAPHIC FINDINGS***Primary Findings***

- Large intestinal mural mass with associated mild regional peritonitis and peri intestinal lymphadenopathy
- Thickened Intestine with intact yet altered wall layering adjacent to intestinal mass
- Mild gastritis and gastric stasis
- Subjectively hypoechoic liver

Secondary Findings

- Bilateral nonobstructive renal medullary mineralization

INTERPRETATION OF THE FINDINGS & FURTHER RECOMMENDATIONS

The intestinal mass, likely jejunal in location, is most consistent with neoplastic criteria such as lymphoma, adenocarcinoma, stromal tumor, or other. Potential for possible regional omental seeding and early neoplastic lymphadenopathy is of concern, although not definitive. Likewise, additional



PATIENT

Bella Hojnacki

SPECIES

Canine

BREED

Shih Tzu

SEX

SF

AGE

7 years

WEIGHT

14 lbs.

INTERPRETED BY

R. McKenzie Daniel, DVM, DABVP (Canine and Feline)

IMAGING PERFORMED BY

Sarah Pender, CVT

HOSPITAL NAME

SVS Imaging QC

REFERRING VET

Dr. Sullivan

INVOICE

12402

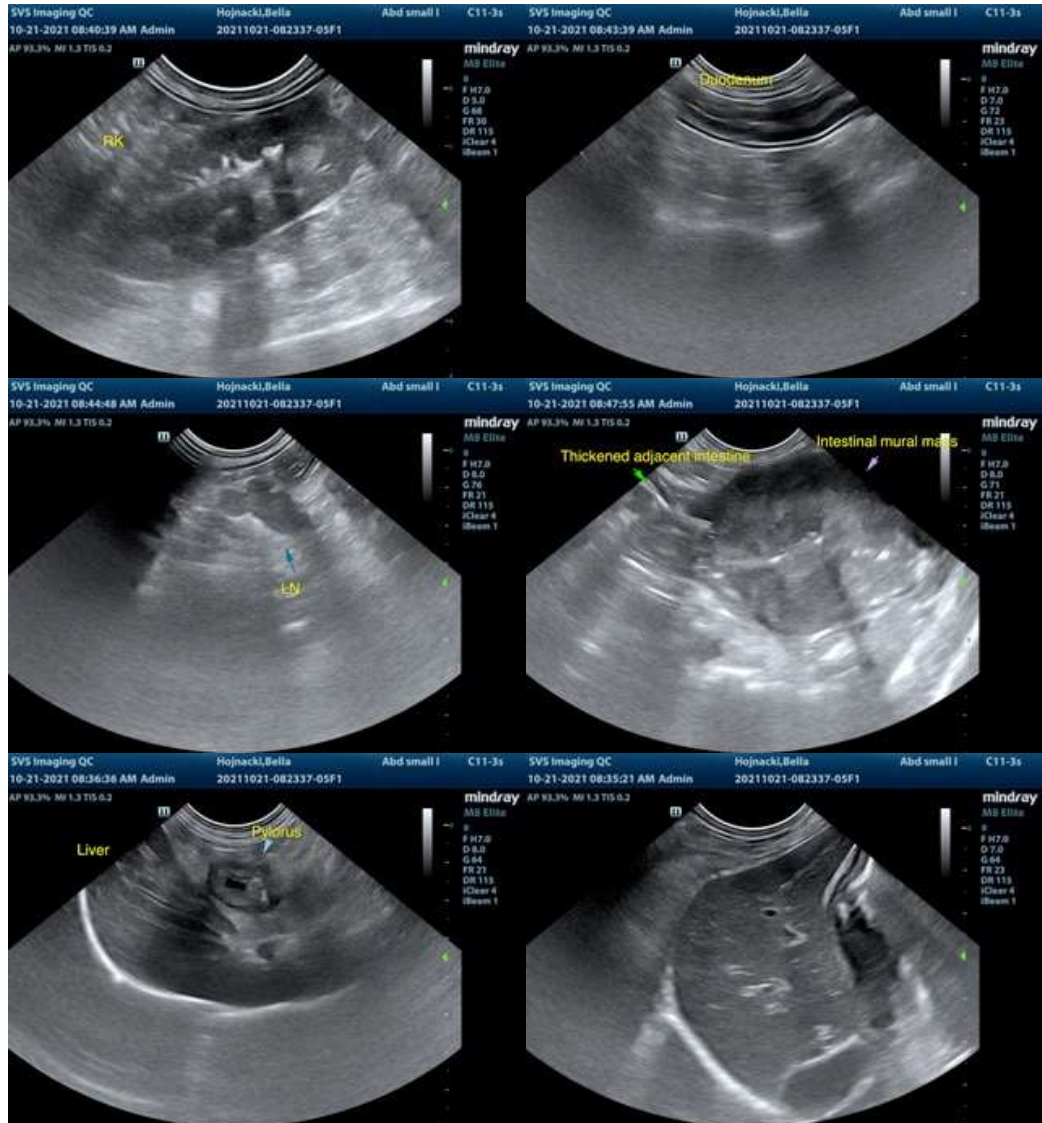
DATE

10/21/21

segments of adjacent small intestine are suggestive of concurrent infiltrative pattern with the overall extent of intestinal involvement difficult to ascertain.

The mildly hypoechoic liver is nonspecific and may indicate patient variant, reactive hepatopathy, concurrent hepatitis, while the possibility of multicentric neoplasia potentially involving the liver cannot be excluded.

Assuming normal clotting status, ultrasound-guided FNA of the intestinal mural mass, as well as the liver for further clarification, may be considered. If no evidence of thoracic metastasis on three view chest radiographs and no cytological evidence of hepatic neoplasia, laparotomy for gross inspection, potential resection anastomosis, intestinal and lymphatic biopsies may be considered. A very guarded long term prognosis is warranted.





PATIENT

Bella Hojnacki

SPECIES

Canine

BREED

Shih Tzu

SEX

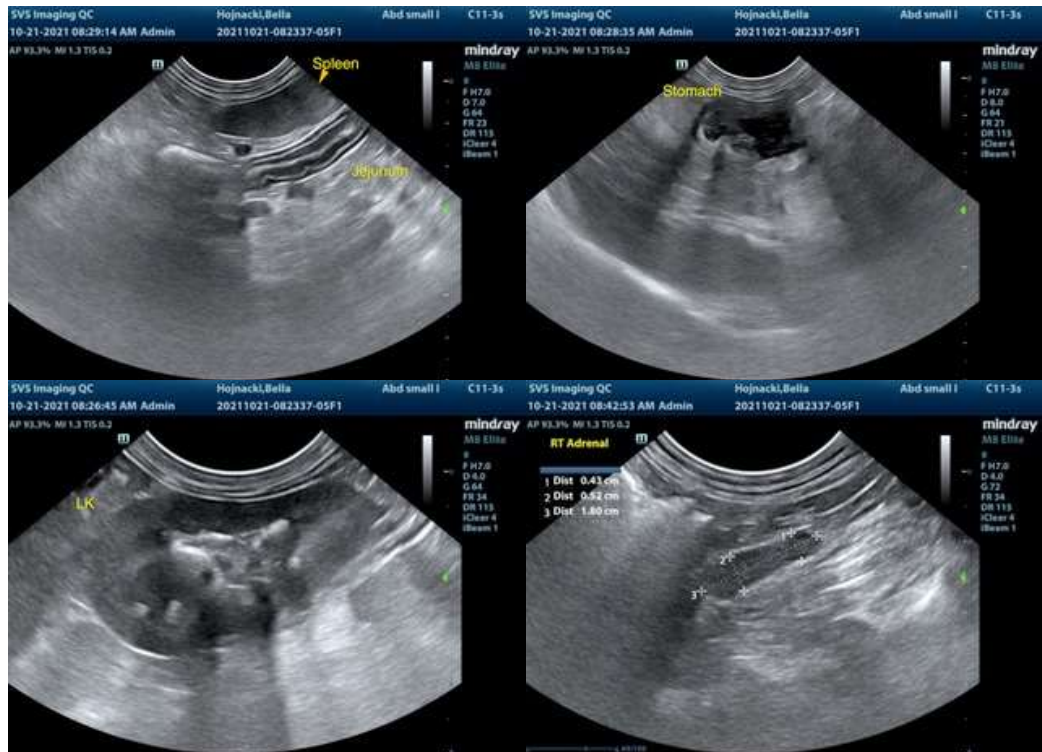
SF

AGE

7 years

WEIGHT

14 lbs.



INTERPRETED BY

R. McKenzie Daniel, DVM, DABVP (Canine and Feline)

IMAGING PERFORMED BY

Sarah Pender, CVT

HOSPITAL NAME

SVS Imaging QC

REFERRING VET

Dr. Sullivan

INVOICE

12402

DATE

10/21/21

The information and recommendations provided are based on the images presented by the referring veterinarian. No evaluation can be communicated regarding pathology that was not visible in the image/video clips provided.

Thank you for this referral. If the clinical or image interpretation does not parallel your findings or if I can be of any further assistance please contact me.

R. McKenzie Daniel, DVM, DABVP (Canine / Feline Practice)
info@SonoPath.com