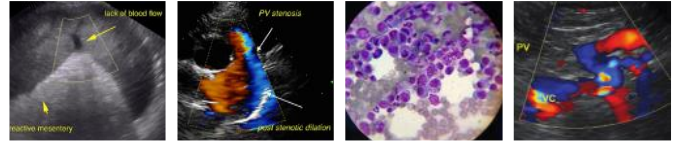




PATIENT	PRESENTING CLINICAL SIGNS
Petey Rodriguez	Hx of R H digit amputation, BX: Fibrosarcoma, High-grade. no other medical hx was reported.
SPECIES	Abnormal PE/Chem/CBC/UA Results: PE BCS 4/9 Muscle waste A cranial abdominal mass was palpated. BW: 9/21/22 CBC: Lymphocytes: 710 (L) 1200-8000. CHEM: BUN: 13 (L) 14-36. UA: Not performed. T4: WNL. BX: 10/11/22 BX: Fibrosarcomas, High-Grade BX
Feline	
BREED	ULTRASONOGRAPHIC EXAMINATION OF THE ABDOMEN
	Urinary System
DSH	The urinary bladder, trigone, cystourethral junction, and visible pelvic urethra to a depth of 2 cm exhibited normal thickness and tone. Anechoic urine was present in the lumen with mild non-dependent particulate sediment. The sediment may indicate cellular debris / protein, crystalline debris, lipid, or mucus. The ureteral papillae were normal. The ureters were not visible which is normal. No evidence of inflammatory or neoplastic changes were noted.
SEX	
MN	
AGE	Normal size and margination were present in the kidneys. A normal 1:3 cortex / medulla ratio and normal corticomedullary definition were maintained. The echogenicity of the cortex was similar to or slightly less than normal liver parenchyma while the medulla echogenicity was hypoechoic to the cortex with no evidence of pelvic dilation. The left kidney measured 4.0 cm in length. The right kidney measured 4.0 cm in length.
NA	
WEIGHT	The area of the aortic trifurcation was free of pathology.
9lb	The area of the iliac trifurcation was free of pathology including no evidence of medial, iliac or sublumbar lymphadenopathy.
INTERPRETED BY	Adrenal Glands
R. McKenzie Daniel, DVM, DABVP (Canine and Feline)	The bilateral adrenal glands were normal in size and contour. Pinpoint areas of mineralization were present without capsular distortion or overt tumors. This is an age-related finding and not pathological. The left adrenal gland measured 0.31 width and the right adrenal gland measured 0.35 width.
IMAGING PERFORMED BY	Spleen
Jose	The spleen exhibited primarily finely textured parenchyma which was hyperechoic to the liver and renal cortical parenchyma. Mild generalized parenchyma heterogeneity was present without evidence of nodular changes. The capsule was smooth and regular without apparent expansion. The splenic vasculature at the hilus was normal in volume with no evidence of congestion or thrombosis. The parenchymal heterogeneity is likely consistent with benign changes such as extramedullary hematopoiesis or age-related remodeling with minor potential for inflammatory or neoplastic disease. The spleen measured 0.79 cm in width at the level of the hilus.
HOSPITAL NAME	Liver
Animal Clinic of Queens	The liver exhibited overall normal size, structure, and contour. The liver parenchyma was uniform and hypoechoic to the spleen with a mild coarse echotexture. The hepatic and portal vasculature were normal in appearance without signs of congestion. The gallbladder was non-distended in size with thin walls and primarily anechoic luminal content. The cystic and common bile ducts were normal.
REFERRING VET	Gastrointestinal
Dr. Thomas	The stomach presented intact wall layering with a normal wall layer ratio. The lumen of the stomach contained mild retained anechoic fluid with no signs of ileus, obstruction or foreign material.
INVOICE	
11962ag	
DATE	
10/20/2022	



PATIENT

Petey Rodriguez

The small intestine presented intact wall layering with 1:3 muscularis/mucosa ratio. The lumen of the small intestine was empty with no signs of ileus, obstruction or foreign material.

Normal visible colon wall layers were present with apparent formed feces in lumen.

SPECIES

Pancreas

Feline

The pancreas base was normal to mildly prominent in size with subtle hypoechoic parenchyma compared to the adjacent omental fat. A normal curvilinear capsule contour of the pancreas was present. The visible pancreatic duct was normal.

BREED

Free Abdomen

DSH

No overt lymphadenopathy or peritoneal effusion was present.

SEX

A well demarcated undifferentiated homogeneous to mildly hypoechoic mass was present in the cranial abdomen which appeared to efface the caudal aspect of the mid to right liver. The mass exhibited potential for portal vasculature along with focal small cystic component. The mass measured ~4.2 cm x 3.6 cm. Subtle evidence of peripheral hyperechoic mesentery was noted.

MN

AGE

ULTRASONOGRAPHIC FINDINGS

NA

- Uniform cranial abdominal mass in the area of the caudal liver
- Mildly prominent to hypoechoic pancreas-nonspecific, potential for patient variant, low grade pancreatitis possible
- Mild urinary bladder sediment

WEIGHT

9lb

Secondary

-

INTERPRETED BY

R. McKenzie Daniel,
DVM, DABVP
(Canine and Feline)

INTERPRETATION OF THE FINDINGS & FURTHER RECOMMENDATIONS

The cranial abdominal mass is suspected to be of hepatic origin given the location and is concerning for metastatic or neoplastic criteria. Potential for non-hepatic origin of the mass along with benign etiologies cannot be definitively excluded. Assuming normal clotting status and using a 25g needle, an abdominal mass FNA for screening cytology is warranted for further assessment and potential oncology consult. No overt evidence of additional intra-abdominal neoplastic or metastatic criteria. A spec fPL may be considered if clinically indicated.

Three view chest radiographs are recommended if not done to assess for occult thoracic pathology.

IMAGING PERFORMED BY

Jose

HOSPITAL NAME

Animal Clinic of
Queens

REFERRING VET

Dr. Thomas

INVOICE

11962ag

DATE

10/20/2022



PATIENT

Petey Rodriguez

SPECIES

Feline

BREED

DSH

SEX

MN

AGE

NA

WEIGHT

9lb

INTERPRETED BY

R. McKenzie Daniel,
DVM, DABVP
(Canine and Feline)

IMAGING PERFORMED BY

Jose

HOSPITAL NAME

Animal Clinic of
Queens

REFERRING VET

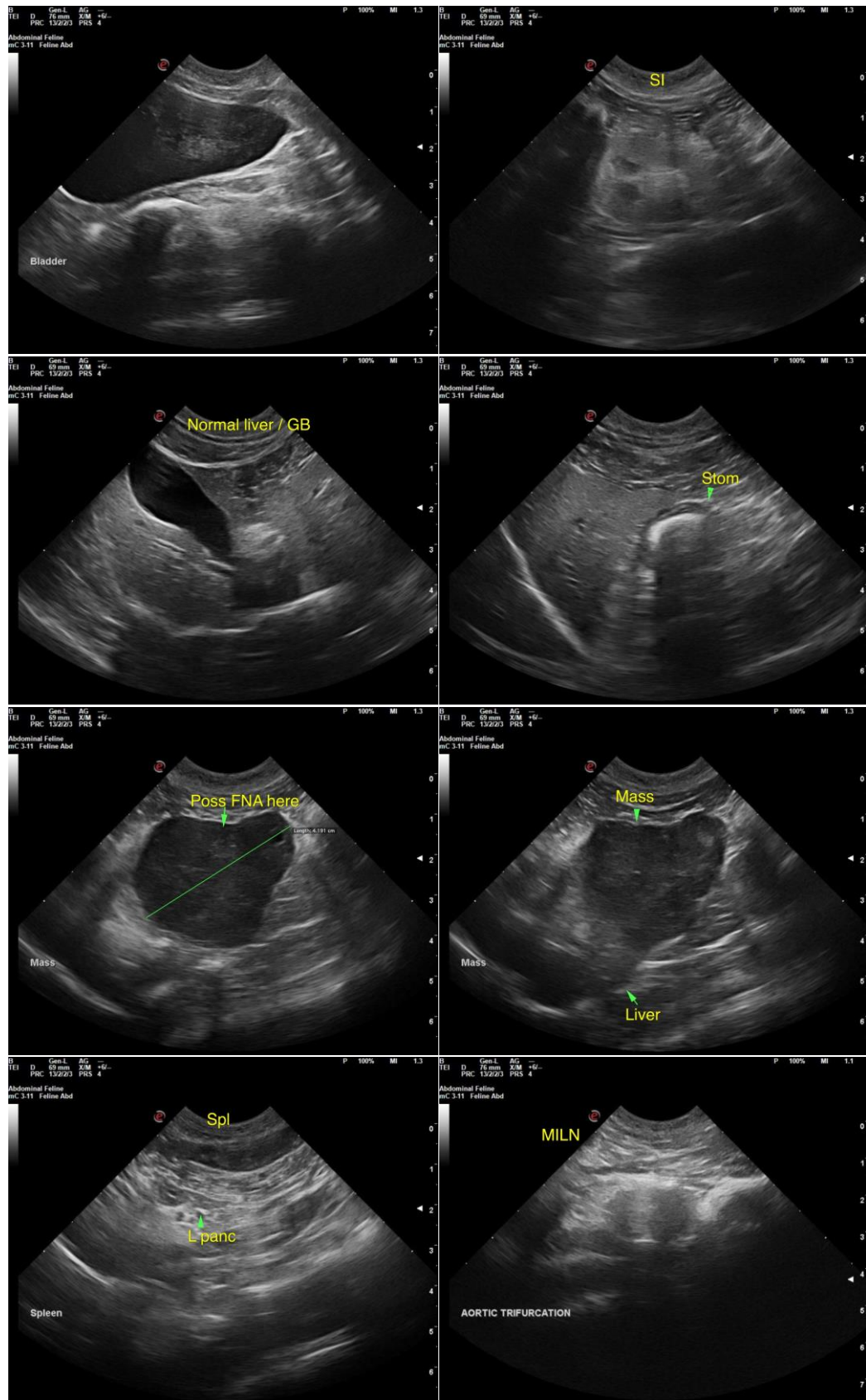
Dr. Thomas

INVOICE

11962ag

DATE

10/20/2022





PATIENT

Petey Rodriguez

SPECIES

Feline

BREED

DSH

SEX

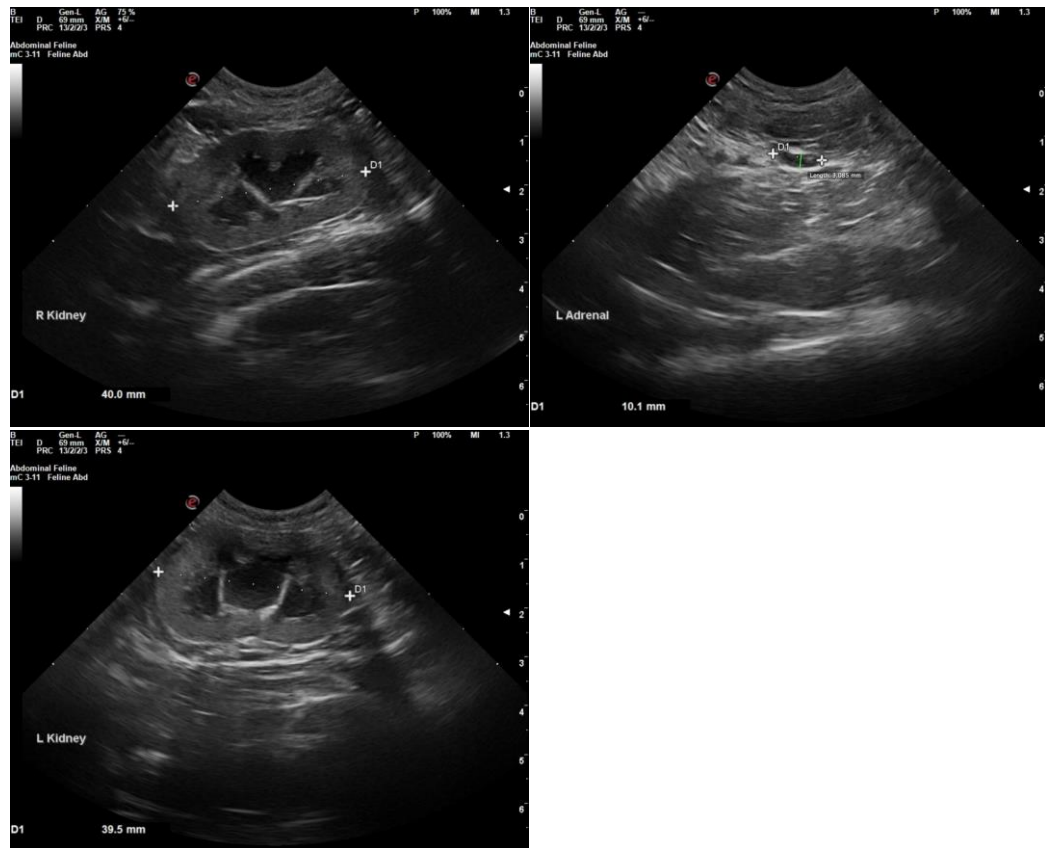
MN

AGE

NA

WEIGHT

9lb



INTERPRETED BY

R. McKenzie Daniel,
DVM, DABVP
(Canine and Feline)

IMAGING PERFORMED BY

Jose

HOSPITAL NAME

Animal Clinic of
Queens

REFERRING VET

Dr. Thomas

INVOICE

11962ag

DATE

10/20/2022

The information and recommendations provided are based on the images presented by the referring veterinarian/sonographer. No evaluation can be communicated regarding pathology that was not visible in the image/video clips provided.

Thank you for this referral. If the clinical or image interpretation does not parallel your findings or if I can be of any further assistance please contact me.

R. McKenzie Daniel, DVM, DABVP (Canine / Feline Practice)

info@SonoPath.com