SonoPath
Clinical Sonography & Telecytology

EDUCATIONAL TELECONSULTATION SERVICES™

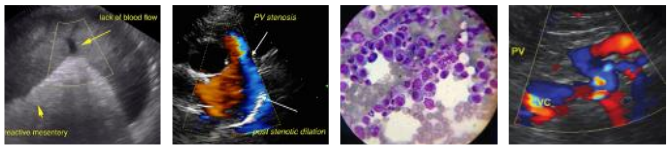

SonoPath.com
1-800-838-4268 info@sonopath.com

PATIENT

Monty Pedrazoli

SPECIES

Feline

BREED

DSH

SEX

MN

AGE

10yr

WEIGHT

13.6lb

INTERPRETED BY

R. McKenzie Daniel, DVM, DABVP (Canine and Feline)

IMAGING PERFORMED BY

Meredith Swart

HOSPITAL NAME

Swart Veterinary Imaging

REFERRING VET

Meredith Swart

INVOICE

11955ag

DATE

10/20/2022

PRESENTING CLINICAL SIGNS

Recently diagnosed with hyperthryoidism. Patient is currently on methimazole but is planning to pursue I131. Bicavitary ultrasound today is in preparation for I131 treatment in next couple weeks. AUS also performed and was unremarkable. No reported clinical signs or murmur

Abnormal PE/Chem/CBC/UA Results: Pending labwork being performed today

ULTRASONOGRAPHIC EXAMINATION OF THE HEART

FELINE CARDIAC PARAMETERS	BODY WEIGHT (kg)	HR (BPM)	IVSd (cm)	LVIDd (cm)	LVWd (cm)	FS (%)	EF (%)
NORMAL PARAMETER	------	150-240	0.3-0.6	1.0-2.1	0.25-0.6	35-67	80-100
PATIENT		NM	0.46	1.24	0.46	54	93
FELINE CARDIAC PARAMETERS	**LA/AO** (Boon)	**LA/AO HEART BASE** (Sisson)	**LA** 2D 4-chamber long axis AS to FW (Sisson) (cm)		**LVOT VEL.** (m/s)	**RVOT VEL.** (m/s)	**IVRT** (m/)
NORMAL PARAMETER	<1.5	0.88-1.79	0.7-1.7		<1.6	<1.3	40-60
PATIENT		1.3	0.2		1.0	0.73	

Adapted from June Boon,Veterinary Echocardiography,1998
Sisson D et al. JVIM 1991; 5: 232, Jacobs et al. Am J Vet Res 1985; 46:1705

Cardiac Presentation

The left ventricular wall was remodeled with regions of mild asymmetry. Overtly normal endocardium echogenicity was present with potential for mild LV fibrosis. Mildly prominent to remodeled papillary muscles were present. LV systolic function was adequate as evidenced by the FS measurement. No evidence of LV or RV enlargement. The left atrium was normal in size with anechoic content. No evidence of LA spontaneous contrast or smoke. The right atrium is normal in size. The mitral valve exhibited mild thickening without overt MR on Doppler. No obvious TR on Doppler. Blood flow through the LVOT and RVOT was normal in measured velocity. No evidence of pericardial or pleural effusion. No cardiac tumors were present.

ULTRASONOGRAPHIC FINDINGS

- Overtly normal cardiac function with mild LV myocardial remodeling
- Normal left atrium

INTERPRETATION OF THE FINDINGS & FURTHER RECOMMENDATIONS

No evidence of overt structural or functional cardiomyopathy with mild LV myocardial remodeling present. This does not appear to be a functional issue at this stage given normal LV functionality and lack of LA enlargement. No indication for cardiac medications. Recheck echo recommended in 6-12 months, sooner if clinical signs of cardiac disease arise.

SonoPath

Clinical Sonography & Telecytology

EDUCATIONAL TELECONSULTATION SERVICES™

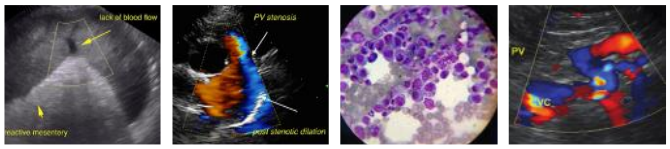

SonoPath.com

1-800-838-4268 info@sonopath.com

PATIENT

Monty Pedrazoli

SPECIES

Feline

BREED

DSH

SEX

MN

AGE

10yr

WEIGHT

13.6lb

INTERPRETED BY

R. McKenzie Daniel, DVM, DABVP (Canine and Feline)

IMAGING PERFORMED BY

Meredith Swart

HOSPITAL NAME

Swart Veterinary Imaging

REFERRING VET

Meredith Swart

INVOICE

11955ag

DATE

10/20/2022

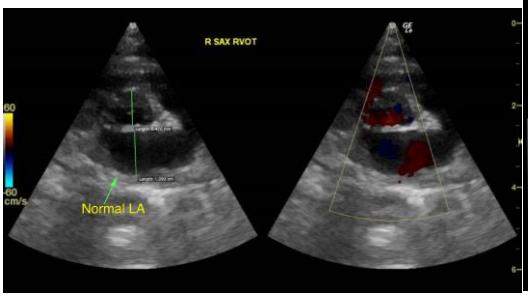

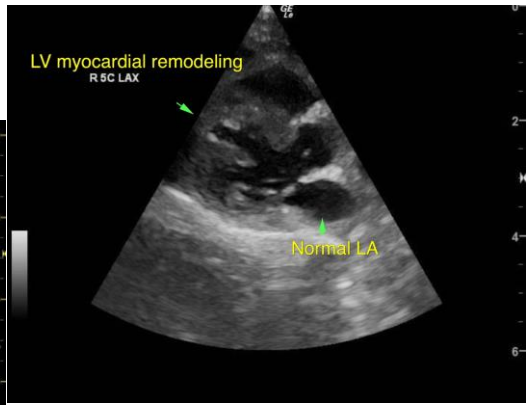

The information and recommendations provided are based on the images presented by the referring veterinarian/sonographer. No evaluation can be communicated regarding pathology that was not visible in the image/video clips provided.

Thank you for this referral. If the clinical or image interpretation does not parallel your findings or if I can be of any further assistance please contact me.

R. McKenzie Daniel, DVM, DABVP (Canine / Feline Practice)

info@SonoPath.com