

**PATIENT**

Sam Stout

**SPECIES**

Feline

**BREED**

DSH

**SEX**

MN

**AGE**

13yr

**WEIGHT**

7.2lb

**INTERPRETED BY**R. McKenzie Daniel,  
DVM, DABVP  
(Canine and Feline)**IMAGING  
PERFORMED BY**

Amy Mayhew LVT

**HOSPITAL NAME**SVS Imaging  
Michigan**REFERRING VET**Milford Veterinary  
Clinic**INVOICE**

11931ag

**DATE**

10/19/2022

**PRESENTING CLINICAL SIGNS**

Fogginess in the lung field suggested infection in the lungs. Much improved on medications.

Abnormal PE/Chem/CBC/UA Results: Chems &amp; TT4 normal CBC- within normal limits except increase in basophils. Suspicious area mediastinum. Please see attached radiographs.

**ULTRASONOGRAPHIC EXAMINATION OF THE THORAX*****Thoracic Presentation***

Sonographic assessment of the lung revealed generalized aerated lung exhibiting generalized reverberation artifact. No evidence of space occupying peripheral pulmonary nodules or masses. No evidence of pleural effusion. The area of the cranial mediastinum was free of overt pathology. Subjective cardiac assessment revealed overtly normal cardiac structure and function given sedation without evidence of left or right heart chamber enlargement.

**ULTRASONOGRAPHIC FINDINGS**

- Generalized aerated lung exhibiting reverberation artifact
- Subjective normal heart

**INTERPRETATION OF THE FINDINGS & FURTHER RECOMMENDATIONS**

No obvious evidence of primary pulmonary pathology such as consolidated lung, pulmonary nodules, masses or evidence of pleural effusion. No obvious evidence of cranial mediastinal lesions although air interference obstructing definitive acoustic window to potential intrapulmonary or cranial mediastinal pathology was present. This could indicate lower airway disease not visible with ultrasound. Lower airway sampling is likely required for definitive diagnosis. Thoracic CT could be considered if strong concern for cranial mediastinal pathology.

IMAGING PERFORMED BY

SVS Mobile Imaging MI 734-637-7711  
svsimagingmi@gmail.com



**PATIENT**

Sam Stout

**SPECIES**

Feline

**BREED**

DSH

**SEX**

MN

**AGE**

13yr

**WEIGHT**

7.2lb

**INTERPRETED BY**

R. McKenzie Daniel,  
DVM, DABVP  
(Canine and Feline)

**IMAGING PERFORMED BY**

Amy Mayhew LVT

**HOSPITAL NAME**

SVS Imaging  
Michigan

**REFERRING VET**

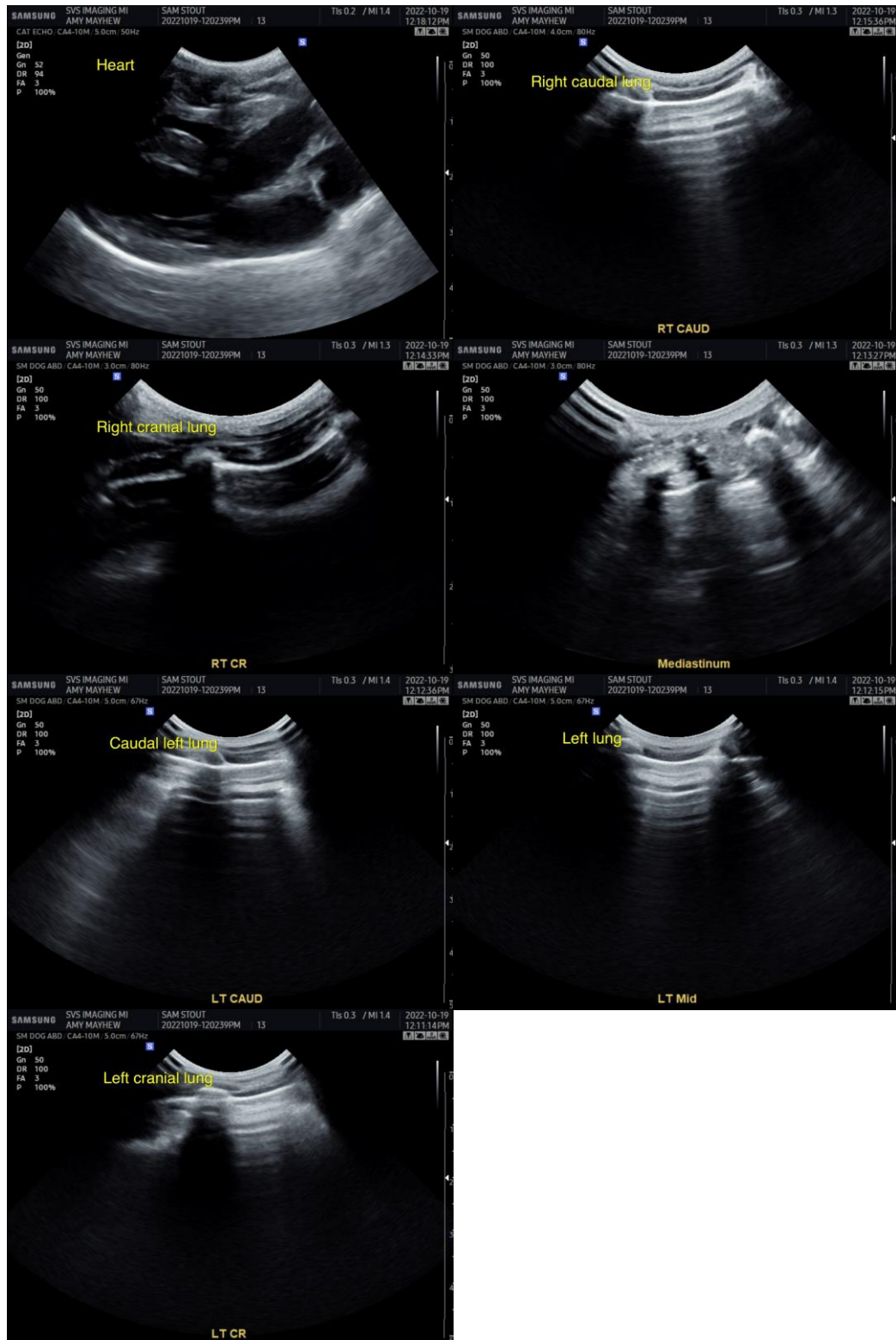
Milford Veterinary  
Clinic

**INVOICE**

11931ag

**DATE**

10/19/2022



The information and recommendations provided are based on the images presented by the referring veterinarian/sonographer. No evaluation can be communicated regarding pathology that was not visible in the image/video clips provided.

**IMAGING PERFORMED BY**

SVS Mobile Imaging MI 734-637-7711  
svsimagingmi@gmail.com



EDUCATIONAL TELECONSULTATION SERVICES™

1-800-838-4268 info@sonopath.com SonoPath.com

**PATIENT**

Sam Stout

Thank you for this referral. If the clinical or image interpretation does not parallel your findings or if I can be of any further assistance please contact me.

R. McKenzie Daniel, DVM, DABVP (Canine / Feline Practice)

**SPECIES**

info@SonoPath.com

Feline

**BREED**

DSH

**SEX**

MN

**AGE**

13yr

**WEIGHT**

7.2lb

**INTERPRETED BY**

R. McKenzie Daniel,  
DVM, DABVP  
(Canine and Feline)

**IMAGING  
PERFORMED BY**

Amy Mayhew LVT

**HOSPITAL NAME**

SVS Imaging  
Michigan

**REFERRING VET**

Milford Veterinary  
Clinic

**INVOICE**

11931ag

**DATE**

10/19/2022