



PATIENT PRESENTING CLINICAL SIGNS

Mia Rattan History: Elevated liver values, pot belly appearance, pre surgical
 Unremarkable CBC. Chem – ALP 1394.

SPECIES ULTRASONOGRAPHIC EXAMINATION OF THE ABDOMEN

Canine **Urinary System**

BREED

Cocker Spaniel Mix

The urinary bladder, trigone, cystourethral junction, and visible pelvic urethra to a depth of 3.0 cm exhibited normal thickness and tone. Anechoic urine was present in the lumen. Pinpoint areas of dependent mineral were present. The ureteral papillae were normal. The ureters were not visible which is normal. No evidence of inflammatory or neoplastic changes were noted.

SEX

FS

Normal size and margination were present in the kidneys. A normal 1:3 cortex / medulla ratio was maintained. The medulla and cortices were uniform in texture with some increased echogenicity and loss of corticomedullary symmetry and definition expected for the age of the patient. No evidence of pelvic dilation was present. Non-obstructive medullary mineral was present, primarily in the lateral diverticuli of both kidneys. The left kidney measured 4.6 cm. The right kidney measured 4.5 cm.

AGE

10 years

The area of the aortic trifurcation was free of pathology.

Adrenal Glands

WEIGHT

15.9 Pounds

The adrenal glands were uniform in size and contour with a uniformly hypoechoic parenchyma. No evidence of hyperplasia, adrenal tumors or nodules. The left adrenal gland measured 1.6 cm length x 0.49 cm at the caudal pole. The right adrenal gland measured 1.7 cm length x 0.51 cm at the caudal pole

Spleen

INTERPRETED BY

R. McKenzie Daniel,
 DVM, DABVP
 (Canine and Feline)

The spleen exhibited primarily finely textured and homogenous parenchyma which was hyperechoic to the liver and renal cortical parenchyma. Multifocal, well-defined, symmetrical, echogenic nodules were present primarily in the medial parenchyma adjacent to the hilus and potentially involving the capsule. The capsule was smooth and regular without apparent expansion. The splenic vasculature at the hilus was normal in volume with no evidence of congestion or thrombosis. Acute to chronic inflammatory or neoplastic changes were not noted. The echogenic nodules tend to trend benign and are most consistent with benign hyperplasia or myelolipomas.

IMAGING PERFORMED BY

Rebekah Jakum, CVT
 ARDMS/RVT

Liver

HOSPITAL NAME

Easton AH

The liver exhibited potential mild generalized enlargement. The parenchyma of the liver was subjectively normal in echogenicity compared to the spleen and renal cortices. The liver parenchyma was uniform with a mildly coarse echotexture. The capsule of the liver was symmetrically rounded to mildly swollen in margination. The hepatic and portal vasculature were normal in appearance without signs of congestion. The gallbladder was non distended in size with mild non-dependent yet non-organized debris. The cystic duct and common bile ducts were normal without evidence of dilation.

REFERRING VET

Dr. Titcher

Gastrointestinal

INVOICE

26364

The stomach presented intact wall layering with a normal wall layer ratio. The lumen of the stomach was empty with no signs of ileus, obstruction or foreign material.

DATE

10.19.2021

The small intestine presented intact wall layering with 1:3 muscularis/mucosa ratio. The lumen of the small intestine was empty with no signs of ileus, obstruction or foreign material.

Normal visible colon wall layers were present with apparent formed feces in lumen.



PATIENT *Pancreas*

Mia Rattan The parenchyma of the left limb, body and right limb of the pancreas presented isoechoic to the adjacent omental fat. A normal curvilinear capsule contour of the pancreas was present. The visible pancreatic duct was normal. No signs of active inflammation or neoplastic disease was evident.

SPECIES

Canine *Free Abdomen*

No intraabdominal masses, lymphadenopathy or peritoneal effusion.

BREED

Cocker Spaniel Mix

ULTRASONOGRAPHIC FINDINGS

- Minor pinpoint urinary bladder mineral
- Bilateral mild chronic renal changes with non-obstructive medullary mineral
- Benign splenic nodules – probable myelolipomas, potential nodular hyperplasia, previous infarct, emerging mineralization, or capsular fibrosis.
- Vacuolar hepatopathy pattern – subjectively benign.
- Mild gallbladder debris (non-mucocele)

SEX

FS

AGE

10 years

INTERPRETATION OF THE FINDINGS & FURTHER RECOMMENDATIONS

Urine culture and sensitivity on sterile urine sample recommended to rule out underlying infection. It is suspected that this patient may be passing small amounts of mineral from the kidneys into the urinary bladder. Given the lack of reported clinical signs (i.e., PU/PD, polyphagia, etc.), and in light of the subjective normal bilateral adrenal glands, potential for hyperadrenocorticism is considered unlikely. However, further workup may be considered if clinical suspicion of hyperadrenocorticism. Hepatosupportive medications including Denamarin and Ursodiol may prove beneficial. No anesthetic contraindications given likely normal hepatic function in light of normal BUN, cholesterol, albumin and glucose levels.

WEIGHT

15.9 Pounds

INTERPRETED BY

R. McKenzie Daniel,
DVM, DABVP
(Canine and Feline)

IMAGING PERFORMED BY

Rebekah Jakum, CVT
ARDMS/RVT

HOSPITAL NAME

Easton AH

REFERRING VET

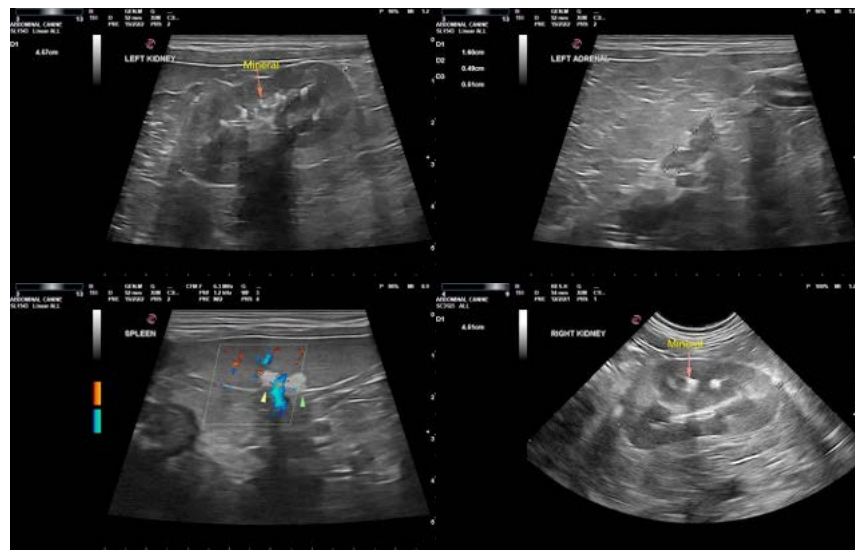Dr. Titcher

INVOICE

26364

DATE

10.19.2021





PATIENT

Mia Rattan

SPECIES

Canine

BREED

Cocker Spaniel Mix

SEX

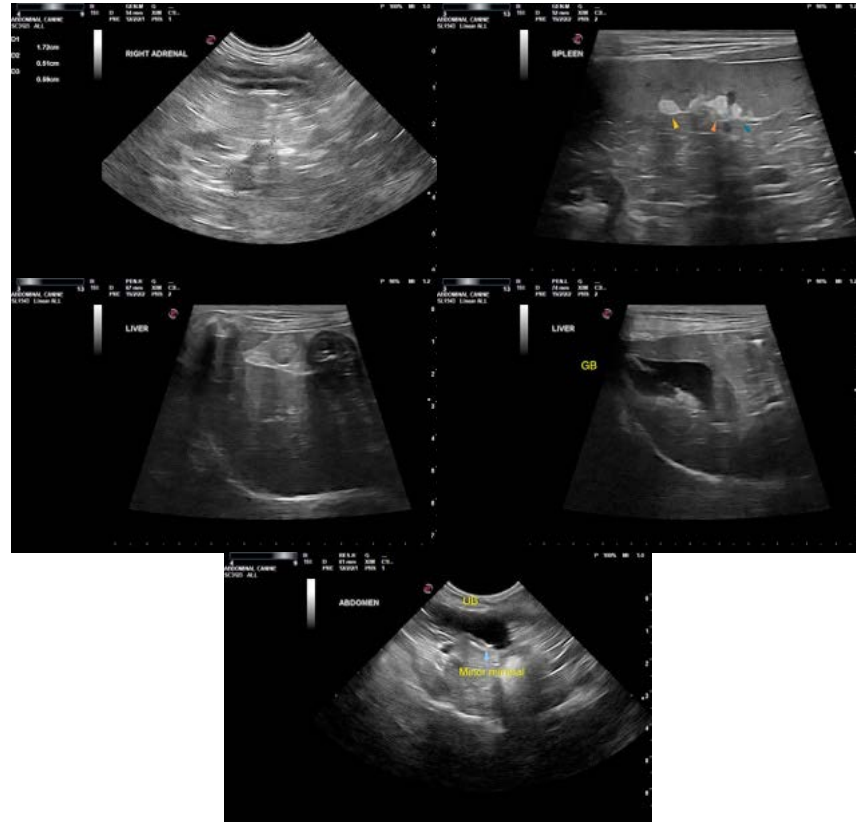
FS

AGE

10 years

WEIGHT

15.9 Pounds



INTERPRETED BY

R. McKenzie Daniel,
DVM, DABVP
(Canine and Feline)

The information and recommendations provided are based on the images presented by the referring veterinarian. No evaluation can be communicated regarding pathology that was not visible in the image/video clips provided.

IMAGING PERFORMED BY

Rebekah Jakum, CVT
ARDMS/RVT

Thank you for this referral. If the clinical or image interpretation does not parallel your findings or if I can be of any further assistance please contact me.

R. McKenzie Daniel, DVM, DABVP (Canine/Feline Practice)

mac.daniel@sonopath.com

HOSPITAL NAME

Easton AH

REFERRING VET

Dr. Titcher

INVOICE

26364

DATE

10.19.2021