



**PATIENT PRESENTING CLINICAL SIGNS**

Jules Kong 1 year recheck abdominal ultrasound from July 22, 2020 as will be having an extensive dental next week.

**SPECIES ULTRASONOGRAPHIC EXAMINATION OF THE ABDOMEN**

Canine **Urinary System**

**BREED**

Golden X

The urinary bladder, trigone, cystourethral junction, and visible pelvic urethra to a depth of 4.0 cm exhibited normal thickness and tone. Anechoic urine was present in the lumen with no uroliths or sediment. The ureteral papillae were normal. The ureters were not visible which is normal. No evidence of inflammatory or neoplastic changes were noted.

**SEX**

Spayed Female

Normal size and margination were present in the kidneys. A normal 1:3 cortex / medulla ratio was maintained. The medulla and cortices were uniform in texture with some increased echogenicity and mild loss of corticomedullary symmetry and definition expected for the age of the patient. No evidence of pelvic dilation was present. The left kidney measured 6.3 cm. The right kidney measured

**AGE**

12 Years

The area of the aortic trifurcation was free of pathology.

**Adrenal Glands**

**WEIGHT**

39.6 Pounds

The right adrenal gland was normal in size. Mild parenchyma heterogeneity and mild capsule asymmetry was present without suspicion for overt neoplasia. The left adrenal gland measured 1.7 cm length x 0.70 cm at the caudal pole. The right adrenal gland was indistinctly visualized owing to patient size and conformation without overt pathology, subjectively measuring 2.5 cm length x 0.79 cm at the caudal pole.

**Spleen**

**INTERPRETED BY**

R. McKenzie Daniel, DVM,  
DABVP (Canine and  
Feline)

A mildly expansive, non-homogeneous mass was noted subjectively in the cranial spleen, exhibiting similar echogenicity compared to adjacent normal appearing splenic parenchyma. The mass measured approximately 5.0 cm in diameter. The subjective mid to caudal spleen exhibiting normal size and symmetrical capsule contour. No evidence of perisplenic omental reactivity, adhesions, or effusion.

**IMAGING PERFORMED BY**

Crystal Hill

**Liver**

**HOSPITAL NAME**

The Maples AH

The liver was subjectively normal in size, structure, and contour. The liver parenchyma was mildly nonuniform and hypoechoic to the spleen with a moderate coarse echotexture and subjective mild to benign parenchymal remodeling. The hepatic and portal vasculature were normal in appearance without signs of congestion. The gallbladder was non-distended in size with thin walls and primarily anechoic luminal content. The cystic and common bile ducts were normal.

**REFERRING VET**

Dr. Kazienko

**Gastrointestinal**

**INVOICE**

26359

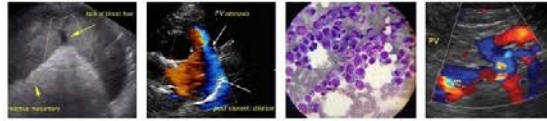
The stomach presented intact wall layering with a normal wall layer ratio. The lumen of the stomach was empty with no signs of ileus, obstruction or foreign material.

The small intestine presented intact wall layering with 1:3 muscularis/mucosa ratio. The lumen of the small intestine was empty with no signs of ileus, obstruction or foreign material.

Normal visible colon wall layers were present with apparent formed feces in lumen.

**DATE**

10/19/21



**PATIENT** *Pancreas*

Jules Kong The parenchyma of the left limb, body and right limb of the pancreas presented isoechoic to the adjacent omental fat. A normal curvilinear capsule contour of the pancreas was present. The visible pancreatic duct was normal. No signs of active inflammation or neoplastic disease was evident.

**SPECIES** *Free Abdomen*

Canine No overt lymphadenopathy or peritoneal effusion was present.

**BREED** *Free Abdomen*

Golden X Rapid view of the heart revealed no evidence of pericardial masses or effusion in the visible window.

**SEX**

Spayed Female

- Non-homogeneous cranial splenic mass
- Mild hepatic parenchymal remodeling – subjectively benign.
- Mild age related renal changes

**AGE**

12 Years

**WEIGHT**

39.6 Pounds

**ULTRASONOGRAPHIC FINDINGS**

**INTERPRETATION OF THE FINDINGS & FURTHER RECOMMENDATIONS**

The cranial splenic mass may represent progression of previously noted splenic nodule, although separate etiology may also be possible. The splenic mass is nonspecific with considerations including hyperplasia, hematopoiesis, granuloma, splenitis, or neoplasia (sarcoma, round cell neoplasia, other). No overt evidence of intraabdominal or major organ metastasis, and no evidence of regional omental seeding or secondary rupture. 3-view chest radiographs are recommended. Given the lack of evidence of pericardial or intraabdominal metastasis and assuming no evidence of pathology on 3-view chest radiographs, splenectomy should be considered.

**INTERPRETED BY**

R. McKenzie Daniel, DVM,  
DABVP (Canine and  
Feline)

**IMAGING PERFORMED BY**

Crystal Hill

**HOSPITAL NAME**

The Maples AH

**REFERRING VET**

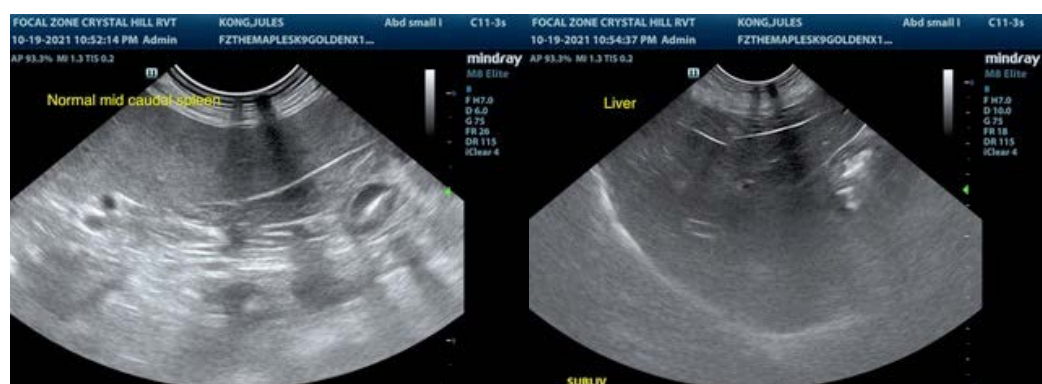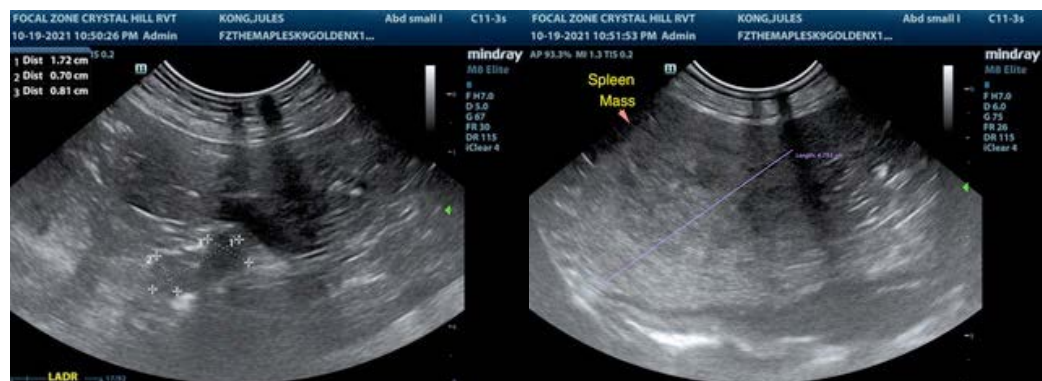
Dr. Kazienko

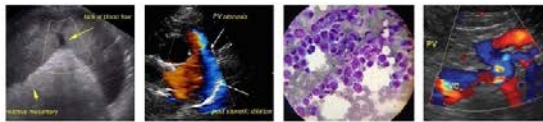
**INVOICE**

26359

**DATE**

10/19/21





**PATIENT**

Jules Kong

**SPECIES**

Canine

**BREED**

Golden X

**SEX**

Spayed Female

**AGE**

12 Years

**WEIGHT**

39.6 Pounds

**INTERPRETED BY**

R. McKenzie Daniel, DVM,  
DABVP (Canine and  
Feline)

**IMAGING  
PERFORMED BY**

Crystal Hill

**HOSPITAL NAME**

The Maples AH

**REFERRING VET**

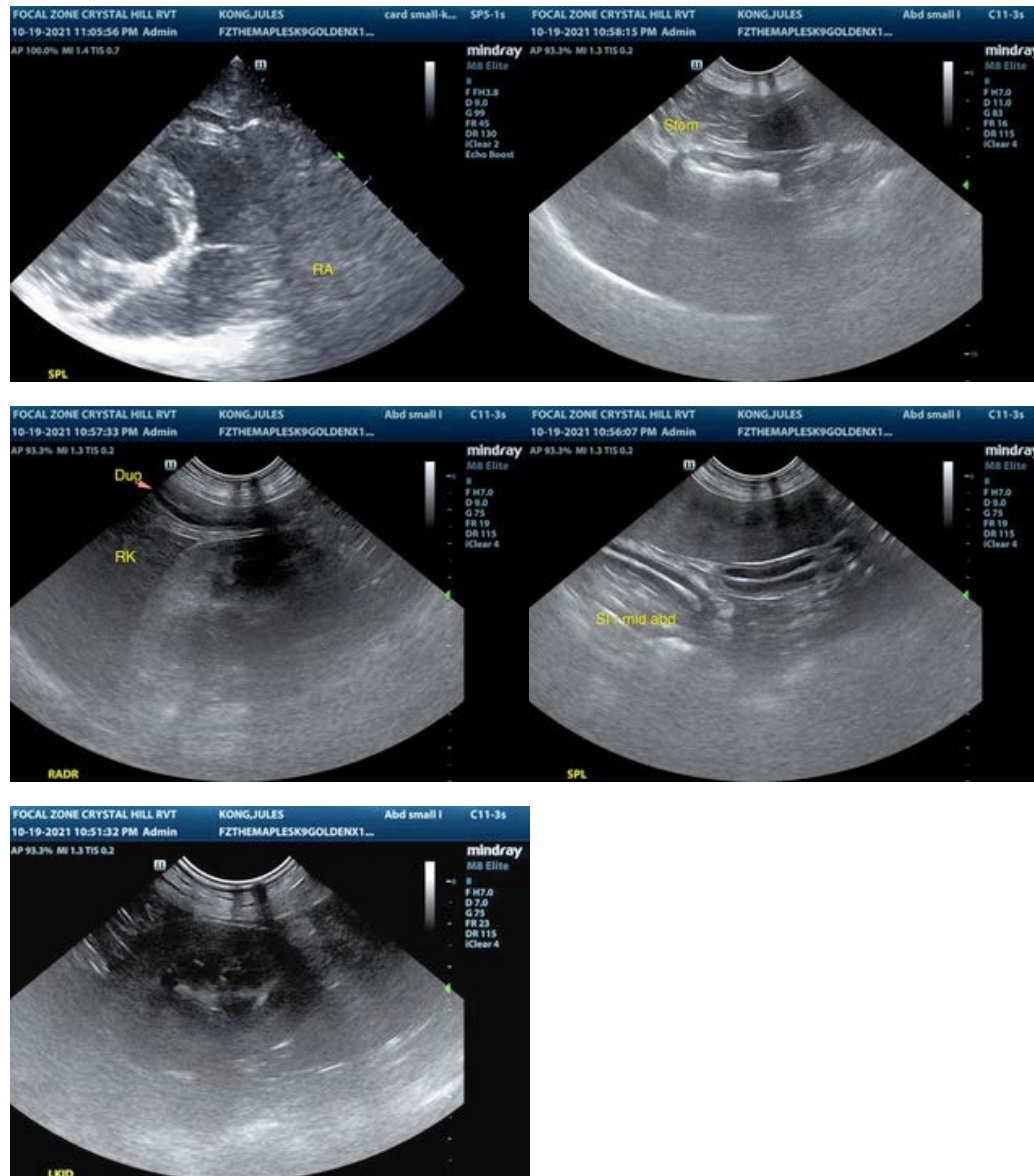
Dr. Kazienko

**INVOICE**

26359

**DATE**

10/19/21



The information and recommendations provided are based on the images presented by the referring veterinarian. No evaluation can be communicated regarding pathology that was not visible in the image/video clips provided.

Thank you for this referral. If the clinical or image interpretation does not parallel your findings or if I can be of any further assistance please contact me.

R. McKenzie Daniel, DVM, DABVP (Canine / Feline Practice)  
info@SonoPath.com