



PATIENT

Mica Brink

SPECIES

Canine

BREED

Golden Retriever

SEX

Spayed Female

AGE

9 Years

WEIGHT

89 Pounds

INTERPRETED BY

R. McKenzie Daniel,
DVM, DABVP
(Canine and Feline)

**IMAGING
PERFORMED BY**

Rachel Runnells, RVT

HOSPITAL NAME

SVS Imaging KC

REFERRING VET

Dr. Sarah Meineka

INVOICE

17834

DATE

10/18/22

PRESENTING CLINICAL SIGNS

History: Presented 10-13-22 for lethargy, inappetence, vomited once, breathing abnormally. Radiographs were non-diagnostic. Bloodwork largely within normal limits, lipase slightly elevated. Add on spec cPL at IDEXX elevated at 491 (normal range 0-200). Treated over the weekend October 14-16 with anti-emetics, sucralfate, omeprazole, IV fluid support, began eating Oct 16 and strong, sent home. Oct 17th ate but then vomited 3 times, acting more lethargic.

Abnormal PE/Chem/CBC/UA Results: Only chemistry abnormality is lipase 363 (normal range 0-250), spec cPL elevated at 491 (normal range 0-200). CBC prior to hospitalization: RBC 9.13 (range 5.39 - 8.70), Hematocrit 64.6 (range 38.3 - 56.5), Hemoglobin 22.3 (range 13.4 - 20.7). Urinalysis was largely WNL aside from color which was red/brown but clear.

ULTRASONOGRAPHIC EXAMINATION OF THE ABDOMEN

Urinary System

The urinary bladder, trigone, cystourethral junction, and visible pelvic urethra to a depth of 3.0 cm exhibited normal thickness and tone. Anechoic urine was present in the lumen with no uroliths or sediment. The ureteral papillae were normal. The ureters were not visible which is normal. No evidence of inflammatory or neoplastic changes were noted. Aortic trifurcation was normal.

Normal size and margination were present in the kidneys. A normal 1:3 cortex / medulla ratio with minor loss of corticomedullary border demarcation was noted. The echogenicity of the cortex was similar to or slightly less than normal liver parenchyma while the medulla echogenicity was hypoechoic to the cortex with no evidence of pelvic dilation. The left kidney measured 7.3 cm in length. The right kidney measured 7.5 cm in length.

Adrenal Glands

The left adrenal gland was uniform in size and contour with a uniformly hypoechoic parenchyma. The left adrenal gland measured 0.62 cm width at the cranial pole and 0.72 cm width at the caudal pole.

The right adrenal gland was uniform in size and contour with a uniformly hypoechoic parenchyma. The right adrenal gland measured 0.84 cm width at the caudal pole and 0.54 cm width at the cranial pole.

Spleen

The spleen was overall normal in size and contour with primarily maintained finely textured homogenous parenchyma. Potential for medial abdominal location of the spleen which is likely a patient variant. A solitary discreet hyperechoic nondisruptive nodule in the cranial spleen was noted, measuring 1.5 cm in diameter, consistent with benign myelolipoma. No evidence of splenic masses or neoplastic criteria.

Liver

The liver was subjectively normal in size, structure, and contour. The liver parenchyma was uniform and hypoechoic to the spleen with a mild coarse echotexture. The hepatic and portal vasculature were normal in appearance without signs of congestion. The gallbladder was non-distended in size with thin walls and primarily anechoic luminal content. The cystic and common bile ducts were normal.

Gastrointestinal



PATIENT

Mica Brink

The stomach presented wall thickening secondary to echogenic mucosa hypertrophy. Mildly prominent wall layering was noted owing to mildly prominent gastric mucosa. Mild gastric distension with mild retained anechoic fluid was present without evidence of retained ingesta or gastric foreign material, as well as no evidence of mechanical pyloric outflow obstruction.

SPECIES

Canine

The small intestine exhibited intact wall layering with primarily maintained 1:3 muscularis/mucosa ratio with subjective propensity for mildly prominent mid to upper duodenal walls, as well as potential mild concurrent upper duodenal stasis. No evidence of small intestinal mechanical obstructive pattern or foreign material, as well as no evidence of small intestinal wall layering or intestinal masses.

BREED

Golden Retriever

Normal visible colon wall layers were present with apparent formed feces in lumen.

SEX

Spayed Female

Pancreas

The pancreas was mildly prominent in size with areas of mild capsule asymmetry. Mild hypoechoic to non-homogenous parenchyma compared to adjacent omentum.

AGE

9 Years

Free Abdomen

No overt lymphadenopathy or peritoneal effusion was present.

ULTRASONOGRAPHIC FINDINGS

WEIGHT

89 Pounds

Primary Findings

- Mild gastritis/gastroduodenitis pattern with mild gastric and upper duodenal hypomotility
- Heterogenous mildly hypoechoic to prominent pancreas- suggestive of chronic active pancreatitis

INTERPRETED BY

R. McKenzie Daniel,
DVM, DABVP
(Canine and Feline)

Secondary Findings

- Minor age-related renal changes
- Benign splenic nodule – consistent with myelolipoma

IMAGING PERFORMED BY

Rachel Runnells, RVT

INTERPRETATION OF THE FINDINGS & FURTHER RECOMMENDATIONS

HOSPITAL NAME

SVS Imaging KC

No evidence of intraabdominal, specifically gastrointestinal or pancreatic neoplastic criteria. Empirical therapy for gastroduodenitis and chronic active pancreatitis is warranted. Recheck sonogram is suggested for reassessment of the stomach, duodenum and pancreas if recurrent or persistent gastrointestinal signs or evidence of persistent pancreatitis. Resting cortisol level could be considered to screen for occult Addisons disease, although the bilateral adrenal glands appear to be normal.

REFERRING VET

Dr. Sarah Meineka

INVOICE

17834

DATE

10/18/22



PATIENT

Mica Brink

SPECIES

Canine

BREED

Golden Retriever

SEX

Spayed Female

AGE

9 Years

WEIGHT

89 Pounds

INTERPRETED BY

R. McKenzie Daniel,
DVM, DABVP
(Canine and Feline)

IMAGING PERFORMED BY

Rachel Runnells, RVT

HOSPITAL NAME

SVS Imaging KC

REFERRING VET

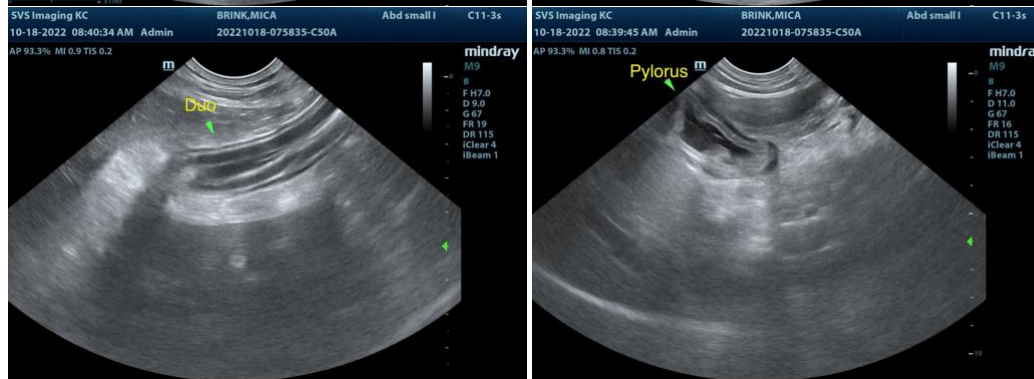
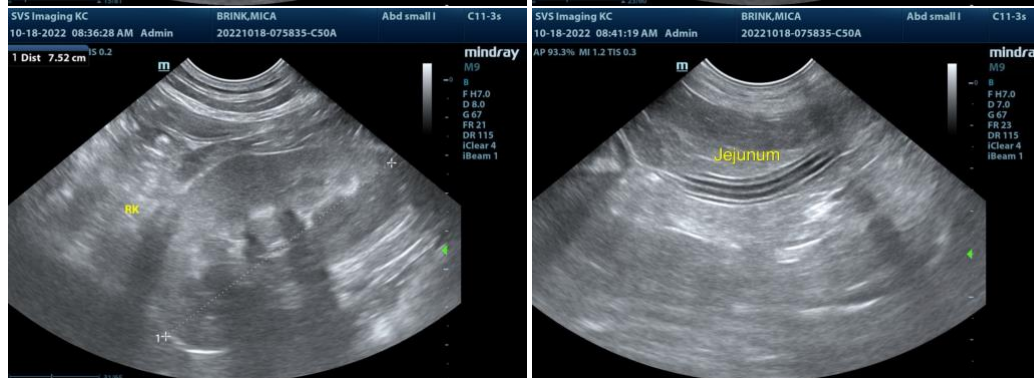
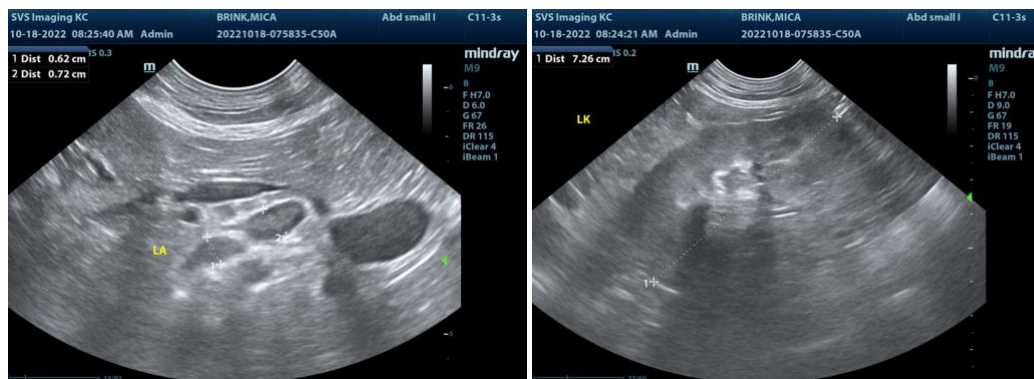
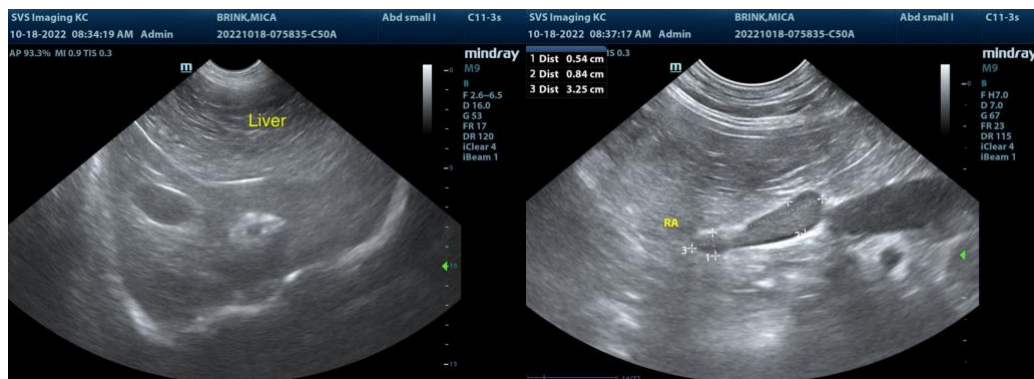
Dr. Sarah Meineka

INVOICE

17834

DATE

10/18/22





PATIENT

Mica Brink

SPECIES

Canine

BREED

Golden Retriever

SEX

Spayed Female

AGE

9 Years

WEIGHT

89 Pounds

INTERPRETED BY

R. McKenzie Daniel,
DVM, DABVP
(Canine and Feline)

IMAGING PERFORMED BY

Rachel Runnells, RVT

HOSPITAL NAME

SVS Imaging KC

REFERRING VET

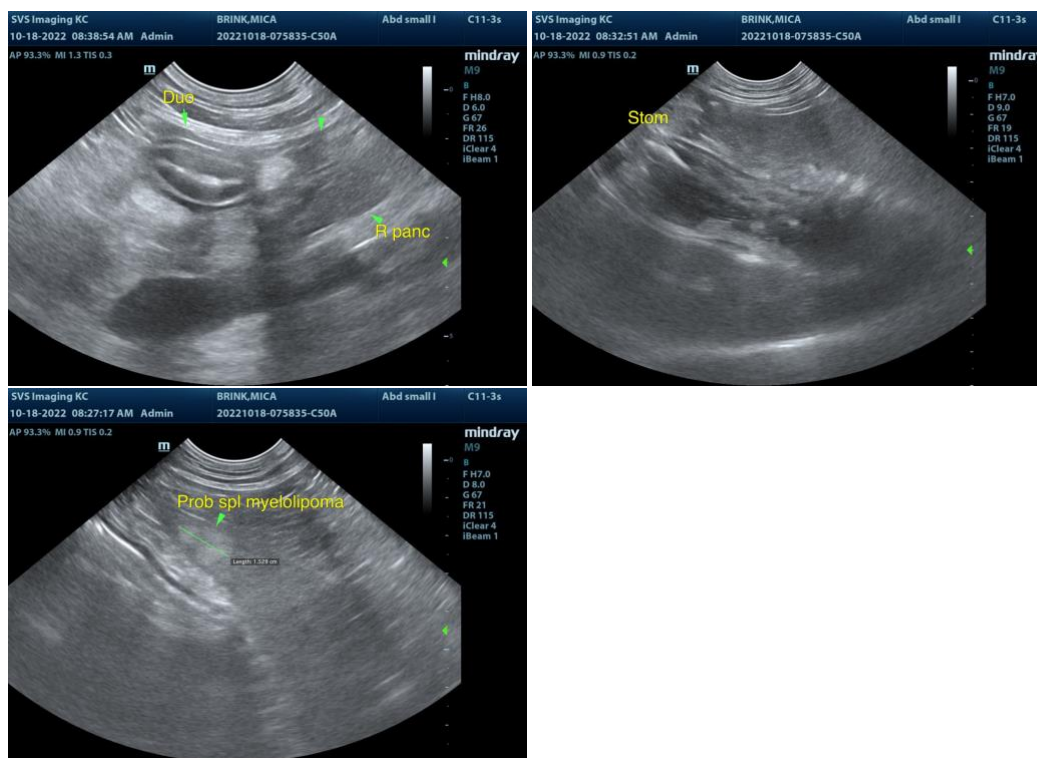
Dr. Sarah Meineka

INVOICE

17834

DATE

10/18/22



The information and recommendations provided are based on the images presented by the referring veterinarian. No evaluation can be communicated regarding pathology that was not visible in the image/video clips provided.

Thank you for this referral. If the clinical or image interpretation does not parallel your findings or if I can be of any further assistance please contact me.

R. McKenzie Daniel, DVM, DABVP (Canine / Feline Practice)
info@SonoPath.com