



PATIENT

Rocket Olson

SPECIES

Canine

BREED

Collie

SEX

Spayed Female

AGE

1 years

WEIGHT

38 lbs.

INTERPRETED BY

R. McKenzie Daniel,
DVM, DABVP
(Canine and Feline)

IMAGING PERFORMED BY

Dr. Gromalak

HOSPITAL NAME

SVS Imaging

REFERRING VET

Dr. Khatter

INVOICE

12366

DATE

10/18/21

PRESENTING CLINICAL SIGNS

History of murmur as a puppy, recently having coughing episodes that has not responded to doxycycline. currently on baytril

ULTRASONOGRAPHIC EXAMINATION OF THE HEART

CANINE CARDIAC PARAMETERS	MR VMAX (m/s)	TR VMAX (m/s)	LA/AO (Boon method)	LA/AO (Heart Base; Swe)	FS (%)	EF (%)	EPSS (cm)
NORMAL PARAMETER	4.5-5.5	<2.7	1.3	<1.6	28-40	40-100	<0.6
PATIENT		>1.0 m/s	NM	1.35	33.3	65.6	0.28
CANINE CARDIAC PARAMETERS	HR (BPM)	AV VMAX (m/s)	PV MAX (m/s)	BODY WEIGHT (kg)	LA 2D short axis Base view (cm)	LVIDd Avg; 2D and m-mode short axis (cm)	LVIDs Avg; 2D and m-mode short axis (cm)
NORMAL PARAMETER	50-100	0.7-1.7	0.7-1.6	BELOW	BELOW	BELOW	BELOW
PATIENT	180	1.5	0.8		2.6	3.0	

Cardiac Presentation

The echocardiogram in this patient demonstrated normal **left atrial** size based on 3 separate methods of LA evaluation. The cranial and caudal **mitral** valve leaflets presented normal linear structure, extension in systole, and union in diastole with normal kinesis. The **left ventricle** presented thicknesses with linear contour and was not dilated nor restricted. The **myocardium** presented normal echogenicity without subjective evidence of significant fibrotic or ischemic disease. **Contractility** of the ventricular walls was adequate and in normal range for this patient evidenced by the fractional shortening measurement and subjective evaluation of the different regions of the myocardium. The **left ventricular outflow** tract demonstrated normal laminar flow and subjective structural integrity. The **right atrium** and auricle revealed normal size, structure and content. No evidence of masses was noted. **Tricuspid** valvular assessment demonstrated adequate linear morphology and kinesis. The **right ventricle** was of normal size (1/3 diameter of LV), chordae structure, myocardial echogenicity and thickness. **Pulmonary outflow** tract assessment revealed normal valve structure, laminar flow, and diameter (approx. 1:1 pa/ao ratio). No visible **pericardial** or free pleura fluid was noted. The cranial **mediastinum and pericardial and extra-cardiac regions** were free of masses in the visible window.

ULTRASONOGRAPHIC FINDINGS

Primary Findings

- Overtly normal cardiac structure and function



PATIENT

Rocket Olson

SPECIES

Canine

BREED

Collie

SEX

Spayed Female

AGE

1 years

WEIGHT

38 lbs.

INTERPRETED BY

R. McKenzie Daniel,
DVM, DABVP
(Canine and Feline)

IMAGING PERFORMED BY

Dr. Gromalak

HOSPITAL NAME

SVS Imaging

REFERRING VET

Dr. Khatter

INVOICE

12366

DATE

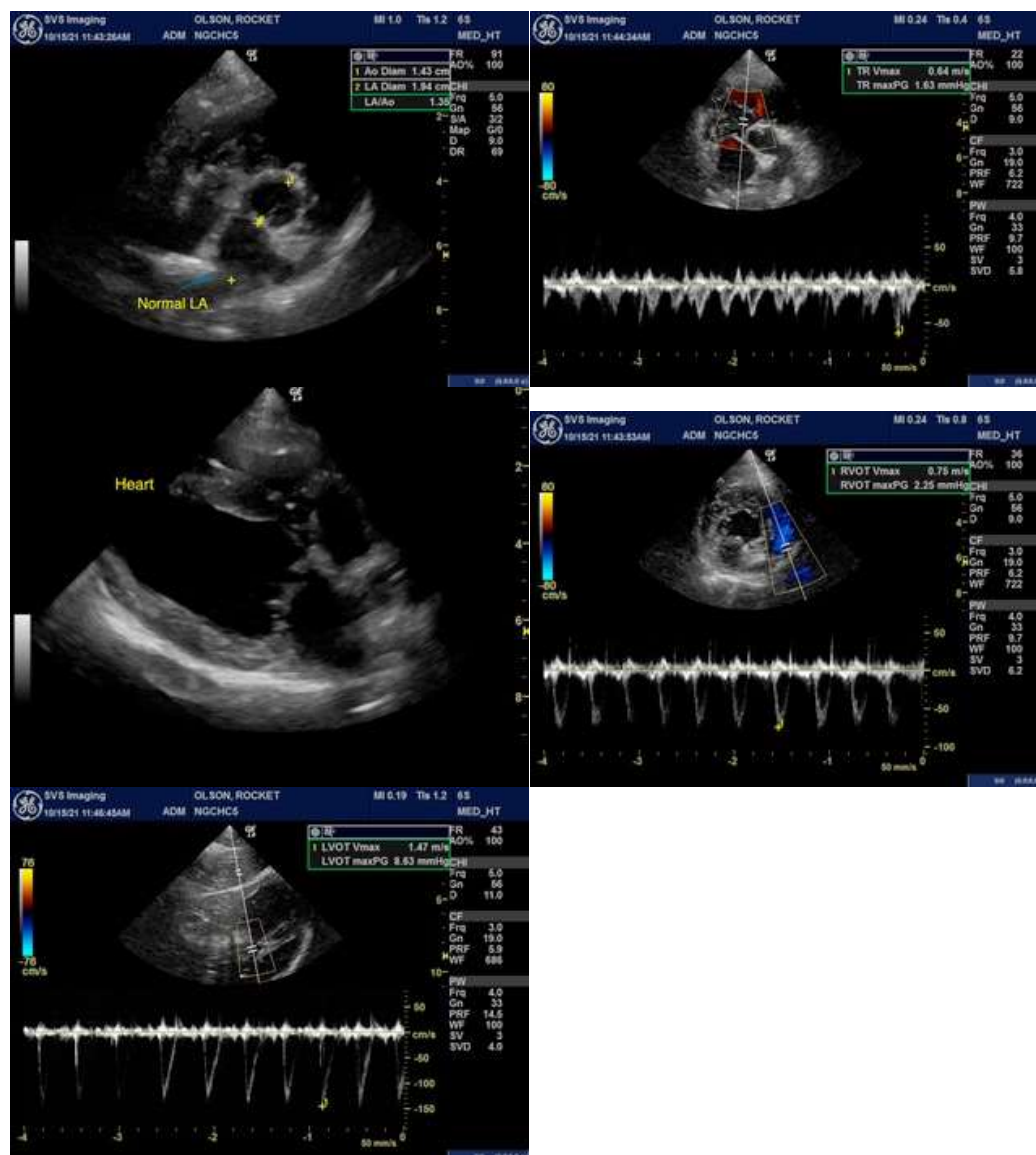
10/18/21

INTERPRETATION OF THE FINDINGS & FURTHER RECOMMENDATIONS

No evidence of structural or functional cardiomyopathy was present in this study. No evidence of valvular insufficiencies, shunt (no evidence of left heart volume overload), systolic dysfunction, or clinical pulmonary hypertension was noted.

Given the cardiac presentation, the coughing in this patient is certainly noncardiogenic in origin. Consideration for primary lower airway disease may be indicated. No Indication for cardiac medications. No overt anesthetic contraindications.

If the murmur is still present, the potential for physiologic or flow murmur possibly present at elevated heart rate or small flow abnormality not noted in this study, assuming normal hydration and no evidence of anemia, may be possible.





PATIENT

Rocket Olson

SPECIES

Canine

BREED

Collie

SEX

Spayed Female

AGE

1 years

WEIGHT

38 lbs.

INTERPRETED BY

R. McKenzie Daniel,
DVM, DABVP
(Canine and Feline)

**IMAGING
PERFORMED BY**

Dr. Gromalak

HOSPITAL NAME

SVS Imaging

REFERRING VET

Dr. Khatter

INVOICE

12366

DATE

10/18/21

The information and recommendations provided are based on the images presented by the referring veterinarian. No evaluation can be communicated regarding pathology that was not visible in the image/video clips provided.

Thank you for this referral. If the clinical or image interpretation does not parallel your findings or if I can be of any further assistance please contact me.

R. McKenzie Daniel, DVM, DABVP (Canine / Feline Practice)
info@SonoPath.com