

**PATIENT PRESENTING CLINICAL SIGNS**

Phil DeAngelis At present time, no clinical signs. Initially dog was seen for chronic diarrhea, which has resolved with diet change and probiotics. TP and Albumin have been consistently decreased and there is protein in urine. Sedated with dexdomitor for study.

**SPECIES** Abnormal PE/Chem/CBC/UA Results: TP 4.9; Albumin 2; Urine protein 3+ with no signs of UTI

Canine

**ULTRASONOGRAPHIC EXAMINATION OF THE ABDOMEN**

**BREED** *Urinary System*

Shepherd X The urinary bladder, trigone, cystourethral junction, and visible pelvic urethra to a depth of 2.0 cm exhibited normal thickness and tone. Anechoic urine was present in the lumen with no uroliths or sediment. The ureteral papillae were normal. The ureters were not visible which is normal. No evidence of inflammatory or neoplastic changes were noted.

**SEX**

Neutered Male The residual prostate was symmetrically normal in size with uniform parenchyma and slight coarse echotexture. The prostate measured 0.97 cm in width.

**AGE**

9 Years Normal size and margination was present in the kidneys. Subjectively normal corticomedullary border echogenicity with mild loss of corticomedullary border distinction. No evidence of pyelectasia. The left kidney measured 6.4 cm. The right kidney measured 5.7 cm.

The area of the aortic trifurcation was free of pathology.

**WEIGHT**

52.9 Pounds

**Adrenal Glands**

The adrenal glands were uniform in size and contour with a uniformly hypoechoic parenchyma. The left adrenal gland measured 0.48 cm at the cranial pole and 0.66 cm at the caudal pole. The right adrenal gland measured 1.0 cm at the cranial pole and 0.68 cm at the caudal pole.

**INTERPRETED BY**

R. McKenzie Daniel, DVM, DABVP (Canine and Feline)

**Spleen**

The spleen exhibited a finely textured and homogenous parenchyma which was hyperechoic to the liver and renal cortical parenchyma. The capsule was smooth and regular without apparent expansion. The splenic vasculature at the hilus was normal in volume with no evidence of congestion or thrombosis. Acute to chronic inflammatory, neoplastic, or benign parenchyma changes were not noted.

**IMAGING PERFORMED BY**

Pamela Harrigan, RDCS

**Liver**

**HOSPITAL NAME**

Chase Vet Clinic

The liver was subjectively normal in size, structure, and contour. The liver parenchyma was uniform and hypoechoic to the spleen with a mild coarse echotexture. The hepatic and portal vasculature were normal in appearance without signs of congestion. The gallbladder was non distended in size with mild, echogenic, nonmineralized biliary sludge. The cystic duct and common bile ducts were normal without evidence of dilation.

**REFERRING VET**

Dr. Catherine Caffarella

**Gastrointestinal**

The stomach presented intact wall layering with a normal wall layer ratio. The lumen of the stomach was empty with no signs of ileus, obstruction or foreign material. Pylorus wall measured 0.37 cm.

**INVOICE**

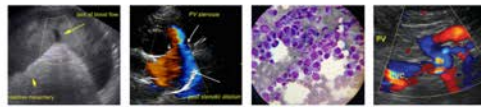
26326

The small intestine presented intact wall layering with 1:3 muscularis/mucosa ratio. The lumen of the small intestine was empty with no signs of ileus, obstruction or foreign material. Duodenum wall measured 0.51 cm. Jejunum wall measured 0.41 cm.

**DATE**

10/15/21

Normal visible colon wall layers were present with apparent formed feces in lumen.



**PATIENT** *Pancreas*

Phil DeAngelis

The pancreas was normal in size and contour with isoechoic to heterogeneous parenchyma compared to adjacent omentum. No signs of active inflammation or neoplasia.

**SPECIES**

Canine

**Free Abdomen**

Intermittent, mildly prominent to enlarged mesenteric nodes were present. Example measured 1.7 cm x 0.66 cm. The lymph nodes were essentially isoechoic to adjacent omentum without evidence of peripheral inflammation and maintaining a normal width: length ratio (<0.5).

**BREED**

Shepherd X

No effusion.

**SEX**

**ULTRASONOGRAPHIC FINDINGS**

Neutered Male

- Normal renal size and magination with mild loss of corticomedullary border distinction
- Mild gallbladder debris (non-mucocele)
- Sonographically unremarkable gastrointestinal tract and colon
- Intermittent, subjectively benign/reactive mesenteric lymph nodes

**AGE**

9 Years

**INTERPRETATION OF THE FINDINGS & FURTHER RECOMMENDATIONS**

**WEIGHT**

52.9 Pounds

UPC recommended on sterile urine sample for further assessment of the proteinuria. Potential for ACE inhibitor medication may be indicated if persistent proteinuria or UPC level >2.0. The response of the diarrhea to diet change and probiotics may suggest previous alteration in gastrointestinal flora, potentially associated with the breed, although the possibility of underlying inflammatory enterocolonopathy possible. Long-term diet and probiotics likely indicated. Further workup for PLN may be considered if documented persistent proteinuria and elevated UPC given the quiet urinary bladder sediment.

**INTERPRETED BY**

R. McKenzie Daniel, DVM,  
 DABVP (Canine and Feline)

**IMAGING PERFORMED BY**

Pamela Harrigan, RDCS

**HOSPITAL NAME**

Chase Vet Clinic

**REFERRING VET**

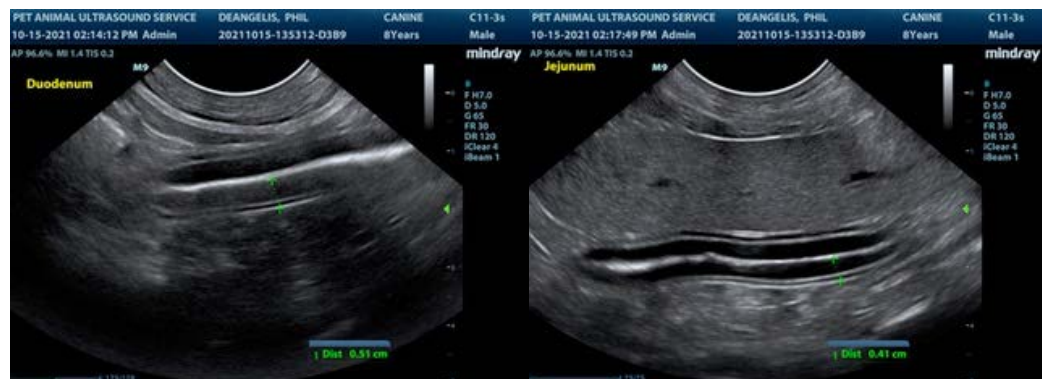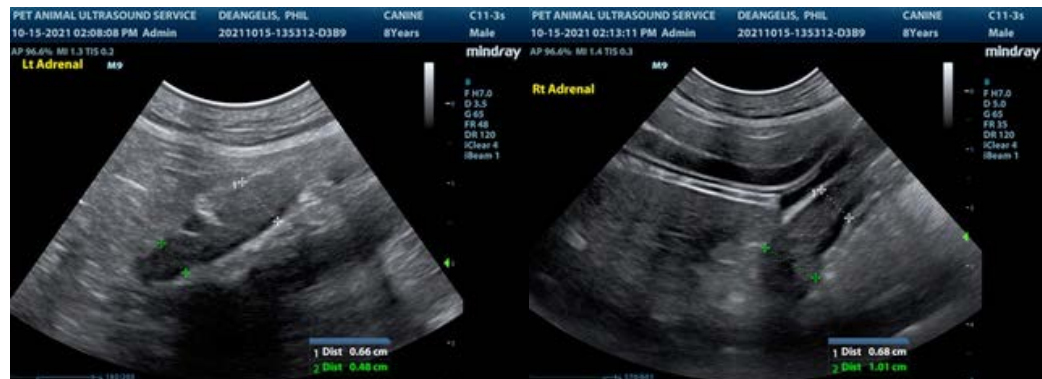Dr. Catherine  
 Caffarella

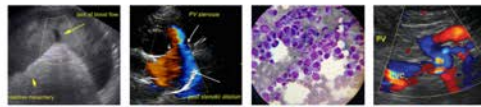
**INVOICE**

26326

**DATE**

10/15/21





**PATIENT**

Phil DeAngelis

**SPECIES**

Canine

**BREED**

Shepherd X

**SEX**

Neutered Male

**AGE**

9 Years

**WEIGHT**

52.9 Pounds

**INTERPRETED BY**

R. McKenzie Daniel, DVM,  
 DABVP (Canine and Feline)

**IMAGING PERFORMED BY**

Pamela Harrigan, RDCS

**HOSPITAL NAME**

Chase Vet Clinic

**REFERRING VET**

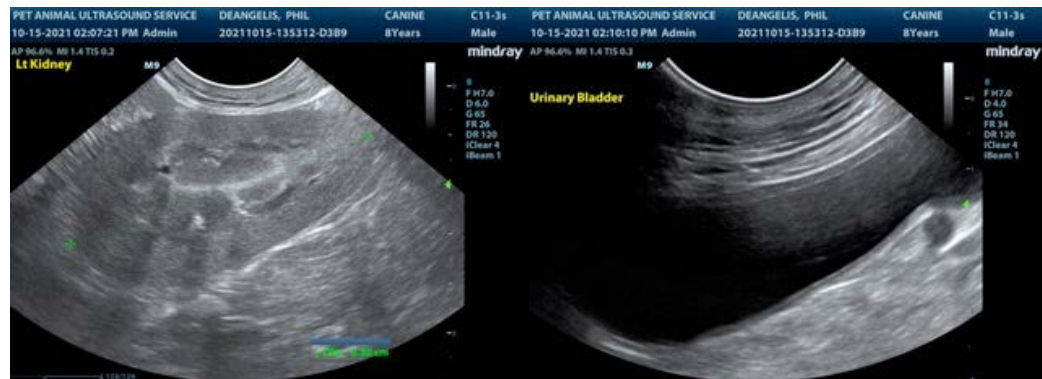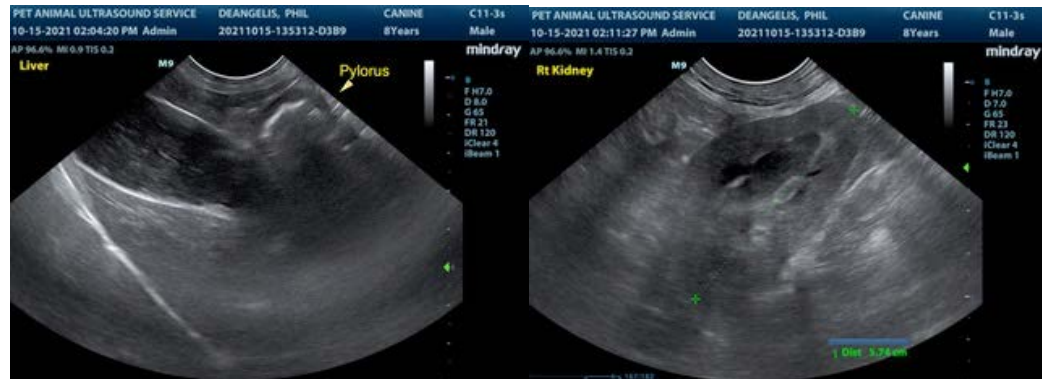
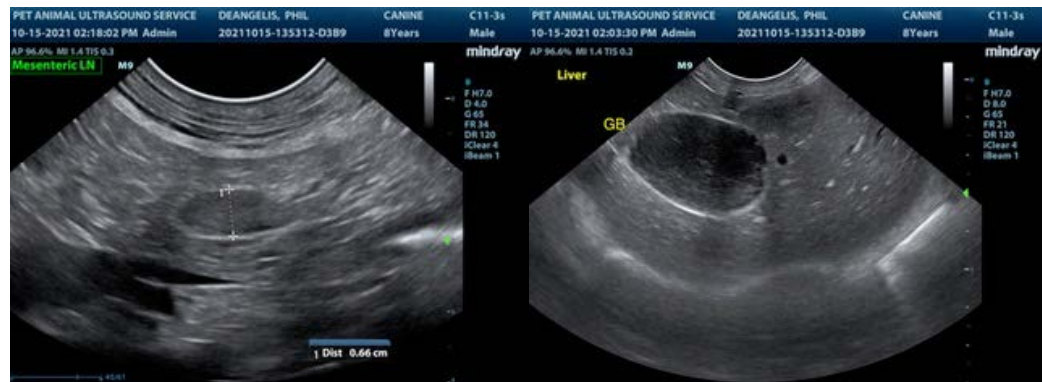Dr. Catherine Caffarella

**INVOICE**

26326

**DATE**

10/15/21



The information and recommendations provided are based on the images presented by the referring veterinarian. No evaluation can be communicated regarding pathology that was not visible in the image/video clips provided.

Thank you for this referral. If the clinical or image interpretation does not parallel your findings or if I can be of any further assistance please contact me.

R. McKenzie Daniel, DVM, DABVP (Canine / Feline Practice)  
 info@SonoPath.com