


PATIENT

Toby O'Malley

PRESENTING CLINICAL SIGNS

Hx intermittent murmur, ^ cardio pet BNP (128) No current meds.

SPECIES

Feline

Abnormal PE/Chem/CBC/UA Results: Creat 2.0, BUN 40 in 7/2022 UA: 2+ protein SG: 1.035

BREED

DSH

ULTRASONOGRAPHIC EXAMINATION OF THE HEART
SEX

MN

AGE

11yr

WEIGHT

NA

FELINE CARDIAC PARAMETERS	BODY WEIGHT (kg)	HR (BPM)	IVSd (cm)	LVIDd (cm)	LVWd (cm)	FS (%)	EF (%)
NORMAL PARAMETER	-----	150-240	0.3-0.6	1.0-2.1	0.25-0.6	35-67	80-100
PATIENT		230	0.46	1.4	0.46	46.4	81.3
FELINE CARDIAC PARAMETERS	LA/AO (Boon)	LA/AO HEART BASE (Sisson)	LA 2D 4-chamber long axis AS to FW (Sisson) (cm)	LVOT VEL. (m/s)	RVOT VEL. (m/s)	IVRT (m/)	
NORMAL PARAMETER	<1.5	0.88-1.79	0.7-1.7	<1.6	<1.3	40-60	
PATIENT	1.3	1.3	1.2	1.0	1.3		
Adapted from June Boon, Veterinary Echocardiography, 1998 Sisson D et al. JVIM 1991; 5: 232, Jacobs et al. Am J Vet Res 1985; 46:1705							

INTERPRETED BY

 R. McKenzie Daniel,
 DVM, DABVP
 (Canine and Feline)

Cardiac Presentation

The echocardiogram in this patient demonstrated normal left atrial size based on 3 separate LA measurements. The cranial and caudal mitral valve leaflets presented normal linear structure and kinetics. No overt MR was noted. The left ventricle presented normal thicknesses with linear contour and was not dilated nor restricted. Normal measured LVOT velocity. The myocardium presented normal echogenicity without subjective evidence of significant fibrotic or ischemic disease. Contractility of the ventricular walls was adequate and in normal range for this patient evidenced by the fractional shortening measurement and subjective evaluation of the different regions and angles of the myocardium. The left ventricular outflow tract demonstrated normal laminar flow and subjective structural integrity. The right atrium and auricle revealed normal size, structure and content. No evidence of masses was noted or chamber overload. Tricuspid valvular assessment demonstrated adequate linear morphology and kinetics. The right ventricle was of normal size (1/3 diameter of LV), chordae structure, myocardial echogenicity and thickness. Pulmonic tract assessment revealed normal valve structure, laminar flow, and diameter (approx. 1:1 pa/ao ratio). Normal measured RVOT velocity. No visible pericardial or free pleura fluid was noted or extra cardiac pathology in the visible planes. The cranial mediastinum and pericardial regions were free of masses in the visible window.

IMAGING PERFORMED BY

Jessica Miller

HOSPITAL NAME

 Livingston Animal
 Hospital

REFERRING VET

Dr. Messina

ULTRASONOGRAPHIC FINDINGS

- Normal echocardiogram

INVOICE

11854ag

INTERPRETATION OF THE FINDINGS & FURTHER RECOMMENDATIONS

A definitive cause of the patient's murmur was not evident without evidence of structural or functional cardiomyopathy. No evidence of clinical issues such as HCM criteria, LV systolic dysfunction, clinical pulmonary hypertension or overt valvular insufficiencies was present. If no volume changes such as

DATE

10/14/2022



PATIENT

Toby O'Malley

dehydration or anemia, a benign physiologic flow murmur or small flow abnormality is suspected. Regardless, the lack of left or right heart chamber enlargement indicate that the hemodynamic effects of the murmur are low. No indication for cardiac medications. Continued monitoring of the murmur is recommended. Recheck echocardiogram recommended in 6-12 months, sooner if murmur intensity increases or clinical signs suggestive of heart disease arise.

SPECIES

Feline

BREED

DSH

SEX

MN

AGE

11yr

WEIGHT

NA

INTERPRETED BY

R. McKenzie Daniel,
DVM, DABVP
(Canine and Feline)

IMAGING PERFORMED BY

Jessica Miller

HOSPITAL NAME

Livingston Animal
Hospital

REFERRING VET

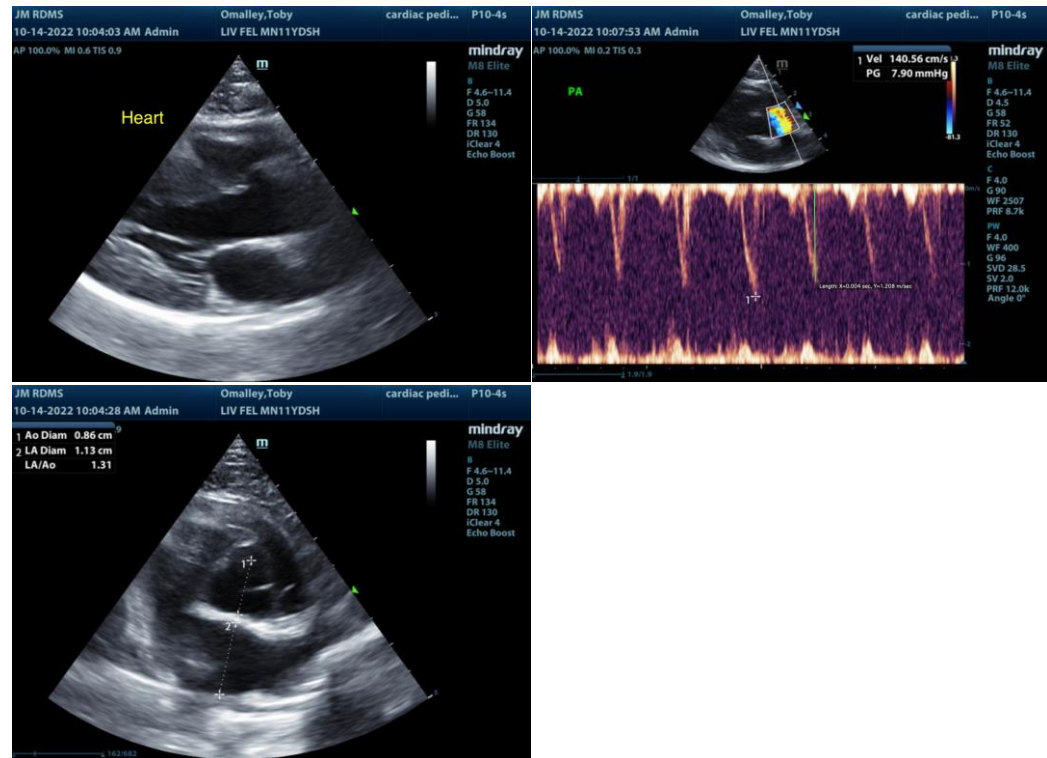
Dr. Messina

INVOICE

11854ag

DATE

10/14/2022



The information and recommendations provided are based on the images presented by the referring veterinarian/sonographer. No evaluation can be communicated regarding pathology that was not visible in the image/video clips provided.

Thank you for this referral. If the clinical or image interpretation does not parallel your findings or if I can be of any further assistance please contact me.

R. McKenzie Daniel, DVM, DABVP (Canine / Feline Practice)

info@SonoPath.com