



PATIENT PRESENTING CLINICAL SIGNS

Lily Deta On and off inappetance and diarrhea. Bloodwork all WNL. Fecals negative. History of calcium oxalate crystals. Is on urinary diet but not controlling crystal formation. Was on potassium citrate for crystal dissolution but dog did not tolerate it. Current medication: Famotidine 10 mg @1/2 PO BID. Fluoxetine 10 mg @1/2 PO SID. Metronidazole 62.5 mg 1PO BID. Probiotics once a day.

SPECIES

Canine

ULTRASONOGRAPHIC EXAMINATION OF THE ABDOMEN

BREED

Urinary System

Yorkshire Terrier

The urinary bladder, trigone, cystourethral junction, and visible pelvic urethra to a depth of 3 cm exhibited normal thickness and tone. Anechoic urine was present in the lumen with no uroliths or sediment. The ureteral papillae were normal. The ureters were not visible which is normal. No evidence of inflammatory or neoplastic changes were noted.

SEX

FS

Normal size and margination was present in the kidneys. A normal 1:3 cortex / medulla ratio was maintained. The medulla and cortices were uniform in texture with some increased echogenicity and moderate loss of corticomedullary symmetry and definition expected for the age of the patient. Mild medullary and pelvic mineralization and mild bilateral pyelectasia was present. The left kidney measured 3.6 cm in length. The right kidney measured 3.6 cm in length.

AGE

16yr

The area of the aortic trifurcation was free of pathology.

WEIGHT

7lb

Adrenal Glands

The bilateral adrenal glands were normal in size. Mild parenchyma heterogeneity and mild capsule asymmetry was present without suspicion for overt neoplasia. The left adrenal gland measured 0.45 cm width in the cranial pole and 0.50 cm width in the caudal pole. The right adrenal gland measured 0.27 cm width in the cranial pole and 0.34 cm width in the caudal pole.

INTERPRETED BY

R. McKenzie Daniel, DVM, DABVP (Canine and Feline)

Spleen

The spleen exhibited a finely textured and homogenous parenchyma which was hyperechoic to the liver and renal cortical parenchyma. The capsule was smooth and regular without apparent expansion. The splenic vasculature at the hilus was normal in volume with no evidence of congestion or thrombosis. Acute to chronic inflammatory, neoplastic, or benign parenchyma changes were not noted.

IMAGING PERFORMED BY

Pamela Harrigan, RDCS

Liver

The liver was subjectively normal in size, structure, and contour. The liver parenchyma was uniform and hypoechoic to the spleen with a mild coarse echotexture. The hepatic and portal vasculature were normal in appearance without signs of congestion. The gallbladder was non-distended in size with thin walls and primarily anechoic luminal content. The cystic and common bile ducts were normal.

HOSPITAL NAME

Chase Veterinary Clinic

REFERRING VET

Dr. Cafferella

Gastrointestinal

The stomach presented intact yet mildly prominent wall layering with a normal wall layer ratio. The lumen of the stomach was empty with no signs of ileus, obstruction or foreign material.

INVOICE

11877ag

The small intestine presented intact wall layering with mildly prominent duodenojejunal mucosa layer. Segments of the mid abdominal jejunum exhibited moderate mural hypertrophy with intact wall layering and altered muscularis/mucosa ratio as well as mucosal speckling. Associated mild jejunal corrugation was present. The lumen of the small intestine was empty with no signs of ileus, obstruction or foreign material. The jejunum wall measured up to 0.41 cm in width. The duodenum wall measured 0.43 cm in width.

DATE

10/14/2022



PATIENT Normal visible colon wall layers were present with apparent formed feces in lumen.

Lily Deta **Pancreas**

SPECIES The pancreas was normal in size and contour with isoechoic to heterogeneous parenchyma compared to adjacent omentum. No signs of active inflammation or neoplasia.

Canine **Free Abdomen**

Subjective mild peri intestinal hyperechoic mesentery was present. No overt free fluid.

BREED **ULTRASONOGRAPHIC FINDINGS**

Yorkshire Terrier

- Bilateral chronic moderate renal changes exhibiting minor medullary/pelvic mineral and minor pyelectasia
- Inflammatory gastroenteropathy pattern with segmentally thickened yet intact jejunum suspect IBD
- Mild heterogeneous pancreas

AGE **INTERPRETATION OF THE FINDINGS & FURTHER RECOMMENDATIONS**

16yr The pyelectasia may be owing to chronic renal changes, potential pelvic scarring possibly owing to previous calculi passage, IV fluid therapy (if applicable). Urine C/S and protein: creatinine ratio on sterile urine sample is recommended.

WEIGHT 7lb A GI panel to include PLI/TLI/Cobalamin/Folate is recommended. In addition to current GI support a hydrolyzed diet trial with potential long term dietary therapy and empirical therapy for IBD may prove beneficial. Empirical cobalamin supplementation pending GI panel results.

INTERPRETED BY

R. McKenzie Daniel, DVM,
 DABVP (Canine and Feline)

IMAGING PERFORMED BY

Pamela Harrigan, RDCS

HOSPITAL NAME

Chase Veterinary Clinic

REFERRING VET

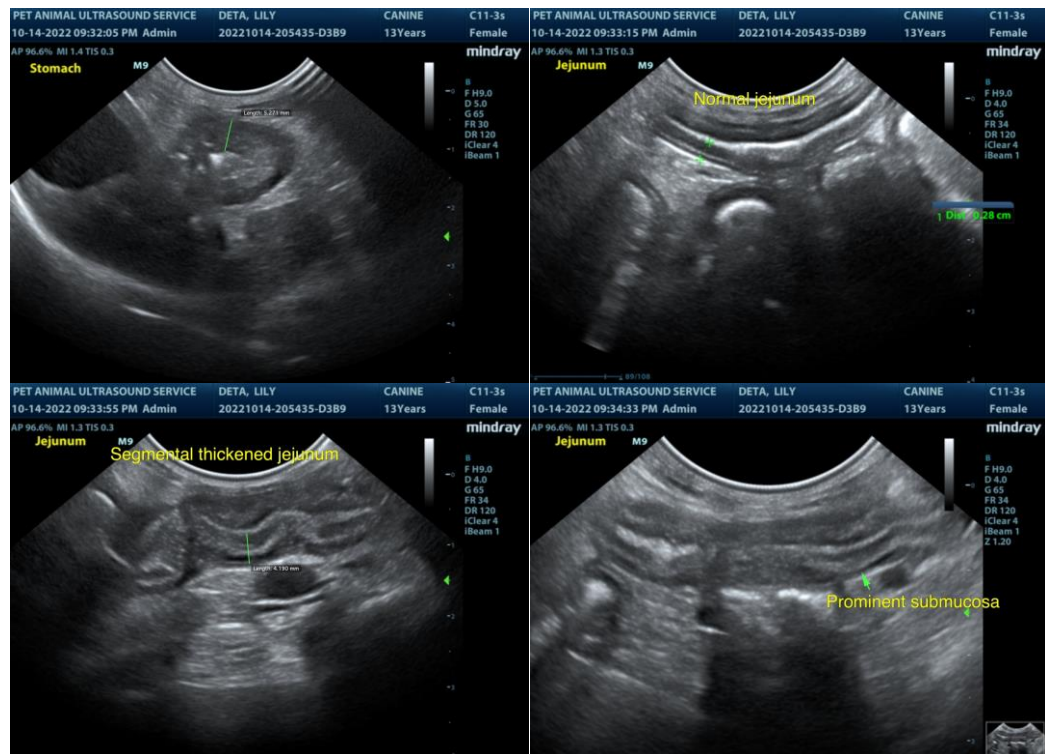
Dr. Cafferella

INVOICE

11877ag

DATE

10/14/2022





PATIENT

Lily Deta

SPECIES

Canine

BREED

Yorkshire Terrier

SEX

FS

AGE

16yr

WEIGHT

7lb

INTERPRETED BY

R. McKenzie Daniel, DVM,
 DABVP (Canine and Feline)

IMAGING PERFORMED BY

Pamela Harrigan, RDCS

HOSPITAL NAME

Chase Veterinary Clinic

REFERRING VET

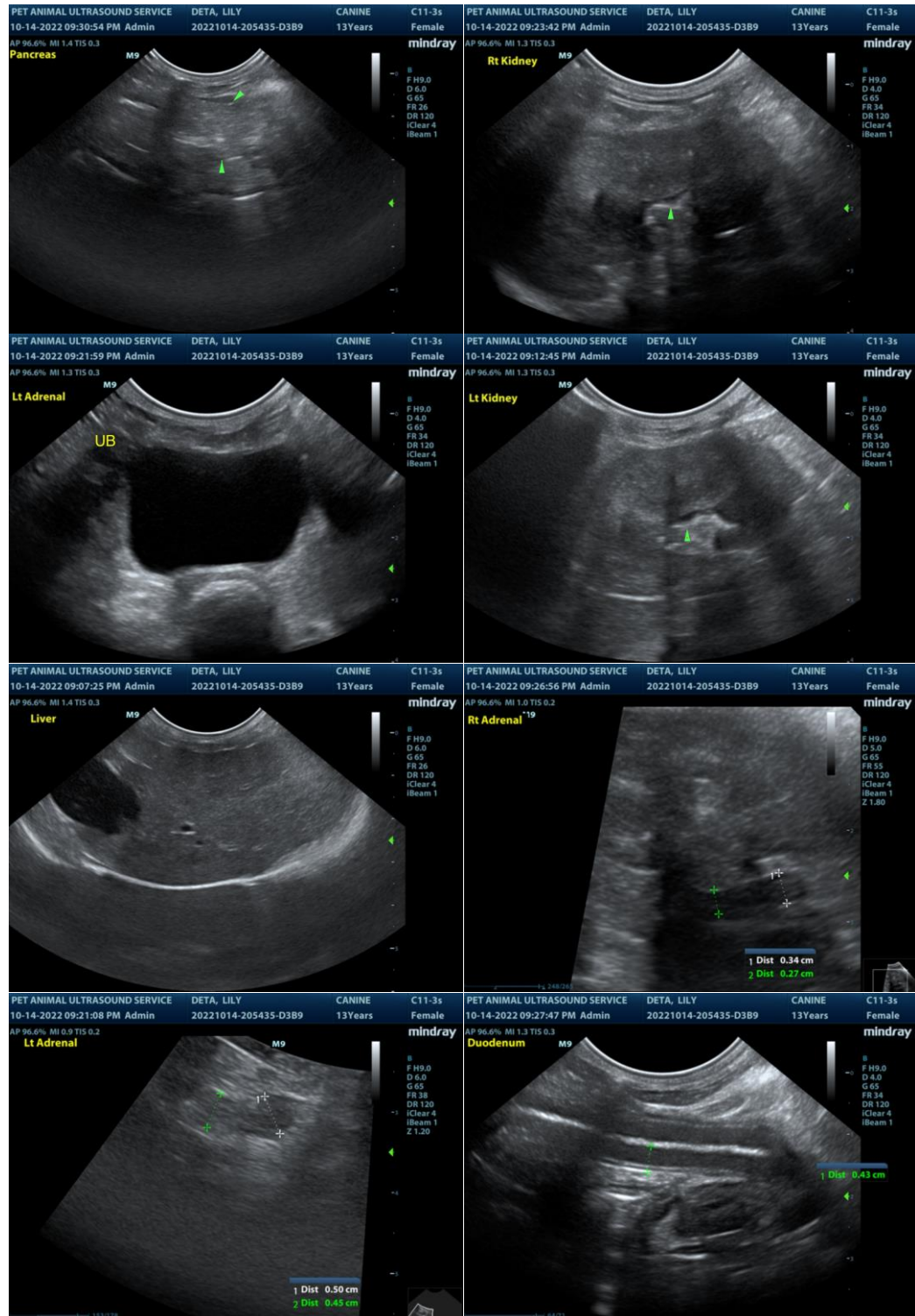
Dr. Cafferella

INVOICE

11877ag

DATE

10/14/2022



The information and recommendations provided are based on the images presented by the referring veterinarian. No evaluation can be communicated regarding pathology that was not visible in the image/video clips provided.

Thank you for this referral. If the clinical or image interpretation does not parallel your findings or if I



PATIENT can be of any further assistance please contact me.

Lily Deta

R. McKenzie Daniel, DVM, DABVP (Canine / Feline Practice)
info@SonoPath.com

SPECIES

Canine

BREED

Yorkshire Terrier

SEX

FS

AGE

16yr

WEIGHT

7lb

INTERPRETED BY

R. McKenzie Daniel, DVM,
DABVP (Canine and Feline)

IMAGING PERFORMED BY

Pamela Harrigan, RDMS

HOSPITAL NAME

Chase Veterinary Clinic

REFERRING VET

Dr. Cafferella

INVOICE

11877ag

DATE

10/14/2022