SonoPath
Clinical Sonography & Telecytology
EDUCATIONAL TELECONSULTATION SERVICES™
1-800-838-4268 info@sonopath.com SonoPath.com

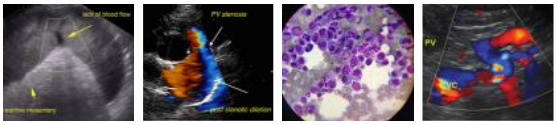

ANIMAL SOUNDS NW
MOBILE VETERINARY ULTRASOUND
IMAGING PERFORMED BY
AnimalSoundsNW.com 541-357-9423

PATIENT
Blue Light

SPECIES
Canine

BREED
Pitbull

SEX
Spayed Female

AGE
8 Years

WEIGHT
69 Pounds

INTERPRETED BY
R. McKenzie Daniel, DVM, DABVP (Canine and Feline)

IMAGING PERFORMED BY
Sara Hansen

HOSPITAL NAME
Abany AH

REFERRING VET
Dr. Flanagen

INVOICE
17685

DATE
10/13/22

PRESENTING CLINICAL SIGNS

History: multiple skin masses likely mast cell tumors, also on off gastroenteritis

Abnormal PE/Chem/CBC/UA Results: Current Medications cerenia, metronidazole, Primary Question/Differential to Be Answered in This Exam staging of liver/spleen/ lymph nodes prior to scheduling likely mast cell tumor removal for biopsy and histopathological staging. R/o any other cause for intermittent gastroenteritis

ULTRASONOGRAPHIC EXAMINATION OF THE ABDOMEN

Urinary System

The urinary bladder, trigone, cystourethral junction, and visible pelvic urethra to a depth of 3.0 cm exhibited normal thickness and tone. Anechoic urine was present in the lumen with no uroliths or sediment. The ureteral papillae were normal. The ureters were not visible which is normal. No evidence of inflammatory or neoplastic changes were noted.

No evidence of medial iliac or sublumbar lymphadenopathy/masses in the area of the iliac trifurcation or dorsal to the urinary bladder.

Normal size and margination were present in the kidneys. A normal 1:3 cortex / medulla ratio and normal corticomedullary definition were maintained. The echogenicity of the cortex was similar to or slightly less than normal liver parenchyma while the medulla echogenicity was hypoechoic to the cortex with no evidence of pelvic dilation. The left kidney measured 6.9 cm in length. The right kidney measured 6.8 cm in length.

Adrenal Glands

The left adrenal gland exhibited subnormal size with normal position and parenchyma echogenicity, measuring 2.0 cm in length x 0.38 cm at the caudal pole in width.

The right adrenal gland, although indistinctly visualized, exhibited potential for mild prominent size with homogeneous parenchyma, potentially measuring 3.0 cm in length x 1.2 cm at the caudal pole in width. No obvious evidence of a right adrenal tumor or neoplastic criteria.

Spleen

The spleen exhibited a finely textured and homogenous parenchyma which was hyperechoic to the liver and renal cortical parenchyma. The capsule was smooth and regular without apparent expansion. The splenic vasculature at the hilus was normal in volume with no evidence of congestion or thrombosis. Acute to chronic inflammatory, neoplastic, or benign parenchyma changes were not noted.

Liver

The liver was subjectively normal in size, structure, and contour. The liver parenchyma was uniform and hypoechoic to the spleen with a mild coarse echotexture. The hepatic and portal vasculature were normal in appearance without signs of congestion. The gallbladder was non-distended in size with thin walls and primarily anechoic luminal content. The cystic and common bile ducts were normal.

Gastrointestinal

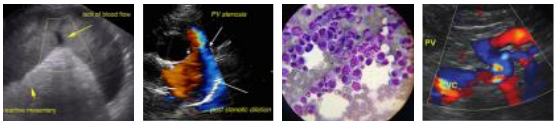

PATIENT

Blue Light

SPECIES

Canine

BREED

Pitbull

SEX

Spayed Female

AGE

8 Years

WEIGHT

69 Pounds

INTERPRETED BY

R. McKenzie Daniel, DVM, DABVP (Canine and Feline)

IMAGING PERFORMED BY

Sara Hansen

HOSPITAL NAME

Abany AH

REFERRING VET

Dr. Flanagen

INVOICE

17685

DATE

10/13/22

The stomach presented intact wall layering with a normal wall layer ratio. The lumen of the stomach contained mild to moderate nonshadowing ingesta/chyme without signs of obstruction or foreign material.

The small intestine presented intact wall layering with 1:3 muscularis/mucosa ratio. Nonshadowing ingesta/chyme was present.

Normal visible colon wall layers were present with apparent formed feces in lumen.

Pancreas

The parenchyma of the left limb, body and right limb of the pancreas presented isoechoic to the adjacent omental fat. A normal curvilinear capsule contour of the pancreas was present. The visible pancreatic duct was normal. No signs of active inflammation or neoplastic disease was evident.

Free Abdomen

No omental masses, lymphadenopathy or evidence of peritoneal free fluid was present.

ULTRASONOGRAPHIC FINDINGS

- Possible prominent right adrenal gland with subnormal left adrenal gland
- Sonographically unremarkable gastrointestinal tract with gastric and segmental intestinal ingesta/chyme
- Otherwise, sonographically normal abdomen

INTERPRETATION OF THE FINDINGS & FURTHER RECOMMENDATIONS

Without overt evidence of significant right adrenal pathology, the clinical significance of the potential prominent right adrenal gland with subnormal left adrenal gland is unclear. Ideally, sonographic reassessment of the right adrenal gland, potentially under sedation to allow better visualization and further assessment, is recommended. Screening blood pressure to assess for evidence of hypertension is warranted. No overt evidence of intrabdominal metastasis from potential cutaneous mast cell tumor. Pending definitive diagnosis, screening splenic FNA cytology could be considered or if recommended by oncology. Dietary intolerance/food allergy, structurally insignificant inflammatory enteropathy, occult parasitism may be considered given the intermittent gastroenteritis signs. Empirically, a limited antigen or hydrolyzed diet trial and empirical deworming may prove beneficial.

SonoPath
Clinical Sonography & Telecytology

EDUCATIONAL TELECONSULTATION SERVICES™

1-800-838-4268 info@sonopath.com SonoPath.com

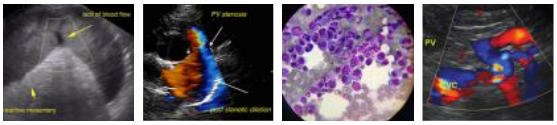

ANIMAL SOUNDS NW
MOBILE VETERINARY ULTRASOUND

IMAGING PERFORMED BY

AnimalSoundsNW.com 541-357-9423

PATIENT

Blue Light

SPECIES

Canine

BREED

Pitbull

SEX

Spayed Female

AGE

8 Years

WEIGHT

69 Pounds

INTERPRETED BY

R. McKenzie Daniel, DVM, DABVP (Canine and Feline)

IMAGING PERFORMED BY

Sara Hansen

HOSPITAL NAME

Abany AH

REFERRING VET

Dr. Flanagen

INVOICE

17685

DATE

10/13/22

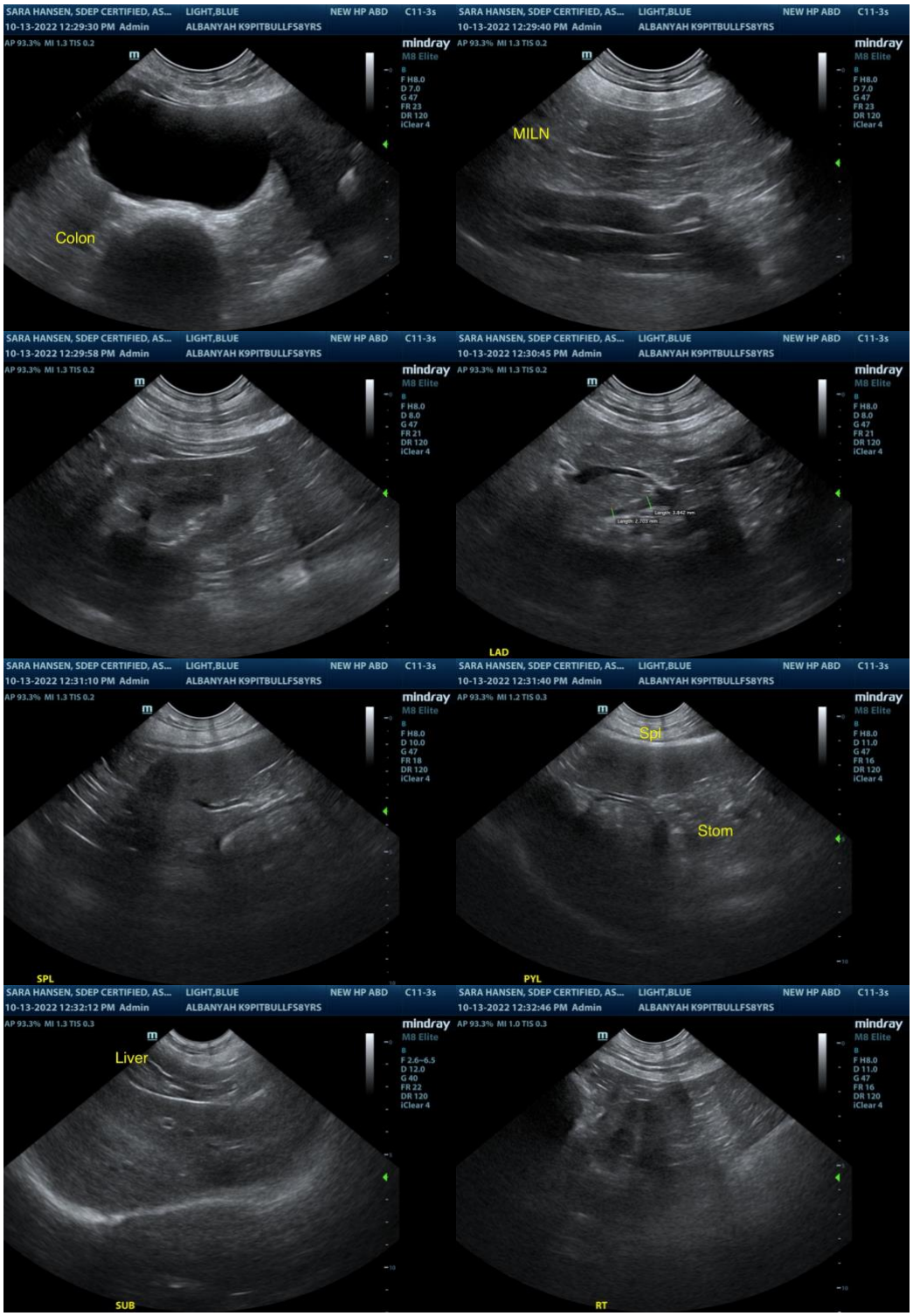

SonoPath
Clinical Sonography & Telecytology
EDUCATIONAL TELECONSULTATION SERVICES™
1-800-838-4268 info@sonopath.com SonoPath.com

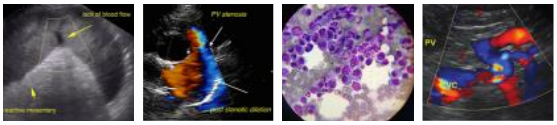

ANIMAL SOUNDS NW
MOBILE VETERINARY ULTRASOUND
IMAGING PERFORMED BY
AnimalSoundsNW.com 541-357-9423

PATIENT

Blue Light

SPECIES

Canine

BREED

Pitbull

SEX

Spayed Female

AGE

8 Years

WEIGHT

69 Pounds

INTERPRETED BY

R. McKenzie Daniel, DVM, DABVP (Canine and Feline)

IMAGING PERFORMED BY

Sara Hansen

HOSPITAL NAME

Abany AH

REFERRING VET

Dr. Flanagen

INVOICE

17685

DATE

10/13/22

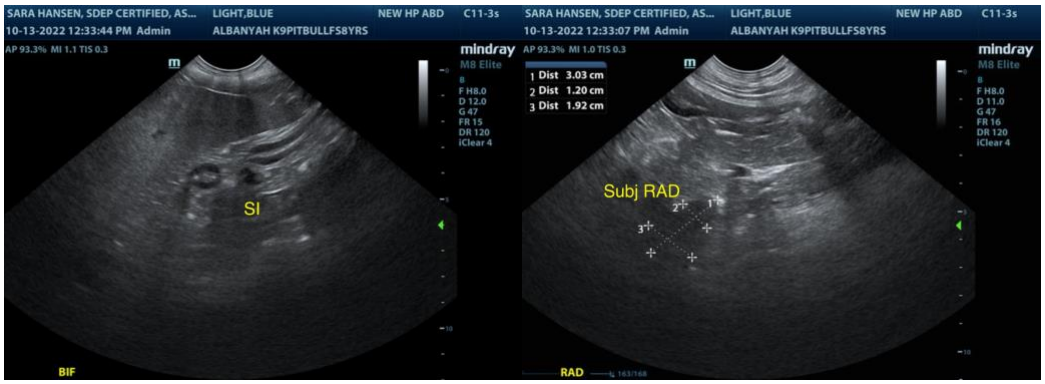

The information and recommendations provided are based on the images presented by the referring veterinarian. No evaluation can be communicated regarding pathology that was not visible in the image/video clips provided.

Thank you for this referral. If the clinical or image interpretation does not parallel your findings or if I can be of any further assistance please contact me.

R. McKenzie Daniel, DVM, DABVP (Canine / Feline Practice)
info@SonoPath.com