



PATIENT

Lou Northwest Dog
Project

SPECIES

Canine

BREED

Pit bull

SEX

FS

AGE

9y

WEIGHT

48 lbs.

INTERPRETED BY

R. McKenzie Daniel,
DVM, DABVP
(Canine and Feline)

**IMAGING
PERFORMED BY**

Jenna Walsh, CVT

HOSPITAL NAME

Eugene AH

REFERRING VET

Dr. Polk

INVOICE

15193

DATE

10/12/22

PRESENTING CLINICAL SIGNS

Murmur was heard by Project's veterinarian, no other information sent over at time of submission. Heart Rate and Respiratory Rates 163 BPM Blood Pressure Measurements 128/93 100 Primary Question/Differential to Be Answered in This Exam Cardiac or splenic disease is the primary concern of the rescue

ULTRASONOGRAPHIC EXAMINATION OF THE ABDOMEN

Urinary System

The urinary bladder, trigone, cystourethral junction, and visible pelvic urethra to a depth of 3.0 cm exhibited normal thickness and tone. Anechoic urine was present in the lumen with no uroliths or sediment. The ureteral papillae were normal. The ureters were not visible which is normal. No evidence of inflammatory or neoplastic changes was noted.

The area of the aortic trifurcation was free of pathology.

Normal size and margination were present in the kidneys. A normal 1:3 cortex / medulla ratio was maintained. The medulla and cortices were uniform in texture with some increased echogenicity and mild loss of corticomedullary symmetry and definition expected for the age of the patient. No evidence of pelvic dilation was present. The left kidney measured 6.2 cm in length. The right kidney measured 6.5 cm in length.

Adrenal Glands

The bilateral adrenal glands were borderline prominent in size based on caudal pole width with subtle asymmetrical capsule contour and maintained homogeneous parenchyma without evidence of parenchymal mineralization. The left adrenal gland measured 3.3 cm length x 0.8 cm width at the caudal pole. The right adrenal gland measured 2.9 cm length x 0.88 cm width at the caudal pole.

Spleen

The spleen exhibited normal size and contour with subtle splenic parenchyma heterogeneity. A nondisruptive, nonuniform, hyperechoic nodule was noted in the cranial spleen without associated capsule distortion, measuring 1.0 cm in diameter.

Liver/ Gallbladder

The liver was subjectively normal in size, structure, and contour. The liver parenchyma was uniform and hypoechoic to the spleen with a mild coarse echotexture. The hepatic and portal vasculature were normal in appearance without signs of congestion. The gallbladder was non-distended in size with thin walls and primarily anechoic luminal content. The cystic and common bile ducts were normal.

Gastrointestinal

The stomach presented intact wall layering with a normal wall layer ratio. The lumen of the stomach contained mild shadowing ingesta with luminal gas. The stomach was otherwise normal.



PATIENT
Lou Northwest Dog
Project

SPECIES

Canine

BREED

Pit bull

SEX

FS

AGE

9y

WEIGHT

48 lbs.

INTERPRETED BY

R. McKenzie Daniel,
DVM, DABVP
(Canine and Feline)

**IMAGING
PERFORMED BY**

Jenna Walsh, CVT

HOSPITAL NAME

Eugene AH

REFERRING VET

Dr. Polk

INVOICE

15193

DATE

10/12/22

The small intestine presented intact wall layering with 1:3 muscularis/mucosa ratio. The lumen of the small intestine was empty with no signs of ileus, obstruction, or foreign material.

Normal visible colon wall layers were present with apparent formed feces in lumen.

Pancreas

The parenchyma of the left limb, body, and right limb of the pancreas presented isoechoic to the adjacent omental fat. A normal curvilinear capsule contour of the pancreas was present. The visible pancreatic duct was normal. No signs of active inflammation or neoplastic disease were evident.

Free Abdomen

No overt lymphadenopathy or peritoneal effusion was present.

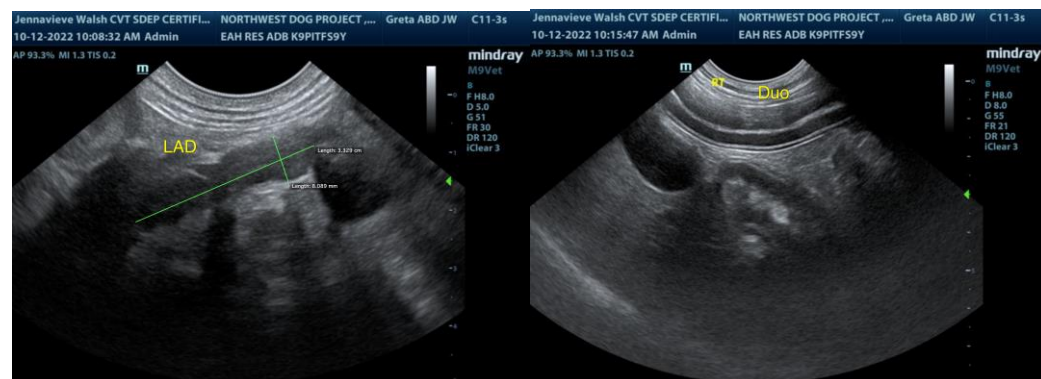
ULTRASONOGRAPHIC FINDINGS

- Early to mild age-related renal changes
- Normal splenic size exhibiting mild parenchyma heterogeneity, solitary benign cranial splenic nodule - consistent with benign myelolipoma, potential for nodular hyperplasia or emerging splenic mineralization
- Bilateral borderline prominent adrenal glands - nonspecific

INTERPRETATION OF THE FINDINGS & FURTHER RECOMMENDATIONS

Overall, no overt evidence of significant visceral pathology, including no evidence of splenic neoplastic criteria. The borderline prominent adrenal glands are of unclear clinical significance, given the hepatic presentation, as well as the lack of reported clinical signs suggestive of adrenal hyperfunction.

Full lab work including CBC/Chemistry panel/Urinalysis and T4 levels is suggested if not done.





PATIENT
Lou Northwest Dog Project

SPECIES

Canine

BREED

Pit bull

SEX

FS

AGE

9y

WEIGHT

48 lbs.

INTERPRETED BY

R. McKenzie Daniel,
DVM, DABVP
(Canine and Feline)

IMAGING PERFORMED BY

Jenna Walsh, CVT

HOSPITAL NAME

Eugene AH

REFERRING VET

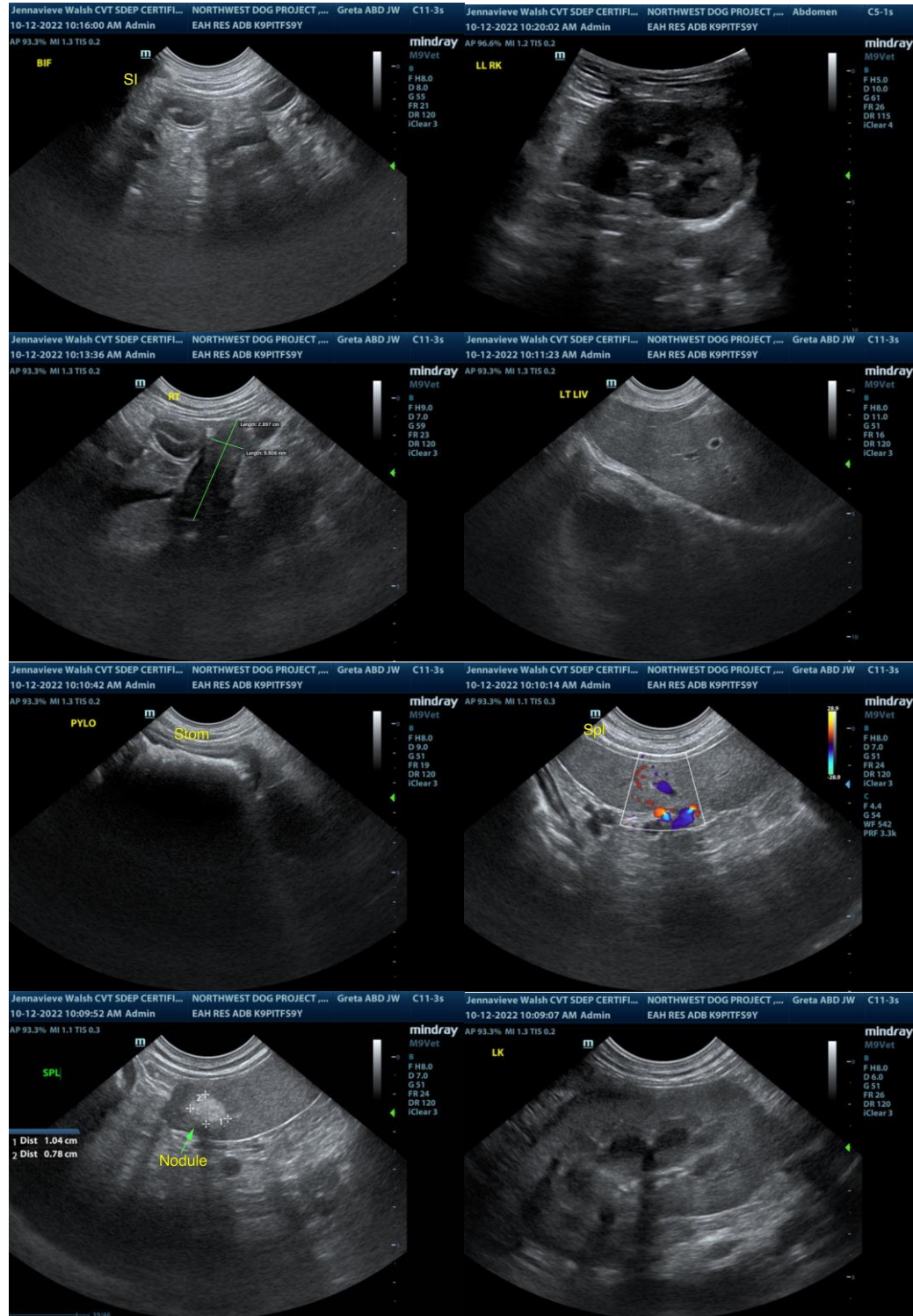
Dr. Polk

INVOICE

15193

DATE

10/12/22





PATIENT
Lou Northwest Dog Project

SPECIES
Canine

BREED
Pit bull

SEX
FS

AGE
9y

WEIGHT
48 lbs.

INTERPRETED BY
R. McKenzie Daniel,
DVM, DABVP
(Canine and Feline)

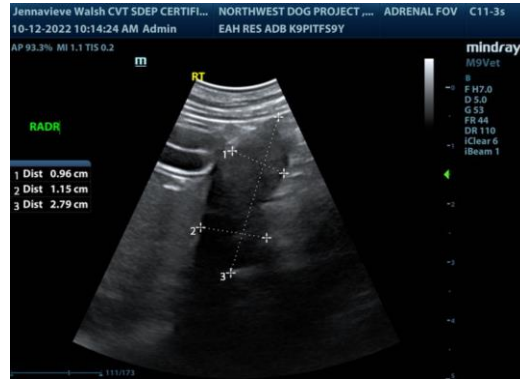
IMAGING PERFORMED BY
Jenna Walsh, CVT

HOSPITAL NAME
Eugene AH

REFERRING VET
Dr. Polk

INVOICE
15193

DATE
10/12/22



The information and recommendations provided are based on the images presented by the referring veterinarian/sonographer. No evaluation can be communicated regarding pathology that was not visible in the image/video clips provided.

Thank you for this referral. If the clinical or image interpretation does not parallel your findings or if I can be of any further assistance please contact me.

R. McKenzie Daniel, DVM, DABVP (Canine / Feline Practice)
info@SonoPath.com