



PATIENT

Leo Perathi

SPECIES

Feline

BREED

Coton de Tulear

SEX

Male

AGE

1.5

WEIGHT

11

INTERPRETED BY

R. McKenzie Daniel,
DVM, DABVP
(Canine and Feline)

IMAGING PERFORMED BY

Jenn

HOSPITAL NAME

Rockaway AH

REFERRING VET

Dr. Ascot

INVOICE

15172

DATE

10/12/22

PRESENTING CLINICAL SIGNS

intermittent vomiting concern for foreign material within stomach

ULTRASONOGRAPHIC EXAMINATION OF THE ABDOMEN

Urinary System

The urinary bladder, trigone, and cystourethral junction exhibited normal thickness and tone. Anechoic urine was present in the lumen with no uroliths or sediment. The ureteral papillae were normal. The ureters were not visible which is normal. No evidence of inflammatory or neoplastic changes was noted.

The area of the aortic trifurcation was free of pathology.

Normal margination was present in the kidneys. A normal 1:3 cortex / medulla ratio and normal corticomedullary definition were maintained. The echogenicity of the cortex was similar to or slightly less than normal liver parenchyma while the medulla echogenicity was hypoechoic to the cortex with no evidence of pelvic dilation. The left kidney measured 3.7 cm in length. The right kidney was potentially mildly subnormal in size compared to the left, although some degree of measurement variability is possible. The right kidney measured 3.1 cm in length.

Adrenal Glands

The left adrenal gland was uniform in size and contour with a uniformly hypoechoic parenchyma. The left adrenal gland measured 1.6 cm length x 0.34 cm width at the caudal pole. The right adrenal gland was uniform in size and contour with a uniformly hypoechoic parenchyma. The right adrenal gland measured 1.8 cm length x 0.56 cm width at the caudal pole.

Spleen

The spleen exhibited a finely textured and homogenous parenchyma which was hyperechoic to the liver and renal cortical parenchyma. The capsule was smooth and regular without apparent expansion. The splenic vasculature at the hilus was normal in volume with no evidence of congestion or thrombosis. Acute to chronic inflammatory, neoplastic, or benign parenchyma changes were not noted.

Liver/ Gallbladder

The liver was subjectively normal in size, structure, and contour. The liver parenchyma was uniform and hypoechoic to the spleen with a mild coarse echotexture. The hepatic and portal vasculature were normal in appearance without signs of congestion. The gallbladder was non-distended in size with thin walls and primarily anechoic luminal content. The cystic and common bile ducts were normal.

Gastrointestinal

The stomach presented intact wall layering with a normal wall layer ratio. The lumen of the stomach was empty containing minor luminal gas with no signs of ileus, obstruction, or foreign material. No evidence of gastric distention with retained fluid, ingesta, or foreign material.

The small intestine presented intact wall layering with 1:3 muscularis/mucosa ratio. The lumen of the small intestine was empty with no signs of mechanical / metabolic ileus, obstruction, or foreign material.



PATIENT

Normal visible colon wall layers were present with apparent formed feces in lumen.

Leo Perathi

Pancreas

SPECIES

The parenchyma of the left limb, body, and right limb of the pancreas presented isoechoic to the adjacent omental fat. A normal curvilinear capsule contour of the pancreas was present. The visible pancreatic duct was normal. No signs of active inflammation or neoplastic disease were evident.

Feline

BREED

Free Abdomen

Coton de Tulear

No overt lymphadenopathy or peritoneal effusion was present.

SEX

ULTRASONOGRAPHIC FINDINGS

Male

- Sonographically unremarkable abdomen

AGE

INTERPRETATION OF THE FINDINGS & FURTHER RECOMMENDATIONS

1.5

No evidence of gastric or gastrointestinal foreign material or mechanical / metabolic ileus. Dietary intolerance/ food allergy, occult parasitism, and low-grade inflammatory gastroenteropathy are all potentials. Supportive care should prove effective. A resting cortisol level to rule out occult Addison's Disease.

WEIGHT

11

INTERPRETED BY

R. McKenzie Daniel,
DVM, DABVP
(Canine and Feline)

IMAGING PERFORMED BY

Jenn

HOSPITAL NAME

Rockaway AH

REFERRING VET

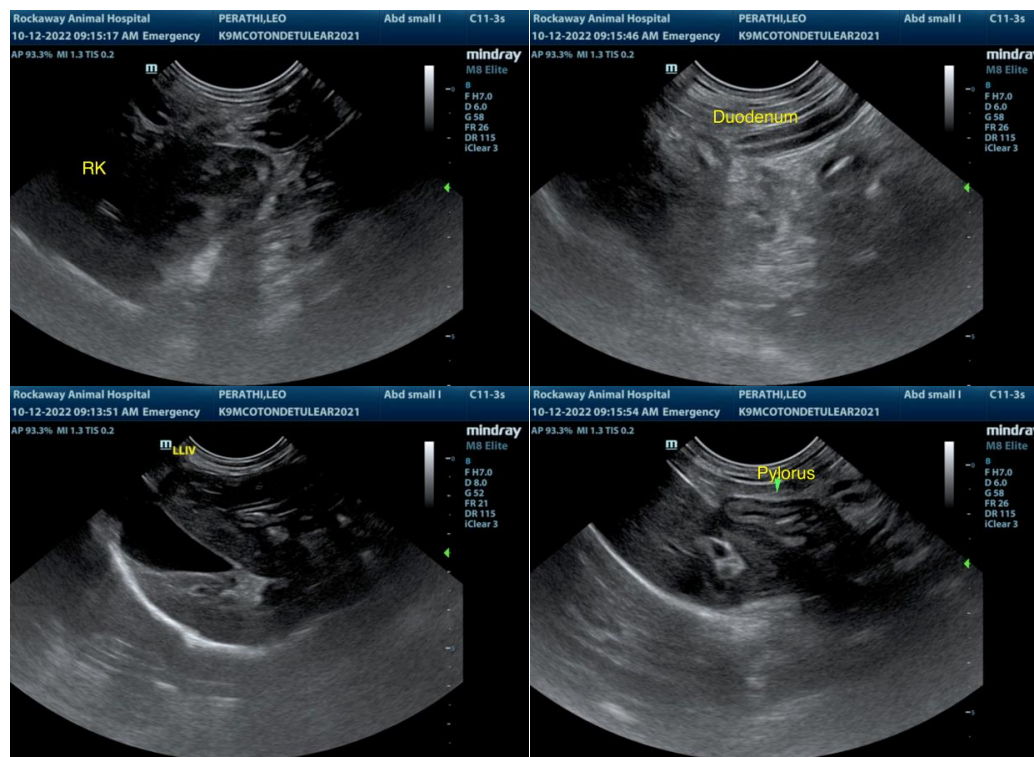
Dr. Ascot

INVOICE

15172

DATE

10/12/22





PATIENT

Leo Perathi

SPECIES

Feline

BREED

Coton de Tulear

SEX

Male

AGE

1.5

WEIGHT

11

INTERPRETED BY

R. McKenzie Daniel,
DVM, DABVP
(Canine and Feline)

IMAGING PERFORMED BY

Jenn

HOSPITAL NAME

Rockaway AH

REFERRING VET

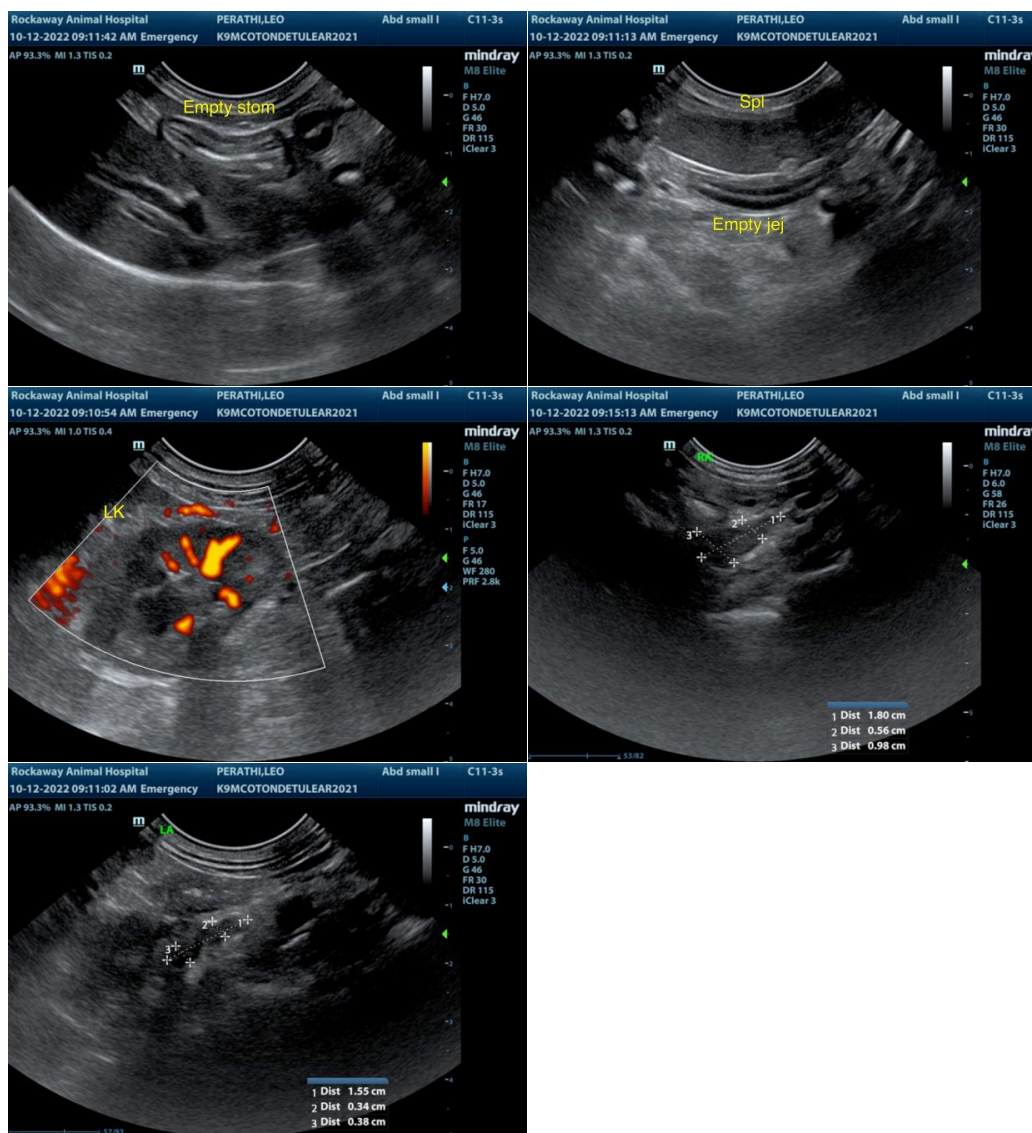
Dr. Ascot

INVOICE

15172

DATE

10/12/22



The information and recommendations provided are based on the images presented by the referring veterinarian/sonographer. No evaluation can be communicated regarding pathology that was not visible in the image/video clips provided.

Thank you for this referral. If the clinical or image interpretation does not parallel your findings or if I can be of any further assistance please contact me.

R. McKenzie Daniel, DVM, DABVP (Canine / Feline Practice)
info@SonoPath.com