


**PATIENT PRESENTING CLINICAL SIGNS**

Grady Perrin Pericardial Effusion, Elevated AL, GGT, and ALKP Current meds: Gabapentin and Cerenia  
 Abnormal PE/Chem/CBC/UA Results: ALKP >2000, ALT increased (unable to read on in-house machine), GGT 22, Kt 3.4

**SPECIES**

Canine

**ULTRASONOGRAPHIC EXAMINATION OF THE HEART & ABDOMEN**
**BREED**

Golden Retriever

**SEX**

Neutered Male

**AGE**

10 Years

**WEIGHT**

104 Pounds

CANINE CARDIAC PARAMETERS	MR VMAX (m/s)	TR VMAX (m/s)	LA/AO (Boon method)	LA/AO (Heart Base; Swe)	FS (%)	EF (%)	EPSS (cm)
NORMAL PARAMETER	4.5-5.5	<2.7	1.3	<1.6	28-40	40-100	<0.6
PATIENT			NM	1.45	34.8	67.5	0.62
CANINE CARDIAC PARAMETERS	HR (BPM)	AV VMAX (m/s)	PV MAX (m/s)	BODY WEIGHT (kg)	LA 2D short axis Base view (cm)	LVIDd Avg; 2D and m-mode short axis (cm)	LVIDs Avg; 2D and m-mode short axis (cm)
NORMAL PARAMETER	50-100	0.7-1.7	0.7-1.6				
PATIENT	128	1.2	1.2		4.6	4.6	

**INTERPRETED BY**

 R. McKenzie Daniel,  
 DVM, DABVP  
 (Canine and Feline)

**IMAGING PERFORMED BY**

Jessica Miller

**HOSPITAL NAME**

Tranquility VC

**REFERRING VET**

Dr. Kurapati

**Cardiac Presentation**

The echocardiogram in this patient demonstrated normal **left atrial** size based on 3 separate methods of LA evaluation. The cranial and caudal **mitral** valve leaflets presented normal linear structure, extension in systole, and union in diastole with normal kinesis. The **left ventricle** presented thicknesses with linear contour and was not dilated nor restricted. The **myocardium** presented normal echogenicity without subjective evidence of significant fibrotic or ischemic disease. **Contractility** of the ventricular walls was adequate and in normal range for this patient evidenced by the fractional shortening measurement and subjective evaluation of the different regions of the myocardium. The **left ventricular outflow** tract demonstrated normal laminar flow and subjective structural integrity. The **right atrium** and auricle revealed normal size, structure and content. No evidence of masses was noted. **Tricuspid** valvular assessment demonstrated adequate linear morphology and kinesis. The **right ventricle** was of normal size (1/3 diameter of LV), chordae structure, myocardial echogenicity and thickness. **Pulmonary outflow** tract assessment revealed normal valve structure, laminar flow, and diameter (approx. 1:1 pa/ao ratio). No visible **pericardial** or free pleura fluid was noted. The cranial **mediastinum and pericardial and extra-cardiac regions** were free of masses in the visible window.

**Urinary System**
**INVOICE**

26201

**DATE**

10/12/21

The urinary bladder, trigone, cystourethral junction, and visible pelvic urethra to a depth of – cm exhibited normal thickness and tone. Anechoic urine was present in the lumen with no uroliths or sediment. The ureteral papillae were normal. The ureters were not visible which is normal. No evidence of inflammatory or neoplastic changes were noted.

No overt pathology associated with the residual prostate. The aortic trifurcation was normal.



<b>PATIENT</b>	Normal size and margination were present in the kidneys. A normal 1:3 cortex / medulla ratio was maintained. The medulla and cortices were uniform in texture with some increased echogenicity and loss of corticomedullary symmetry and definition expected for the age of the patient. No evidence of pelvic dilation was present. The left kidney measured 6.6 cm. The right kidney measured 7.6 cm.
Grady Perrin	
<b>SPECIES</b>	<b>Adrenal Glands</b>
Canine	The left adrenal gland was normal in size. Mild parenchyma heterogeneity and mild capsule asymmetry was present without suspicion for overt neoplasia. The left adrenal gland measured 4.1 cm length x 0.54 cm at the caudal pole.
<b>BREED</b>	<b>Spleen</b>
Golden Retriever	The right adrenal gland was indistinctly visualized owing to patient size, yet without overt pathology, subjectively measuring 3.3 cm length x 0.82 cm.
<b>SEX</b>	<b>Liver</b>
Neutered Male	The spleen exhibited primarily finely textured and homogenous parenchyma which was hyperechoic to the liver and renal cortical parenchyma. Multifocal, well-defined, symmetrical, echogenic nodules were present primarily around the splenic hilus. The capsule was smooth and regular without apparent expansion. The splenic vasculature at the hilus was normal in volume with no evidence of congestion or thrombosis. Acute to chronic inflammatory or neoplastic changes were not noted. The echogenic nodules tend to trend benign and are most consistent with benign hyperplasia or myelolipomas.
<b>AGE</b>	<b>Gastrointestinal</b>
10 Years	The stomach presented mild wall thickening secondary to echogenic mucosa hypertrophy. Intact wall layering was maintained and distinct. Mild to moderate retained anechoic to mildly echogenic fluid and chyme present in the stomach. No evidence of mechanical pyloric outflow obstruction. Gastric body wall measured 0.40 cm.
<b>WEIGHT</b>	<b>Liver</b>
104 Pounds	The liver exhibited generalized mild enlargement with maintained symmetrical capsule contour. Mild generalized increased hepatic parenchyma echogenicity noted compared to the falciform fat and renal cortices with moderate coarse echotexture. No hepatic masses or nodules noted. The gallbladder was non distended in size with moderate, echogenic, nonmineralized biliary sludge. The gallbladder walls were sonographically unremarkable. Mild cystic biliary duct dilation containing a mild amount of concurrent debris was present. No evidence of peripheral inflammation.
<b>INTERPRETED BY</b>	<b>Gastrointestinal</b>
R. McKenzie Daniel, DVM, DABVP (Canine and Feline)	The intestinal walls demonstrated intact wall layering and maintained 1:3 muscularis / mucosa ratio. The mucosa exhibited mild decreased echogenicity with occasional mucosal speckling. A segmental to diffuse ileus pattern consisting of mild fluid accumulation in the intestinal lumen was present without obstruction or foreign material. Duodenum wall measured 0.50 cm.
<b>IMAGING PERFORMED BY</b>	<b>Pancreas</b>
Jessica Miller	The pancreas presented isoechoic to the adjacent omental fat. A normal curvilinear capsule contour of the pancreas was present. The visible pancreatic duct was normal. No signs of active inflammation or neoplastic disease was evident.
<b>HOSPITAL NAME</b>	
Tranquility VC	
<b>REFERRING VET</b>	
Dr. Kurapati	
<b>INVOICE</b>	
26201	
<b>DATE</b>	
10/12/21	



**PATIENT**

**Free Abdomen**

Grady Perrin

Focal enlarged mid abdominal mesenteric lymph node was present measuring 3.0 cm x 1.0 cm. This lymph node was homogenous, mildly hypoechoic and smoothly marginated. A normal width: length ratio was maintained (<0.5). Evidence of perilymphatic inflammation was evident.

**SPECIES**

Canine

No evidence of peritoneal effusion. The omentum was of uniform echogenicity.

**BREED**

Golden Retriever

**ULTRASONOGRAPHIC FINDINGS**

- Overtly normal cardiac structure and function for age
- Hepatopathy – Vacuolar hepatopathy, cholestasis, hepatitis/cholangiohepatitis (infectious, immune mediated), neoplasia, or other hepatopathy possible.
- Moderate gallbladder (non-mucocele)
- Gastroenteritis pattern
- Age related spleen with benign nodules – consistent with probable benign myelolipomas

**AGE**

10 Years

**INTERPRETATION OF THE FINDINGS & FURTHER RECOMMENDATIONS**

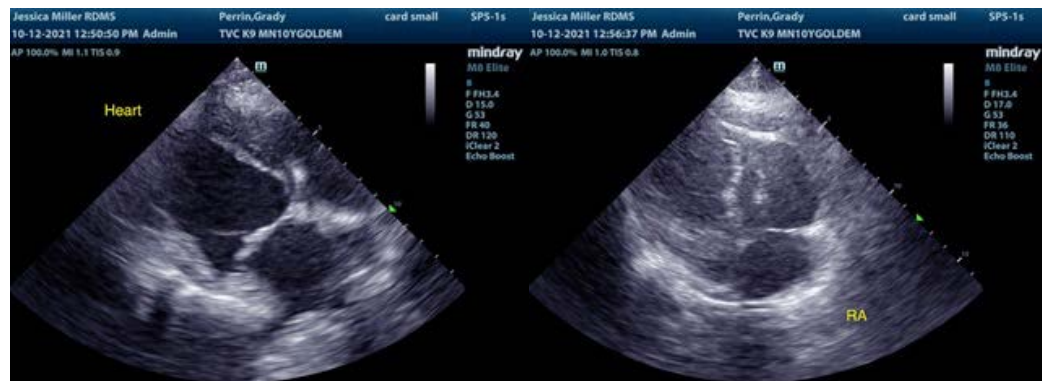Further assessment of the liver (assuming normal clotting status) may include ultrasound guided FNA for screening cytology, potentially to identify inflammatory cell type if present as well as to assess for potential neoplasia. No overt evidence of hepatic neoplastic criteria indicating neoplasia, which may be considered a less likely differential diagnosis yet cannot be excluded. Given the predominantly elevated ALT and presence of gallbladder debris, non-specific hepatitis/cholangiohepatitis may be considered a primary differential diagnosis. Hepatosupportive medications including Denamarin and Ursodiol +/- appropriate empirical antibiotic trial (initially for two weeks with reassessment of hepatic enzymes) would be appropriate. Leptospirosis titers/PCR may be considered if clinically indicated. Continued as needed gastrointestinal support is suggested. No evidence of pericardial effusion or pericardial masses noted.

**WEIGHT**

104 Pounds

**INTERPRETED BY**

R. McKenzie Daniel,  
DVM, DABVP  
(Canine and Feline)



**IMAGING PERFORMED BY**

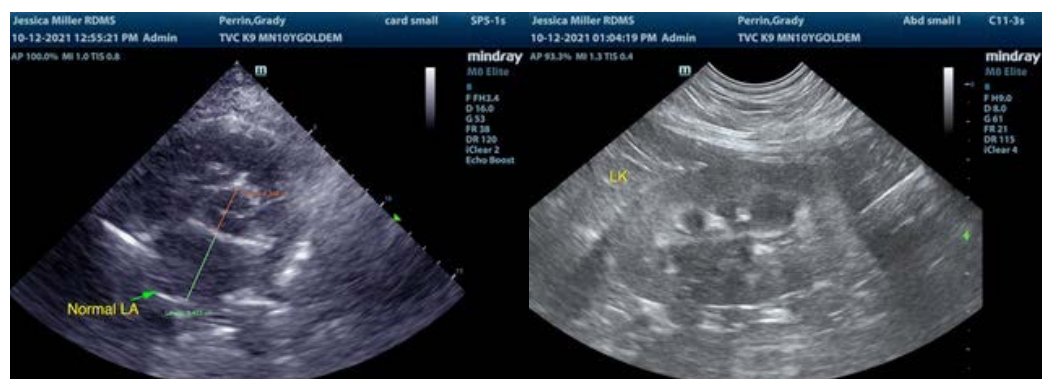
Jessica Miller

**HOSPITAL NAME**

Tranquility VC

**REFERRING VET**

Dr. Kurapati



**INVOICE**

26201

**DATE**

10/12/21



**PATIENT**

Grady Perrin

**SPECIES**

Canine

**BREED**

Golden Retriever

**SEX**

Neutered Male

**AGE**

10 Years

**WEIGHT**

104 Pounds

**INTERPRETED BY**

R. McKenzie Daniel,  
DVM, DABVP  
(Canine and Feline)

**IMAGING PERFORMED BY**

Jessica Miller

**HOSPITAL NAME**

Tranquility VC

**REFERRING VET**

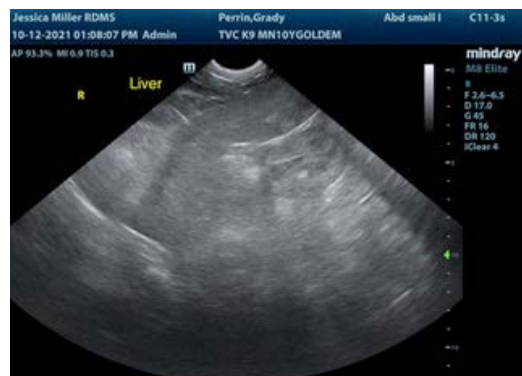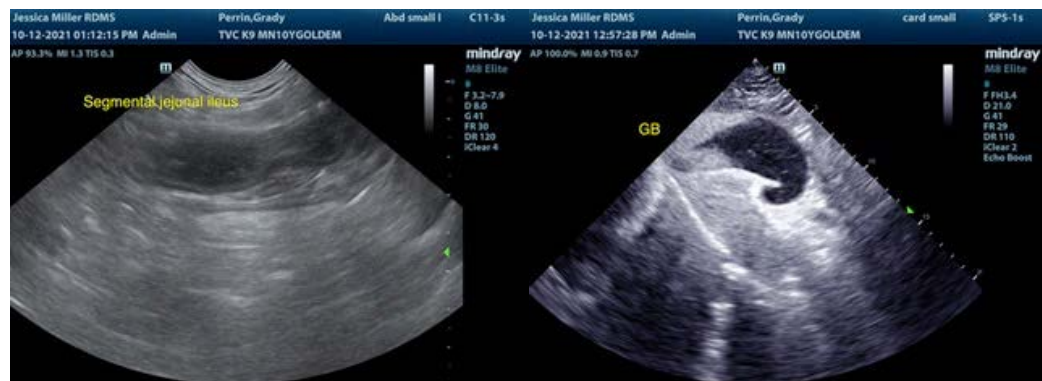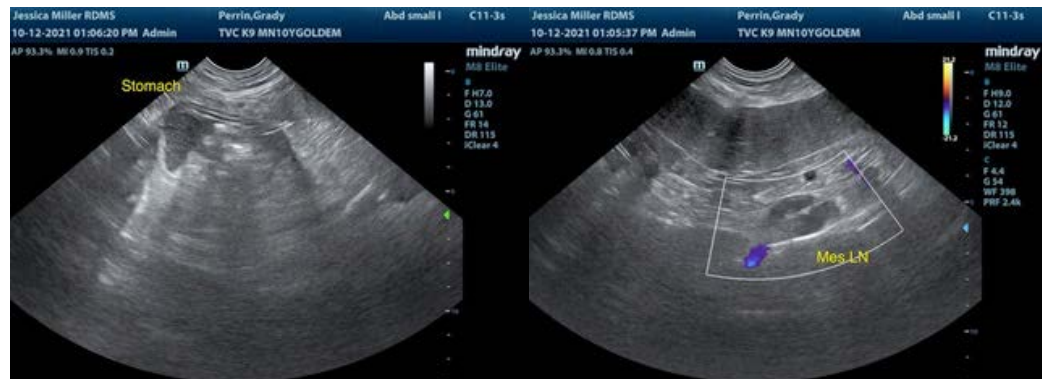
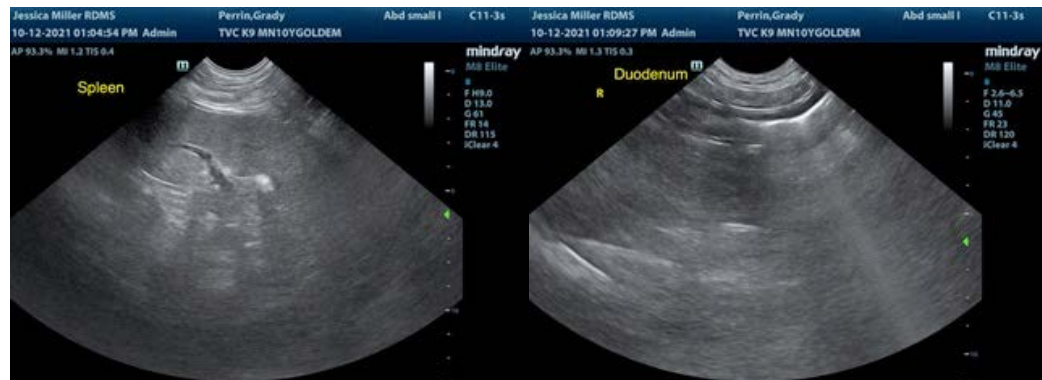
Dr. Kurapati

**INVOICE**

26201

**DATE**

10/12/21





**PATIENT**

Grady Perrin

The information and recommendations provided are based on the images presented by the referring veterinarian. No evaluation can be communicated regarding pathology that was not visible in the image/video clips provided.

**SPECIES**

Canine

Thank you for this referral. If the clinical or image interpretation does not parallel your findings or if I can be of any further assistance please contact me.

**BREED**

Golden Retriever

**R. McKenzie Daniel, DVM, DABVP (Canine / Feline Practice)**  
info@SonoPath.com

**SEX**

Neutered Male

**AGE**

10 Years

**WEIGHT**

104 Pounds

**INTERPRETED BY**

R. McKenzie Daniel,  
DVM, DABVP  
(Canine and Feline)

**IMAGING  
PERFORMED BY**

Jessica Miller

**HOSPITAL NAME**

Tranquility VC

**REFERRING VET**

Dr. Kurapati

**INVOICE**

26201

**DATE**

10/12/21