



PATIENT PRESENTING CLINICAL SIGNS

Roxie Taylor Declining energy level and attitude without any clear abnormality on PE. Moderate to severe dental disease, history of elevated alkaline phosphatase, BW done in advance of planned dental.

SPECIES Abnormal PE/Chem/CBC/UA Results: ALKP 1097, triglycerides 1095, Precision PSL 163.

Canine

Urinary System

BREED

Tibetan Terrier

The urinary bladder, trigone, and cystourethral junction exhibited normal thickness and tone. Anechoic urine was present in the lumen with no uroliths or sediment. The ureteral papillae were normal. The ureters were not visible which is normal. No evidence of inflammatory or neoplastic changes was noted.

SEX

Spayed Female

Mildly prominent medial iliac lymph nodes were present. The lymph nodes were essentially isoechoic to adjacent omentum without evidence of peripheral inflammation and maintaining a normal width: length ratio (<0.5). An example of the lymph nodes measured 0.53 cm diameter. These lymph nodes were not consistent with Inflammatory or neoplastic criteria, and are likely incidental.

AGE

13 years

Normal size and margination were present in the kidneys. A normal 1:3 cortex / medulla ratio was maintained. The medulla and cortices were uniform in texture with some increased echogenicity and mild loss of corticomedullary symmetry and definition expected for the age of the patient. Very scant pyelectasia was noted in the left kidney. The left kidney measured 5.2 cm in length. The right kidney measured 5.8 cm in length.

WEIGHT

28.1 lbs.

Adrenal Glands

INTERPRETED BY

R. McKenzie Daniel, DVM,
 DABVP (Canine and
 Feline)

The left adrenal gland was uniform in size and contour with a uniformly hypoechoic parenchyma. The left adrenal gland measured 0.36 cm width at the caudal pole and 0.28 cm width at the cranial pole. The right adrenal gland was uniform in size and contour with a uniformly hypoechoic parenchyma. The right adrenal gland measured 0.50 cm width at the caudal pole and 0.37 cm width at the cranial pole.

IMAGING PERFORMED BY

Pamela Harrigan, RDCS

Spleen

HOSPITAL NAME

Wood River AH

The spleen exhibited a finely textured and homogenous parenchyma which was hyperechoic to the liver and renal cortical parenchyma. Mild medial folding of the caudal spleen was present, which is nonindicative of underlying splenic pathology and likely a patient variant. The splenic vasculature at the hilus was normal in volume with no evidence of congestion or thrombosis. Acute to chronic inflammatory, neoplastic, or benign parenchyma changes were not noted.

REFERRING VET

Casey Schulke, DVM

Liver/ Gallbladder

INVOICE

12387

The liver presented mildly enlarged in size. The parenchyma of the liver was subjectively normal in echogenicity compared to the spleen and renal cortices. The liver parenchyma was uniform with a mildly coarse echotexture. The capsule of the liver was symmetrically rounded to mildly swollen in margination. The hepatic and portal vasculature were normal in appearance without signs of congestion. The gallbladder was non-distended in size with minor, echogenic, nonorganized gallbladder debris. The cystic and common bile ducts were normal.

DATE

10/11/21



PATIENT

Roxie Taylor

Gastrointestinal

SPECIES

Canine

BREED

Tibetan Terrier

SEX

Spayed Female

AGE

13 years

WEIGHT

28.1 lbs.

INTERPRETED BY

R. McKenzie Daniel, DVM,
DABVP (Canine and
Feline)

**IMAGING
PERFORMED BY**

Pamela Harrigan, RDCS

HOSPITAL NAME

Wood River AH

REFERRING VET

Casey Schulke, DVM

INVOICE

12387

DATE

10/11/21

The stomach presented intact wall layering with a normal wall layer ratio. The lumen of the stomach was empty with no signs of ileus, obstruction, or foreign material. The gastric body wall width measured 0.35 cm.

The small intestine presented intact wall layering with 1:3 muscularis/mucosa ratio. The lumen of the small intestine was empty with no signs of ileus, obstruction, or foreign material. The duodenum wall width measured 0.34 cm. The jejunum wall width measured 0.29 cm.

Normal visible colon wall layers were present with apparent formed feces in lumen.

Pancreas

The pancreas was normal in size and contour with isoechoic to heterogeneous parenchyma compared to adjacent omentum. No signs of active inflammation or neoplasia.

Free Abdomen

No overt lymphadenopathy or peritoneal effusion was present.

ULTRASONOGRAPHIC FINDINGS

Primary Findings

- Mild chronic renal changes
- Vacuolar hepatopathy pattern
- Minor gallbladder debris
- Heterogeneous pancreas

INTERPRETATION OF THE FINDINGS & FURTHER RECOMMENDATIONS

Largely geriatric abdomen without evidence of significant visceral pathology.

The gallbladder debris may be secondary to fasting or indicate nonclinical cholestasis.

The heterogeneous pancreas is nonspecific yet suggestive of age-related pancreatic changes. The potential for mild chronic to low-grade pancreatitis is possible, given the elevated PSL level.

An obvious cause of the patient's clinical signs was not overtly evidence within the abdominal cavity. No contraindications to anesthesia. Fasting triglyceride level may be considered if persistently elevated.



PATIENT

Roxie Taylor

SPECIES

Canine

BREED

Tibetan Terrier

SEX

Spayed Female

AGE

13 years

WEIGHT

28.1 lbs.

INTERPRETED BY

R. McKenzie Daniel, DVM,
 DABVP (Canine and Feline)

IMAGING PERFORMED BY

Pamela Harrigan, RDCS

HOSPITAL NAME

Wood River AH

REFERRING VET

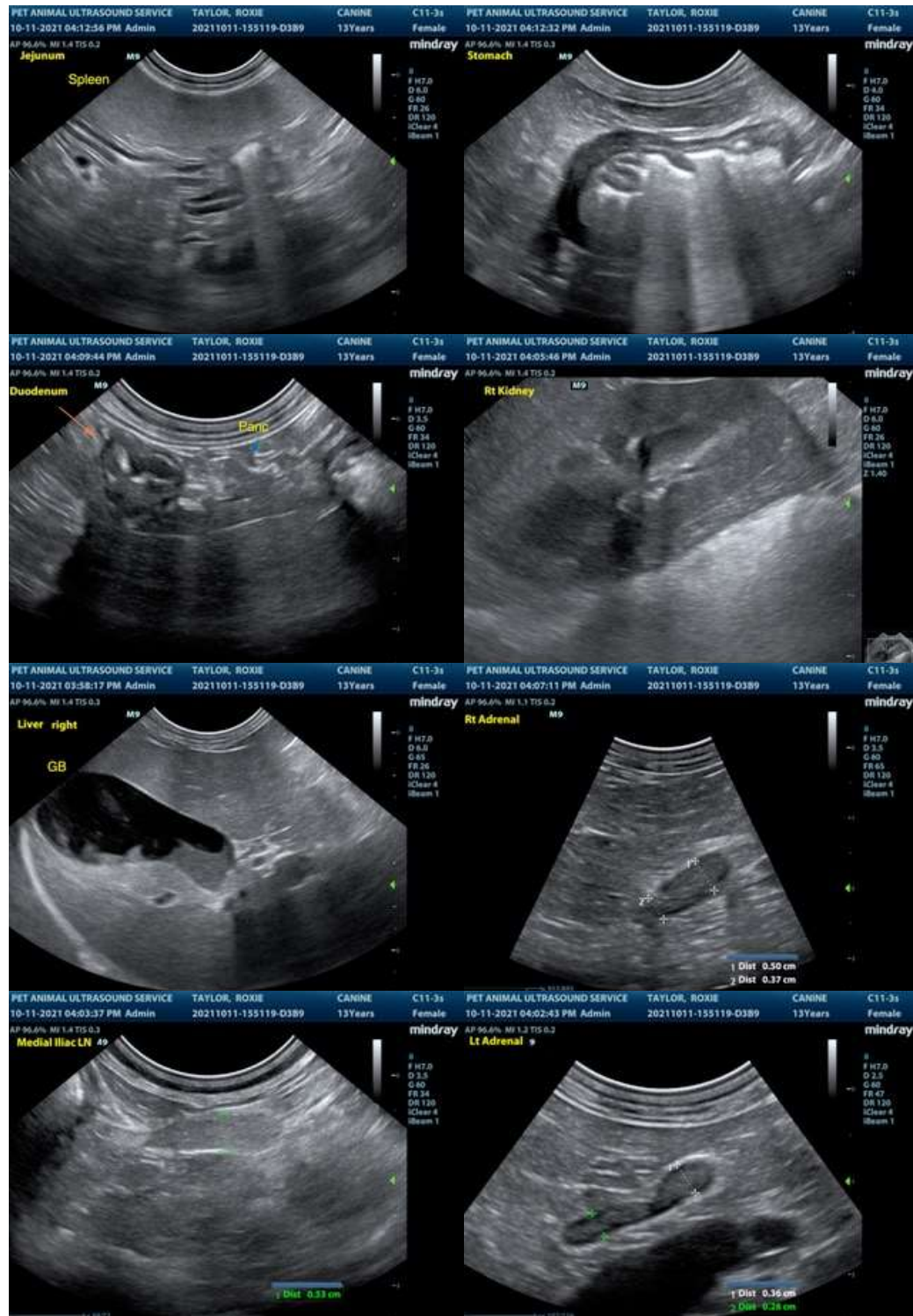
Casey Schulke, DVM

INVOICE

12387

DATE

10/11/21





PATIENT

Roxie Taylor

SPECIES

Canine

BREED

Tibetan Terrier

SEX

Spayed Female

AGE

13 years

WEIGHT

28.1 lbs.

INTERPRETED BY

R. McKenzie Daniel, DVM,
DABVP (Canine and
Feline)

**IMAGING
PERFORMED BY**

Pamela Harrigan, RDMS

HOSPITAL NAME

Wood River AH

REFERRING VET

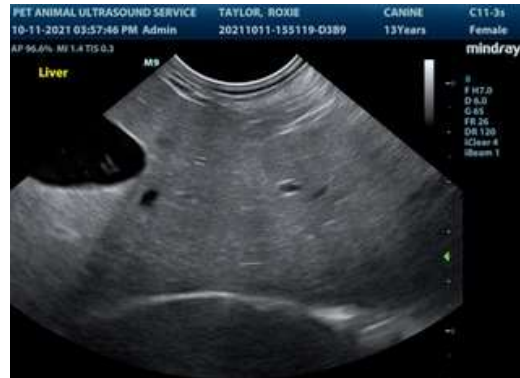Casey Schulke, DVM

INVOICE

12387

DATE

10/11/21



The information and recommendations provided are based on the images presented by the referring veterinarian. No evaluation can be communicated regarding pathology that was not visible in the image/video clips provided.

Thank you for this referral. If the clinical or image interpretation does not parallel your findings or if I can be of any further assistance please contact me.

R. McKenzie Daniel, DVM, DABVP (Canine / Feline Practice)
info@SonoPath.com