

**PATIENT**

Millie Schneck

**SPECIES**

Canine

**BREED**

Trammell

**SEX**

Spayed Female

**AGE**

7 years

**WEIGHT**

31 lbs.

**INTERPRETED BY**

R. McKenzie Daniel,  
DVM, DABVP  
(Canine and Feline)

**IMAGING PERFORMED BY**

Sarah Pender, CVT

**HOSPITAL NAME**

SVS Imaging QC

**REFERRING VET**

Dr. Trammell

**INVOICE**

12389

**DATE**

10/11/21

**PRESENTING CLINICAL SIGNS**

-No significant findings on PE. Fecal flotation negative. CBC/Chemistry unremarkable. Texas GI panel unremarkable - mild folate elevation possibly related to intestinal dysbiosis. No significant improvement with Panacur, probiotic, diet trial with Hill's Gastrointestinal biome.

**ULTRASONOGRAPHIC EXAMINATION OF THE ABDOMEN****Urinary System**

The urinary bladder, trigone, cystourethral junction, and visible pelvic urethra to a depth of 3.0 cm exhibited normal thickness and tone. Anechoic urine was present in the lumen with no uroliths or sediment. The ureteral papillae were normal. The ureters were not visible which is normal. No evidence of inflammatory or neoplastic changes was noted.

The area of the aortic trifurcation was free of pathology.

Normal size and margination were present in the kidneys. A normal 1:3 cortex / medulla ratio and normal corticomedullary definition were maintained. The echogenicity of the cortex was similar to or slightly less than normal liver parenchyma while the medulla echogenicity was hypoechoic to the cortex with no evidence of pelvic dilation. The left kidney measured 5.7 cm in length. The right kidney measured 5.6 cm in length.

**Adrenal Glands**

The left adrenal gland was uniform in size and contour with a uniformly hypoechoic parenchyma. The left adrenal gland measured 2.1 cm length x 0.53 cm width at the caudal pole. The right adrenal gland was uniform in size and contour with a uniformly hypoechoic parenchyma. The right adrenal gland measured 3.1 cm length x 0.42 cm width at the caudal pole.

**Spleen**

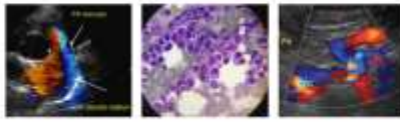The spleen exhibited a finely textured and homogenous parenchyma which was hyperechoic to the liver and renal cortical parenchyma. The capsule was smooth and regular without apparent expansion. The splenic vasculature at the hilus was normal in volume with no evidence of congestion or thrombosis. Acute to chronic inflammatory, neoplastic, or benign parenchyma changes were not noted.

**Liver/ Gallbladder**

The liver was subjectively normal in size, structure, and contour. The liver parenchyma was uniform and hypoechoic to the spleen with a mild coarse echotexture. The hepatic and portal vasculature were normal in appearance without signs of congestion. The gallbladder was non-distended in size with thin walls and primarily anechoic luminal content. The cystic and common bile ducts were normal.

**Gastrointestinal**

The stomach presented intact wall layering with a normal wall layer ratio. Minor echogenic ingesta and chyme were present in the gastric lumen, along with luminal gas. The gastric body wall width measured 0.28 cm.

**PATIENT**

Millie Schneck

The small intestine presented intact wall layering with 1:3 muscularis/mucosa ratio. The lumen of the small intestine was empty with no signs of ileus, obstruction, or foreign material. The duodenum wall width measured 0.40 cm. The jejunum wall width measured 0.39 cm.

**SPECIES**

Canine

The colon was sonographically unremarkable containing formed to semi-formed feces in the lumen.

***Pancreas***

The parenchyma of the left limb, body, and right limb of the pancreas presented isoechoic to the adjacent omental fat. A normal curvilinear capsule contour of the pancreas was present. The visible pancreatic duct was normal. No signs of active inflammation or neoplastic disease were evident.

**BREED**

Trammell

***Free Abdomen*****SEX**

Spayed Female

No overt lymphadenopathy or peritoneal effusion was present.

**ULTRASONOGRAPHIC FINDINGS****AGE**

7 years

***Primary Findings***

- Sonographically unremarkable abdomen
- Minor retained gastric ingesta / chyme

**WEIGHT**

31 lbs.

**INTERPRETATION OF THE FINDINGS & FURTHER RECOMMENDATIONS**

No evidence of visceral, specifically gastroenterocolic, pathology.

**INTERPRETED BY**

R. McKenzie Daniel,  
DVM, DABVP  
(Canine and Feline)

Although nonspecific, the mild folate elevation may indicate upper intestinal disease. Given the lack of improvement with prophylactic deworming, probiotics, and dietary trial, an antibiotic trial such as Metronidazole or Tylosin, along with continued supportive care including high colony count probiotic and potential diet rotation with a limited antigen to hydrolyzed diet may prove beneficial.

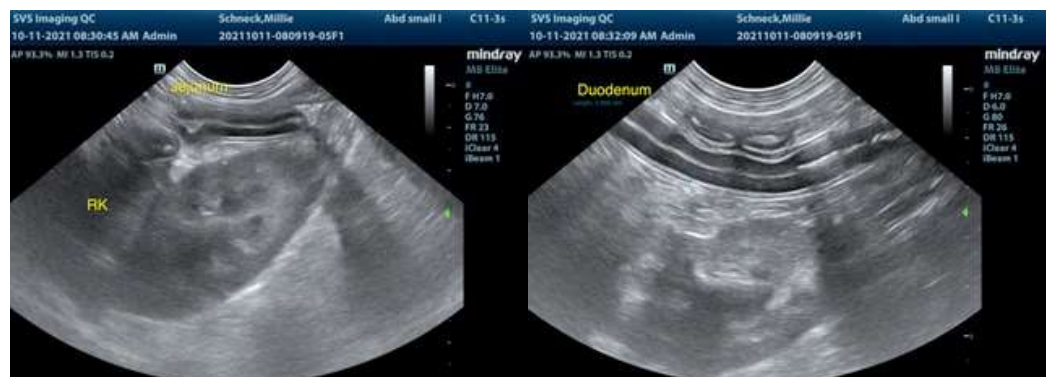**IMAGING PERFORMED BY**

Sarah Pender, CVT

Empirical cobalamin supplementation may be considered if cobalamin levels were normal yet (<400).

**HOSPITAL NAME**

SVS Imaging QC

**REFERRING VET**

Dr. Trammell

**INVOICE**

12389

**DATE**

10/11/21



**PATIENT**

Millie Schneck

**SPECIES**

Canine

**BREED**

Trammell

**SEX**

Spayed Female

**AGE**

7 years

**WEIGHT**

31 lbs.

**INTERPRETED BY**

R. McKenzie Daniel, DVM, DABVP  
(Canine and Feline)

**IMAGING PERFORMED BY**

Sarah Pender, CVT

**HOSPITAL NAME**

SVS Imaging QC

**REFERRING VET**

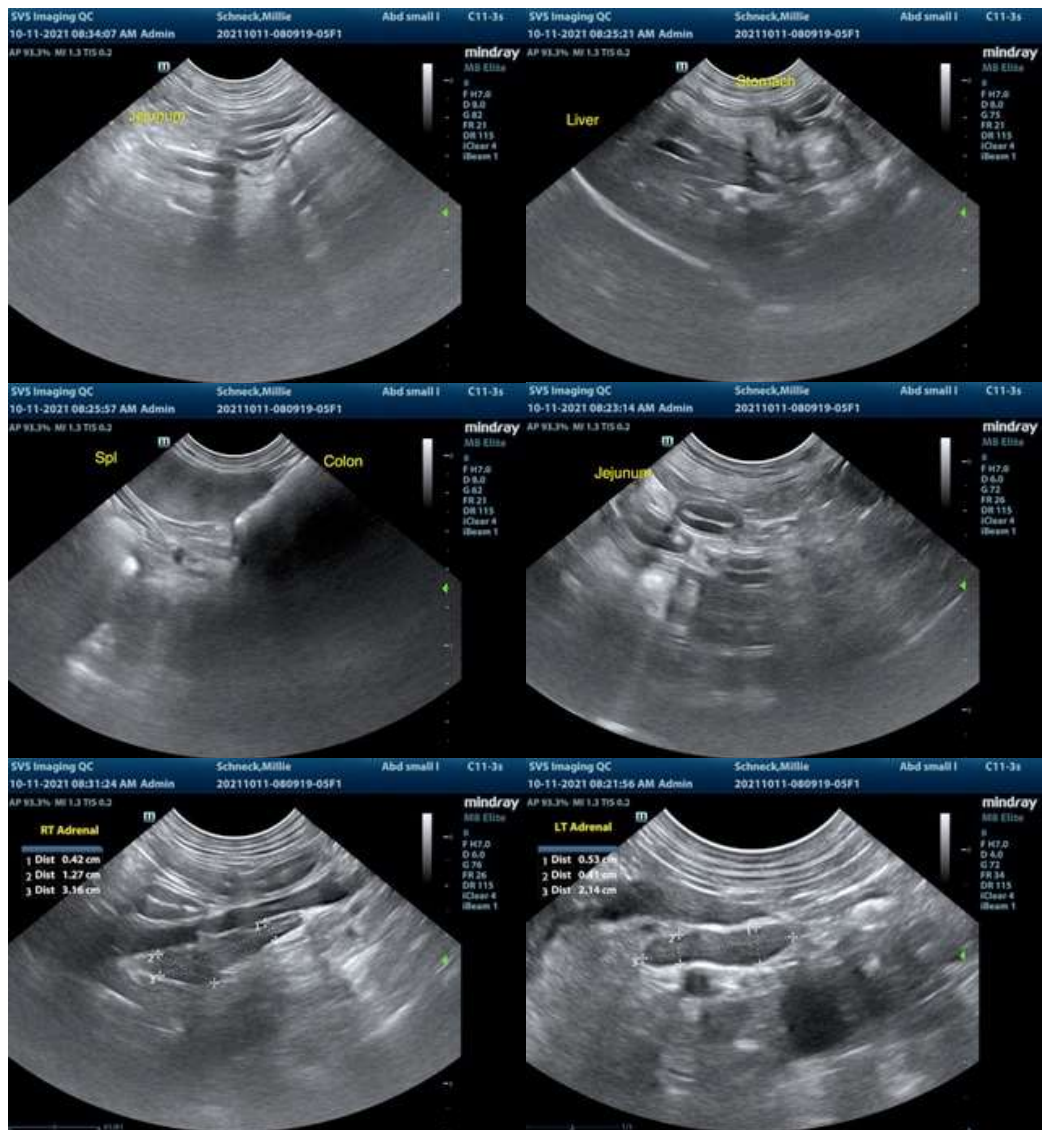
Dr. Trammell

**INVOICE**

12389

**DATE**

10/11/21



The information and recommendations provided are based on the images presented by the referring veterinarian. No evaluation can be communicated regarding pathology that was not visible in the image/video clips provided.

Thank you for this referral. If the clinical or image interpretation does not parallel your findings or if I can be of any further assistance please contact me.

**R. McKenzie Daniel, DVM, DABVP (Canine / Feline Practice)**  
info@SonoPath.com