



PATIENT

Rusty Goff

SPECIES

Canine

BREED

Mixed

SEX

Intact Male

AGE

6 Months

WEIGHT

6.7 pounds

INTERPRETED BY

R. McKenzie Daniel,
DVM, DABVP (Canine
/ Feline Practice)

IMAGING PERFORMED BY

Meghan Morse LVT,
CVT

HOSPITAL NAME

Midland Park
Veterinary Hospital

REFERRING VET

Dr. Shokoff

INVOICE

13060

DATE

01/09/2026

PRESENTING CLINICAL SIGNS

Pre op ECG revealed sinus tachycardia and tall P waves.

Abnormal PE/Chem/CBC/UA Results: ALKP 148, BUN/creat ratio increased (normal individually)

ULTRASONOGRAPHIC EXAMINATION OF THE HEART

CANINE CARDIAC PARAMETERS	MR VMAX (m/s)	TR VMAX (m/s)	LA/AO (M-Mode)	LA/AO (Heart Base; Swe)	FS (%)	EF (%)	EPSS (cm)
NORMAL PARAMETER	4.5-5.5	<2.7	1.3	Up to 1.6	28-40	40-100	<0.6
PATIENT	--	--	NM	1.1	45	78	0.1
CANINE CARDIAC PARAMETERS	HR (BPM)	AV VMAX (m/s)	PV MAX (m/s)	BODY WEIGHT (lbs)	LAD LA MAX 4 Chamber	LVIDd Avg; 2D and m-mode short axis (cm)	LVIDs Avg; 2D and m-mode short axis (cm)
NORMAL PARAMETER	50-100	0.7-1.7	0.7-1.6				
PATIENT	NM	1.4	0.93	6.7	1.5	1.6	--

Cardiac Presentation

The echocardiogram in this patient demonstrated normal **left atrial** dimension based on 2 separate methods of LA evaluation. The cranial and caudal **mitral** valve leaflets presented normal linear structure, extension in systole, and union in diastole with normal kinesis. No evidence of MR on doppler. The **left ventricle** presented thicknesses with linear contour and was not dilated nor restricted. The **myocardium** presented normal echogenicity without subjective evidence of significant fibrotic or ischemic disease. **Contractility** of the ventricular walls was adequate and in normal range for this patient evidenced by the fractional shortening measurement and subjective evaluation of the different regions of the myocardium. The **left ventricular outflow** tract demonstrated normal laminar flow and subjective structural integrity. Normal measured LVOT velocity. The **right atrium** and auricle revealed normal size, structure and content. No evidence of masses was noted. **Tricuspid** valvular assessment demonstrated adequate linear morphology and kinesis. No evidence of TR on doppler. The **right ventricle** was of normal size (1/3 diameter of LV), chordae structure, myocardial echogenicity and thickness. **Pulmonary outflow** tract assessment revealed normal valve structure, laminar flow, and diameter (approx.1:1 pa/ao ratio). Normal measured RVOT velocity. No visible **pericardial** or free pleura fluid was noted. The cranial **mediastinum and pericardial and extra-cardiac regions** were free of masses in the visible window. No evidence of arrhythmia.

ULTRASONOGRAPHIC FINDINGS

- Normal cardiac structure/function.



PATIENT

Rusty Goff

SPECIES

Canine

BREED

Mixed

SEX

Intact Male

AGE

6 Months

WEIGHT

6.7 pounds

INTERPRETED BY

R. McKenzie Daniel, DVM, DABVP (Canine / Feline Practice)

IMAGING PERFORMED BY

Meghan Morse LVT, CVT

HOSPITAL NAME

Midland Park Veterinary Hospital

REFERRING VET

Dr. Shokoff

INVOICE

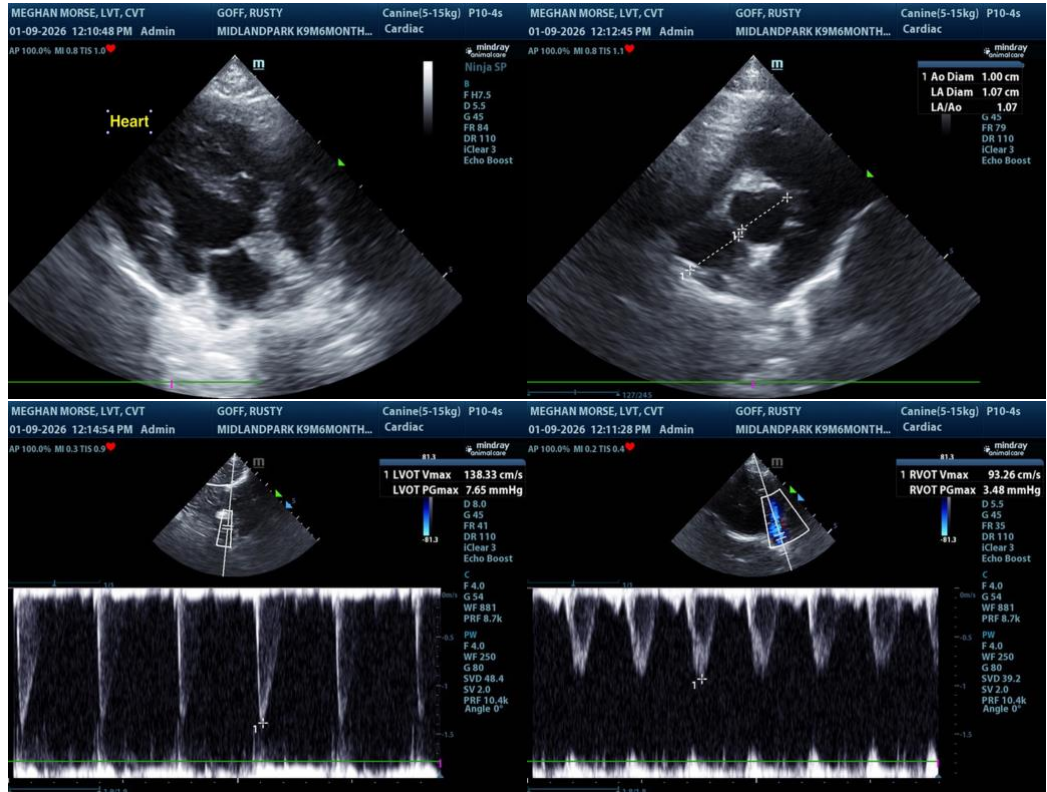
13060

DATE

01/09/2026

INTERPRETATION OF THE FINDINGS & FURTHER RECOMMENDATIONS

No evidence of clinical issues such as left or right heart chamber enlargement, LV systolic dysfunction, valvular insufficiencies, or congenital disease such as stenotic disease, PDA, or other. From a cardiac structural/functional standpoint, no anesthetic contraindications.



The information and recommendations provided are based on the images presented by the referring veterinarian/sonographer. No evaluation can be communicated regarding pathology that was not visible in the image/video clips provided.

Thank you for this referral. If the clinical or image interpretation does not parallel your findings or if I can be of any further assistance, please contact me.

R. McKenzie Daniel, DVM, DABVP (Canine / Feline Practice)

info@SonoPath.com