



PATIENT

Dino Bonilla

PRESENTING CLINICAL SIGNS

HM 3/6 L sided apical. Cataracts and lenticular sclerosis OU gr. 2 dental.

SPECIES

Canine

ULTRASONOGRAPHIC EXAMINATION OF THE HEART

BREED

Shitzu Mix

SEX

M

AGE

14 yr, 9 mon

WEIGHT

14.6 lbs.

CANINE CARDIAC PARAMETERS	MR VMAX (m/s)	TR VMAX (m/s)	LA/AO (M-Mode)	LA/AO (Heart Base; Swe)	FS (%)	EF (%)	EPSS (cm)
NORMAL PARAMETER	4.5-5.5	<2.7	1.3	Up to 1.6	28-40	40-100	<0.6
PATIENT	5.3	<2.0	-	1.25	42	74	0.25
CANINE CARDIAC PARAMETERS	HR (BPM)	AV VMAX (m/s)	PV MAX (m/s)	BODY WEIGHT (lb)	LAD LA MAX4 Chamber	LVIDd Avg; 2D and m-mode short axis (cm)	LVIDs Avg; 2D and m-mode short axis (cm)
NORMAL PARAMETER	50-100	0.7-1.7	0.7-1.6				
PATIENT	NM	1.0	0.9	14.6	2.6	2.3	-

INTERPRETED BY

R. McKenzie Daniel,
 DVM, DABVP
 (Canine and Feline)

Cardiac Presentation

The echocardiogram in this patient demonstrated normal **left atrial** size based on 2 different LA measurement methods. Chamber volumes and echogenicity were normal. The cranial and caudal **mitral** valve leaflets presented thickening consistent with endocardiosis with mild valvular prolapse. Doppler indicated measurable moderate eccentric insufficiency (MR velocity 5.3 m/s). The **left ventricle** presented thicknesses with linear contour and was not dilated nor restricted. The **myocardium** presented normal echogenicity without subjective evidence of significant fibrotic or ischemic disease. **Contractility** of the ventricular walls was adequate and in normal range for this patient evidenced by the fractional shortening measurement and subjective evaluation of the different regions of the myocardium. The **left ventricular outflow** tract demonstrated normal laminar flow and subjective structural integrity. The **right atrium** and auricle revealed normal size, structure and content. No evidence of masses was noted or chamber overload. **Tricuspid** valvular assessment demonstrated mild thickening with mild TR on Doppler (measured TR velocity <2.0 m/s). The **right ventricle** was of normal size (1/3 diameter of LV), chordae structure, myocardial echogenicity and thickness. **Pulmonic** tract assessment revealed normal valve structure, laminar flow, and diameter (approx.1:1 pa/ao ratio). No visible **pericardial** or free pleura fluid was noted. No echographically detectable evidence of cardiac / pericardial tumors was visible.

IMAGING PERFORMED BY

Kerri Becker

HOSPITAL NAME

Vetco Totowa

REFERRING VET

Dr. Tuttman

INVOICE

10537

DATE

1/8/26



PATIENT

Dino Bonilla

SPECIES

Canine

BREED

Shitzu Mix

SEX

M

AGE

14 yr, 9 mon

WEIGHT

14.6 lbs.

INTERPRETED BY

R. McKenzie Daniel,
 DVM, DABVP
 (Canine and Feline)

IMAGING PERFORMED BY

Kerri Becker

HOSPITAL NAME

Vetco Totowa

REFERRING VET

Dr. Tuttmann

INVOICE

10537

DATE

1/8/26

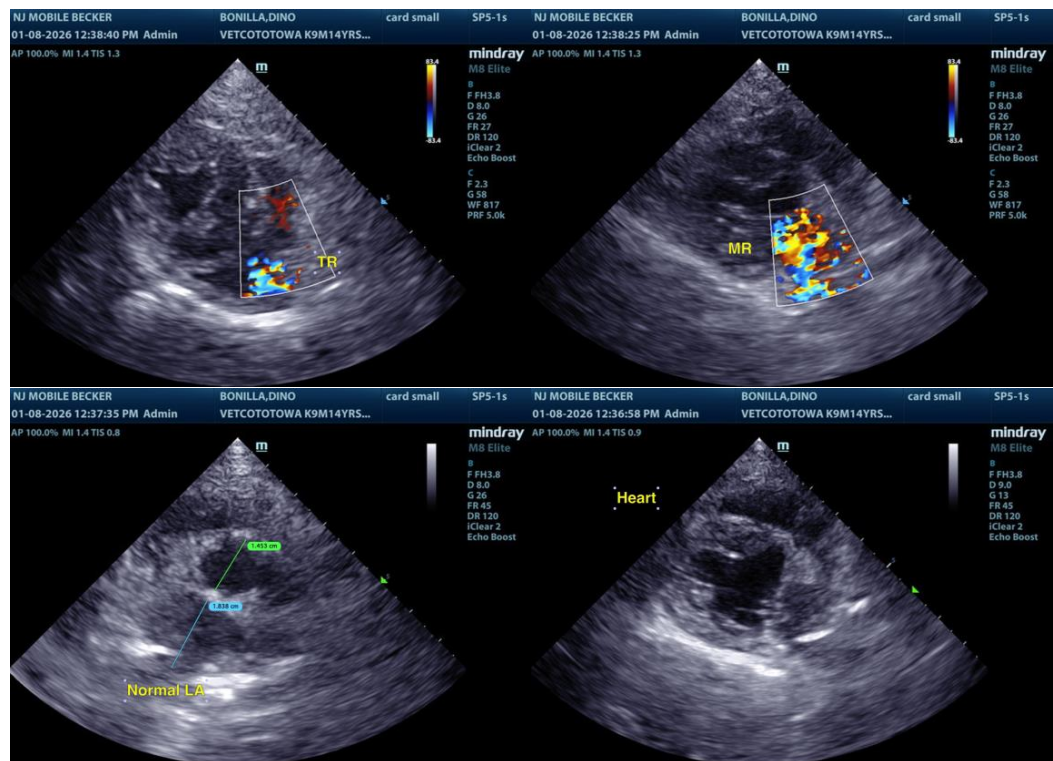
ULTRASONOGRAPHIC FINDINGS

- Chronic mitral valve disease with mild valvular prolapse (B1)
- Mild TR – no evidence of pulmonary hypertension

INTERPRETATION OF THE FINDINGS & FURTHER RECOMMENDATIONS

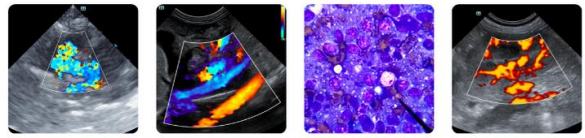
The cause of the murmur is chronic degenerative valvular changes with secondary eccentric mitral valve insufficiency. The lack of left atrial enlargement implies that the risk of complications secondary to mitral valve insufficiency is low at this time and, without current clinical signs, indicates that medical therapy is not required. Prognosis is considered variable and sonographic monitoring is recommended. Recheck echocardiogram is suggested in 6-12 months, sooner if clinical signs arise. Anesthetic risk is considered mild.

If required, the suggested anesthetic protocol may include opioid or Benzodiazepine pre-med, induction with Propofol or Alfaxalone, and appropriate gas anesthesia with avoidance of alpha 2 agonists.



The information and recommendations provided are based on the images presented by the referring veterinarian/sonographer. No evaluation can be communicated regarding pathology that was not visible in the image/video clips provided.

Thank you for this referral. If the clinical or image interpretation does not parallel your findings or if I can be of any further assistance, please contact me.



PATIENT

Dino Bonilla

R. McKenzie Daniel, DVM, DABVP (Canine / Feline Practice)
info@sonopath.com

SPECIES

Canine

BREED

Shitzu Mix

SEX

M

AGE

14 yr, 9 mon

WEIGHT

14.6 lbs.

INTERPRETED BY

R. McKenzie Daniel,
DVM, DABVP
(Canine and Feline)

**IMAGING
PERFORMED BY**

Kerri Becker

HOSPITAL NAME

Vetco Totowa

REFERRING VET

Dr. Tuttman

INVOICE

10537

DATE

1/8/26