



PATIENT

Lux Pimentel

SPECIES

Canine

BREED

Yorkie

SEX

Spayed Female

AGE

13 Years 8 Months

WEIGHT

6.1 pounds

INTERPRETED BY

R. McKenzie Daniel,
DVM, DABVP (Canine
/ Feline Practice)

IMAGING PERFORMED BY

Kerri Becker

HOSPITAL NAME

Animal Paradise
Hospital

REFERRING VET

Dr. Elshafie

INVOICE

13003

DATE

01/07/2026

PRESENTING CLINICAL SIGNS

Assess heart after ER visit and starting on medication. 4/6 HM HX CHF Meds- Vetmedin, Lasix

Abnormal PE/Chem/CBC/UA Results: ALP-194 BUN-43 Cre-1.6 Glu-12 CBC-WNL

ULTRASONOGRAPHIC EXAMINATION OF THE HEART

CANINE CARDIAC PARAMETERS	MR VMAX (m/s)	TR VMAX (m/s)	LA/AO (M-Mode)	LA/AO (Heart Base; Swe)	FS (%)	EF (%)	EPSS (cm)
NORMAL PARAMETER	4.5-5.5	<2.7	1.3	Up to 1.6	28-40	40-100	<0.6
PATIENT	5.6	--	NM	1.55	47	80	0.2
CANINE CARDIAC PARAMETERS	HR (BPM)	AV VMAX (m/s)	PV MAX (m/s)	BODY WEIGHT (kg)	LAD LA MAX 4 Chamber	LVIDd Avg; 2D and m-mode short axis (cm)	LVIDs Avg; 2D and m-mode short axis (cm)
NORMAL PARAMETER	50-100	0.7-1.7	0.7-1.6				
PATIENT	NM	1.1	1.0	--	2.2	2.5	--

Cardiac Presentation

The echocardiogram in this patient demonstrated mild to moderate increased **left atrial** dimension based on 2 different LA measurement methods. The cranial and caudal **mitral** valve leaflets presented thickening consistent with endocardiosis. No overt valvular prolapse or chordate tendon rupture. Doppler revealed significant eccentric MR. The **left ventricle** presented mild increased dimension with linear contour and was not dilated nor restricted. The **myocardium** presented normal echogenicity without subjective evidence of significant fibrotic or ischemic disease. **Contractility** of the ventricular walls was adequate and in normal range for this patient evidenced by the fractional shortening measurement and subjective evaluation of the different regions of the myocardium. The **left ventricular outflow** tract demonstrated normal laminar flow and subjective structural integrity. The **right atrium** and auricle revealed normal size, structure and content. No evidence of masses was noted or chamber overload. **Tricuspid** valvular assessment demonstrated adequate linear morphology. The **right ventricle** was of normal size (1/3 diameter of LV), chordae structure, myocardial echogenicity and thickness. **Pulmonic** tract assessment revealed normal valve structure, laminar flow, and diameter (approx.1:1 pa/ao ratio). No visible **pericardial** or free pleura fluid was noted. No echographically detectable evidence of cardiac / pericardial tumors was visible. No overt arrhythmia.

ULTRASONOGRAPHIC FINDINGS

- Chronic mitral valve disease (B2).

INTERPRETATION OF THE FINDINGS & FURTHER RECOMMENDATIONS



PATIENT

Lux Pimentel

SPECIES

Canine

BREED

Yorkie

SEX

Spayed Female

AGE

13 Years 8 Months

WEIGHT

6.1 pounds

INTERPRETED BY

R. McKenzie Daniel,
 DVM, DABVP (Canine
 / Feline Practice)

**IMAGING
 PERFORMED BY**

Kerri Becker

HOSPITAL NAME

Animal Paradise
 Hospital

REFERRING VET

Dr. Elshafie

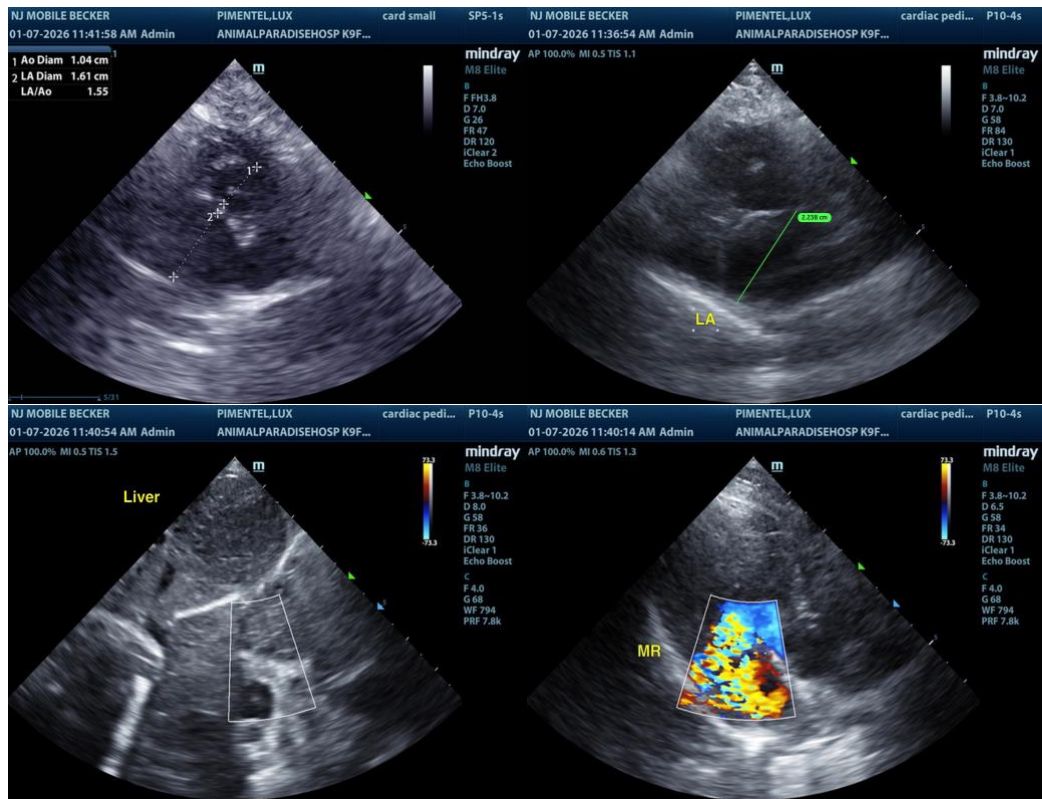
INVOICE

13003

DATE

01/07/2026

Given evidence of mild to moderate increased LA dimension, Vetmedin 0.30 mg/kg PO BID is warranted. Diuretic therapy is indicated if evidence of cardiogenic pulmonary edema at lowest effective dose with concurrent monitoring of renal parameters. Subjectively, the degree of LA enlargement was not definitively consistent with congestive criteria yet may be possible. No additional clinical issues such as arrhythmia or evidence of clinical pulmonary hypertension. Sonographic monitoring is advised for further assessment and prognosis. Recheck echo is suggested in 6 months or sooner if progressive clinical signs. Baseline monitoring of resting respiration rate going forward is recommended. Anesthetic risk is considered moderate. If required, the following protocol is suggested with close clinical monitoring. Suggested anesthetic protocol may include opioid or Benzodiazepine pre-med, induction with Propofol or Alfaxalone, and appropriate gas anesthesia with avoidance of alpha 2 agonists.



The information and recommendations provided are based on the images presented by the referring veterinarian/sonographer. No evaluation can be communicated regarding pathology that was not visible in the image/video clips provided.

Thank you for this referral. If the clinical or image interpretation does not parallel your findings or if I can be of any further assistance, please contact me.

R. McKenzie Daniel, DVM, DABVP (Canine / Feline Practice)

info@SonoPath.com