



PATIENT

Bula Essex

PRESENTING CLINICAL SIGNS

MCT staging, grade 2 murmur (left sided) high HR, murmur not heard at low HR

SPECIES

Canine

BREED

Mixed Terrier

SEX

FS

AGE

10yr

WEIGHT

12.1kg

ULTRASONOGRAPHIC EXAMINATION OF THE ABDOMEN AND HEART

CANINE CARDIAC PARAMETERS	MR VMAX (m/s)	TR VMAX (m/s)	LA/AO M-mode	LA/AO (Heart Base; Swe)	FS (%)	EF (%)	EPSS (cm)
NORMAL PARAMETER	4.5-5.5	<2.7	1.3	Up to 1.6	28-40	40-100	<0.6
PATIENT	--	--	--	1.12	35	66	0.27
CANINE CARDIAC PARAMETERS	HR (BPM)	AV VMAX (m/s)	PV MAX (m/s)	BODY WEIGHT (kg)	LAD LA MAX 4 Chamber	LVIDd Avg; 2D and m-mode short axis (cm)	LVIDs Avg; 2D and m-mode short axis (cm)
NORMAL PARAMETER	50-100	0.7-1.7	0.7-1.6				
PATIENT	--	1.4	0.72	--	3.2	3.1	--

Cardiac Presentation

The echocardiogram in this patient demonstrated normal left atrial size based on 2 separate methods of LA evaluation. The cranial and caudal mitral valve leaflets presented normal linear structure, extension in systole, and union in diastole with normal kinesis. Minor eccentric MR on Doppler. The left ventricle presented thicknesses with linear contour and was not dilated nor restricted. The myocardium presented normal echogenicity without subjective evidence of significant fibrotic or ischemic disease. Contractility of the ventricular walls was adequate and in normal range for this patient evidenced by the fractional shortening measurement and subjective evaluation of the different regions of the myocardium. The left ventricular outflow tract demonstrated normal laminar flow and subjective structural integrity. Normal measured LVOT velocity. The right atrium and auricle revealed normal size, structure and content. No evidence of masses was noted. Tricuspid valvular assessment demonstrated adequate linear morphology and kinesis. No overt TR on Doppler. The right ventricle was of normal size (1/3 diameter of LV), chordae structure, myocardial echogenicity and thickness. Pulmonary outflow tract assessment revealed normal valve structure, laminar flow, and diameter (approx.1:1 pa/ao ratio). Trace pulmonic insufficiency present on Doppler. No visible pericardial or free pleural fluid was noted. The cranial mediastinum and pericardial and extra-cardiac regions were free of masses in the visible window.

Urinary System

The urinary bladder, trigone, cystourethral junction, and visible pelvic urethra to a depth of 4 cm exhibited normal thickness and tone. Anechoic urine was present in the lumen with no evidence of

INTERPRETED BY

R. McKenzie Daniel, DVM, DABVP (Canine and Feline)

IMAGING PERFORMED BY

Dr. Judy McFarlen

HOSPITAL NAME

Westview Veterinary Hospital

REFERRING VET

Dr. Judy McFarlen

INVOICE
23489

DATE
01/07/2026



PATIENT

Bula Essex

SPECIES

Canine

BREED

Mixed Terrier

SEX

FS

AGE

10yr

WEIGHT

12.1kg

INTERPRETED BY

R. McKenzie Daniel,
DVM, DABVP
(Canine and Feline)

IMAGING PERFORMED BY

Dr. Judy McFarlen

HOSPITAL NAME

Westview Veterinary
Hospital

REFERRING VET

Dr. Judy McFarlen

INVOICE 23489

DATE

01/07/2026

urine/lumen sediment, mineral, or calculi. The ureteral papillae were normal. The ureters were not visible which is normal. No evidence of inflammatory or neoplastic changes was noted.

Normal size and margination were present in the kidneys. A normal 1:3 cortex / medulla ratio was maintained. The medulla and cortices were uniform in texture with some increased echogenicity and mild loss of corticomedullary symmetry and definition expected for the age of the patient. No evidence of pelvic dilation was present. The left kidney measured 5.1 cm in length. The right kidney measured 5.5 cm in length.

The area of the iliac trifurcation was free of pathology including no evidence of medial iliac or sublumbar lymphadenopathy or masses.

The area of the residual prostate appeared normal and free of pathology

Adrenal Glands

The left adrenal gland was uniform in size and contour with a uniformly hypoechoic parenchyma. The left adrenal gland measured 0.5 cm width at the caudal pole. The right adrenal gland was uniform in size and contour with a uniformly hypoechoic parenchyma. The right adrenal gland measured 0.56 cm width at the caudal pole.

Spleen

The spleen exhibited a finely textured and homogenous parenchyma which was hyperechoic to the liver and renal cortical parenchyma. The capsule was smooth and regular without apparent expansion. The splenic vasculature at the hilus was normal in volume with no evidence of congestion or thrombosis. Acute to chronic inflammatory, neoplastic, or benign parenchyma changes were not noted.

Liver/Gallbladder

The liver was subjectively normal in size, structure, and contour. The liver parenchyma was uniform and hypoechoic to the spleen with a mild coarse echotexture. Normal vascular volume. The hepatic and portal vasculature were normal in appearance without signs of congestion. The gallbladder was non-distended in size with thin walls and primarily anechoic luminal content. The cystic and common bile ducts were normal.

Gastrointestinal

The stomach presented intact wall layering with a normal wall layer ratio. The lumen of the stomach was empty with no signs of ileus, obstruction or foreign material.

The small intestine presented intact wall layering with 1:3 muscularis/mucosa ratio. The lumen of the small intestine was empty with no signs of mechanical/metabolic ileus, obstruction or foreign material.

Normal visible colon wall layers were present with apparent formed feces in lumen.

Pancreas

The parenchyma of the left limb, body and right limb of the pancreas presented isoechoic to the adjacent omental fat. A normal curvilinear capsule contour of the pancreas was present. The visible pancreatic duct was normal. No signs of active inflammation or neoplastic disease was evident.



PATIENT

Free Abdomen

Bula Essex

No omental masses, overt lymphadenopathy or peritoneal effusion was present.

SPECIES

Canine

BREED

Mixed Terrier

Primary

- Mild MR (B1)
- Trace pulmonic insufficiency-not considered hemodynamically significant
- Age-related renal changes with left kidney cortical cyst
- Sonographically normal spleen.
- Non-organized gallbladder debris.

SEX

FS

INTERPRETATION OF THE FINDINGS & FURTHER RECOMMENDATIONS

Incidental murmur owing to mitral valve insufficiency is suspected if murmur is not consistently heard. Regardless of classification, the hemodynamic effects of the murmur are low. No indication for cardiac medication. Conservative monitoring for recurrent or persistent murmur is recommended. Recheck echocardiogram as needed is suggested.

AGE

10yr

Largely a geriatric abdomen without evidence of significant visceral pathology. No evidence of neoplastic or metastatic criteria. Correlation with lab work recommended with hepatosupportive medication /ursodiol if evidence of cholestasis.

WEIGHT

12.1kg

INTERPRETED BY

R. McKenzie Daniel,
DVM, DABVP
(Canine and Feline)

IMAGING PERFORMED BY

Dr. Judy McFarlen

HOSPITAL NAME

Westview Veterinary
Hospital

REFERRING VET

Dr. Judy McFarlen

INVOICE

23489

DATE

01/07/2026



PATIENT

Bula Essex

SPECIES

Canine

BREED

Mixed Terrier

SEX

FS

AGE

10yr

WEIGHT

12.1kg

INTERPRETED BY

R. McKenzie Daniel,
DVM, DABVP
(Canine and Feline)

IMAGING PERFORMED BY

Dr. Judy McFarlen

HOSPITAL NAME

Westview Veterinary
Hospital

REFERRING VET

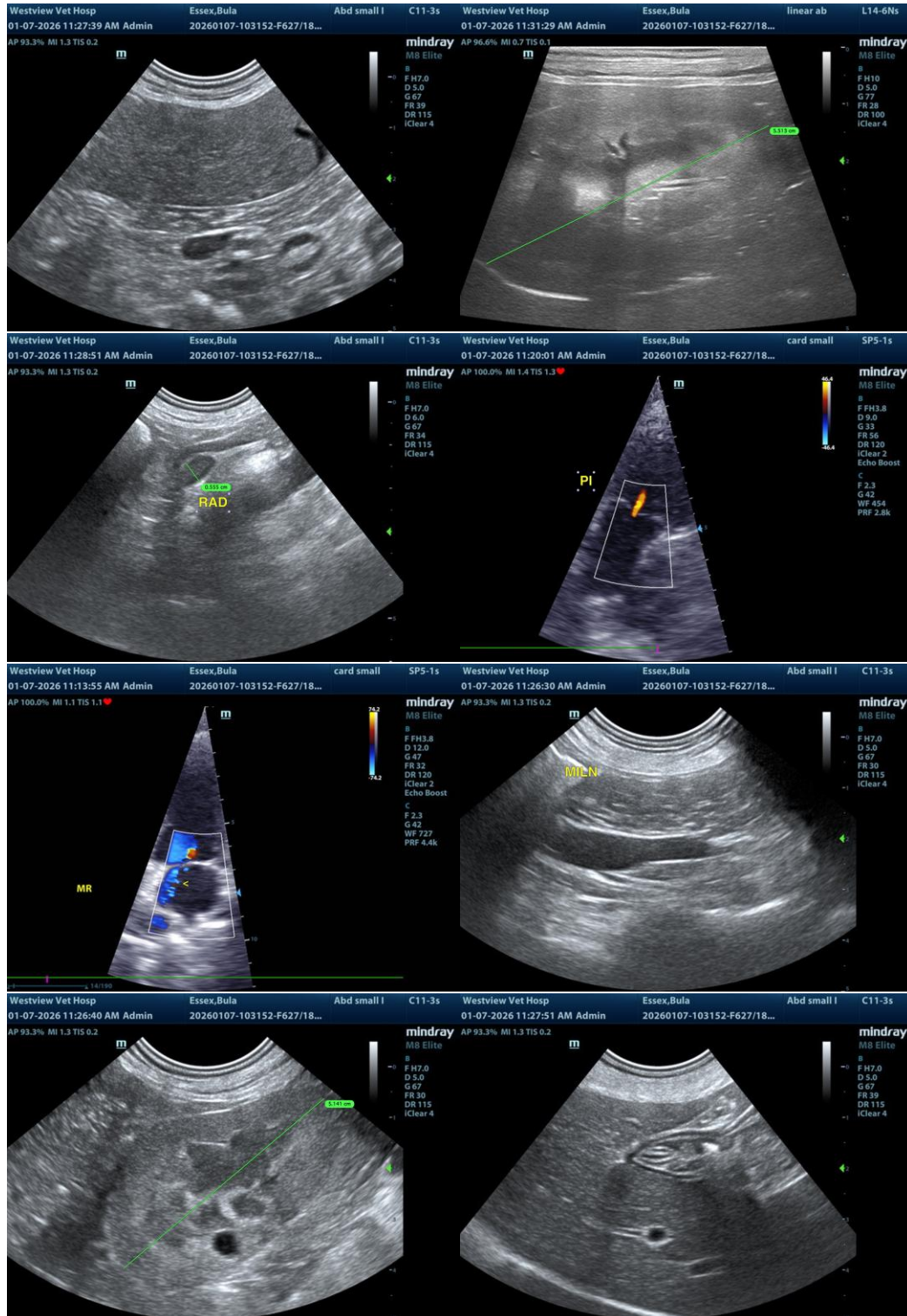
Dr. Judy McFarlen

INVOICE

23489

DATE

01/07/2026





PATIENT

Bula Essex

SPECIES

Canine

BREED

Mixed Terrier

SEX

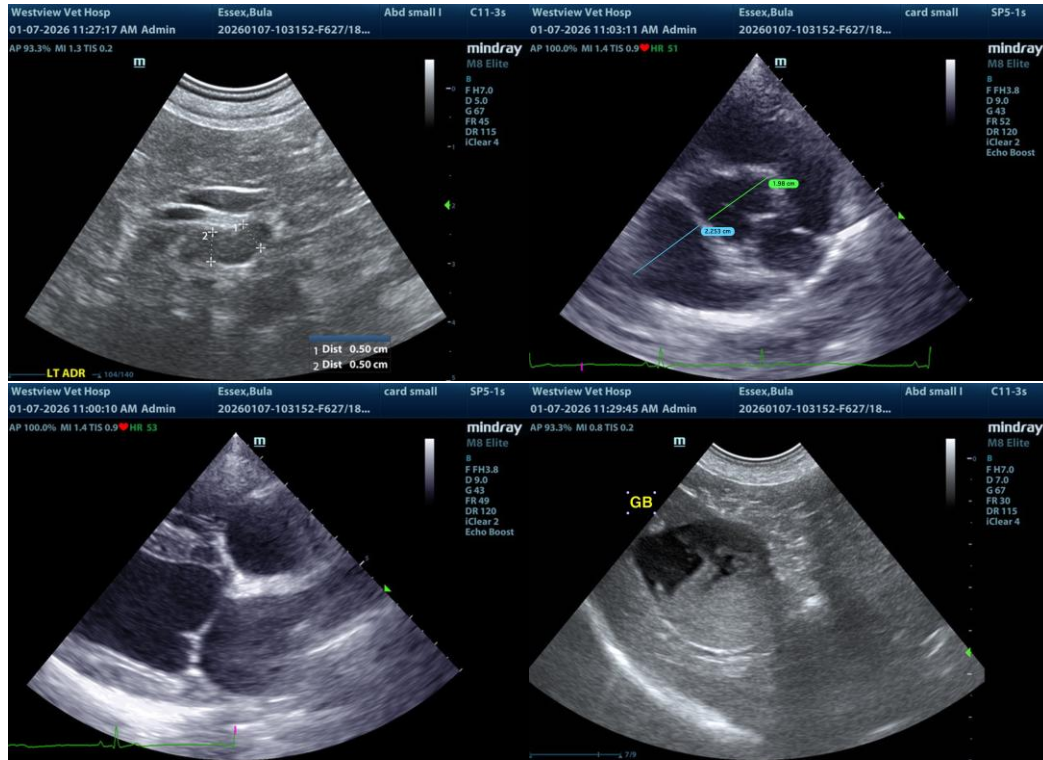
FS

AGE

10yr

WEIGHT

12.1kg



INTERPRETED BY

R. McKenzie Daniel,
DVM, DABVP
(Canine and Feline)

IMAGING PERFORMED BY

Dr. Judy McFarlen

HOSPITAL NAME

Westview Veterinary
Hospital

REFERRING VET

Dr. Judy McFarlen

INVOICE

23489

DATE

01/07/2026

The information and recommendations provided are based on the images presented by the referring veterinarian/sonographer. No evaluation can be communicated regarding pathology that was not visible in the image/video clips provided.

Thank you for this referral. If the clinical or image interpretation does not parallel your findings or if I can be of any further assistance, please contact me.

R. McKenzie Daniel, DVM, DABVP (Canine/Feline Practice)
info@sonopath.com