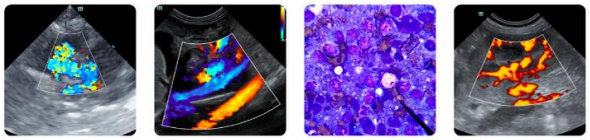

PATIENT
Jet Christiansen

SPECIES
Feline

BREED
Domestic Shorthair

SEX
Male, Neutered

AGE
9

WEIGHT
6.4 kg

INTERPRETED BY
R. McKenzie Daniel, DVM, DABVP (Canine and Feline)

IMAGING PERFORMED BY
Dr. Rachel Gray

HOSPITAL NAME
Wilvet Salem

REFERRING VET
Dr. Rachel Gray

INVOICE
10497

DATE
1/6/25

PRESENTING CLINICAL SIGNS

Pet has not been eating for approx 1 week. Pt presented to rDVM this afternoon for runny, loose stools with small drops of blood. Open mouth breathing on the way to RDVM. Pt has not had any interest in food for 7 days but will lick wet food. Pt has had dental extractions in the past with oral ulcerations- improved today without obvious oral pathology. Historic vomiting 1-2x/month, diarrhea 1-2x/month.

Abnormal PE/Chem/CBC/UA Results: Pet was transferred with low potassium at 3.1, AlkP at 461, Alt at 480, tbili at 7.7 Pet was transferred to Wilvet and hospitalized with NG tube and a plan to place an E tube after stabilized.

ULTRASONOGRAPHIC EXAMINATION OF THE ABDOMEN

Urinary System

The urinary bladder, trigone, and cystourethral junction exhibited normal thickness and tone. Primarily anechoic urine was present in the lumen. Mild, nondependent, particulate sediment was present without evidence of calculus formation. The ureteral papillae were normal. The ureters were not visible which is normal. No evidence of inflammatory or neoplastic mural changes were noted.

No evidence of pathology in the area of the aortic trifurcation.

Normal size and margination were present in the kidneys. A normal 1:3 cortex / medulla ratio and normal corticomedullary definition were maintained. The echogenicity of the cortex was similar to or slightly less than normal liver parenchyma while the medulla echogenicity was hypoechoic to the cortex with no evidence of pelvic dilation. The left kidney measured 4.3 cm in length. The right kidney measured 4.4 cm in length.

Adrenal Glands

No overt pathology was noted in the area of the left or right adrenal glands.

Spleen

The spleen was enlarged in size, exhibiting a finely textured and homogenous parenchyma which was hyperechoic to the liver and renal cortical parenchyma. The capsule was smooth and regular without apparent expansion. The splenic vasculature at the hilus was normal in volume with no evidence of congestion or thrombosis. Acute to chronic inflammatory, neoplastic, or benign parenchyma changes were not noted. The spleen measured 1.3 cm width at the level of the mid spleen.

Liver/ Gallbladder

The liver was subjectively mildly enlarged in size. The parenchyma of the liver exhibited mild nonhomogeneous increased in echogenicity compared to the spleen. There were no visualized splenic masses or nodules. The echotexture of the liver parenchyma was uniform with a mild coarse echotexture. The capsule of the liver was symmetrical in margination. The hepatic and portal vasculature were normal

PATIENT
Jet Christiansen

SPECIES
Feline

BREED
Domestic Shorthair

SEX
Male, Neutered

AGE
9

WEIGHT
6.4 kg

INTERPRETED BY
R. McKenzie Daniel, DVM, DABVP (Canine and Feline)

IMAGING PERFORMED BY
Dr. Rachel Gray

HOSPITAL NAME
Wilvet Salem

REFERRING VET
Dr. Rachel Gray

INVOICE
10497

DATE
1/6/25

in appearance without signs of congestion. The gallbladder was non-distended in size containing primarily anechoic content with mild, nonorganized gallbladder debris. The common bile duct was not definitively visualized.

Gastrointestinal

The stomach presented intact wall layering with a normal wall layer ratio. The lumen of the stomach was empty without evidence of retained ingesta or foreign material. Mild retained gastric fluid was noted. There was no evidence of obstruction to pyloric outflow.

The intestinal walls demonstrated intact wall layers with mildly thickened walls and mild altered wall ratio, primarily consisting of a mildly thickened intestinal muscularis layer. The duodenum wall measured 0.30 cm width. The jejunum wall width measured 0.30 cm.

Normal visible colon wall layers were present with semi-formed fecal matter.

Pancreas

The parenchyma of the left limb, body, and right limb of the pancreas presented isoechoic to the adjacent omental fat. A normal curvilinear capsule contour of the pancreas was present. The visible pancreatic duct was normal. No signs of active inflammation or neoplastic disease were evident.

Free Abdomen

No obvious significant omental lymphadenopathy was visualized. No evidence of peritoneal effusion was present.

ULTRASONOGRAPHIC FINDINGS

- Mild splenomegaly
- Hepatopathy
- Gallbladder debris
- Normal area of pancreas
- Mild nonobstructive hypomotile stomach
- Intact mildly thickened small intestine wall
- Semi-formed fecal matter in colon

INTERPRETATION OF THE FINDINGS & FURTHER RECOMMENDATIONS

IBD or other inflammatory enteropathy, hepatobiliary inflammation, lipidosis, splenomegaly secondary to sedation, hyperplasia, hematopoiesis, or splenitis with potential for emerging multi-focal round cell neoplasia are all potentials. There is no sonographic evidence of pancreatitis, although mild pancreatitis may present as sonographically normal. A GI panel to include PLI/TLI/Cobalamin/Folate is recommended. There is no evidence of post hepatic or mechanical gastrointestinal obstruction.

SonoPath

FOSTERING THE ART OF VETERINARY MEDICINE™

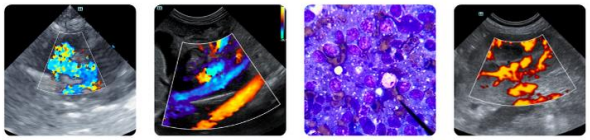

Clinical Sonography & Telecytology

Educational Teleconsultation Services™

SonoPath.com *info@sonopath.com* *1.800.838.4268*

PATIENT

Jet Christiansen

SPECIES

Feline

BREED

Domestic Shorthair

SEX

Male, Neutered

AGE

9

WEIGHT

6.4 kg

INTERPRETED BY

R. McKenzie Daniel, DVM, DABVP (Canine and Feline)

IMAGING PERFORMED BY

Dr. Rachel Gray

HOSPITAL NAME

Wilvet Salem

REFERRING VET

Dr. Rachel Gray

INVOICE

10497

DATE

1/6/25

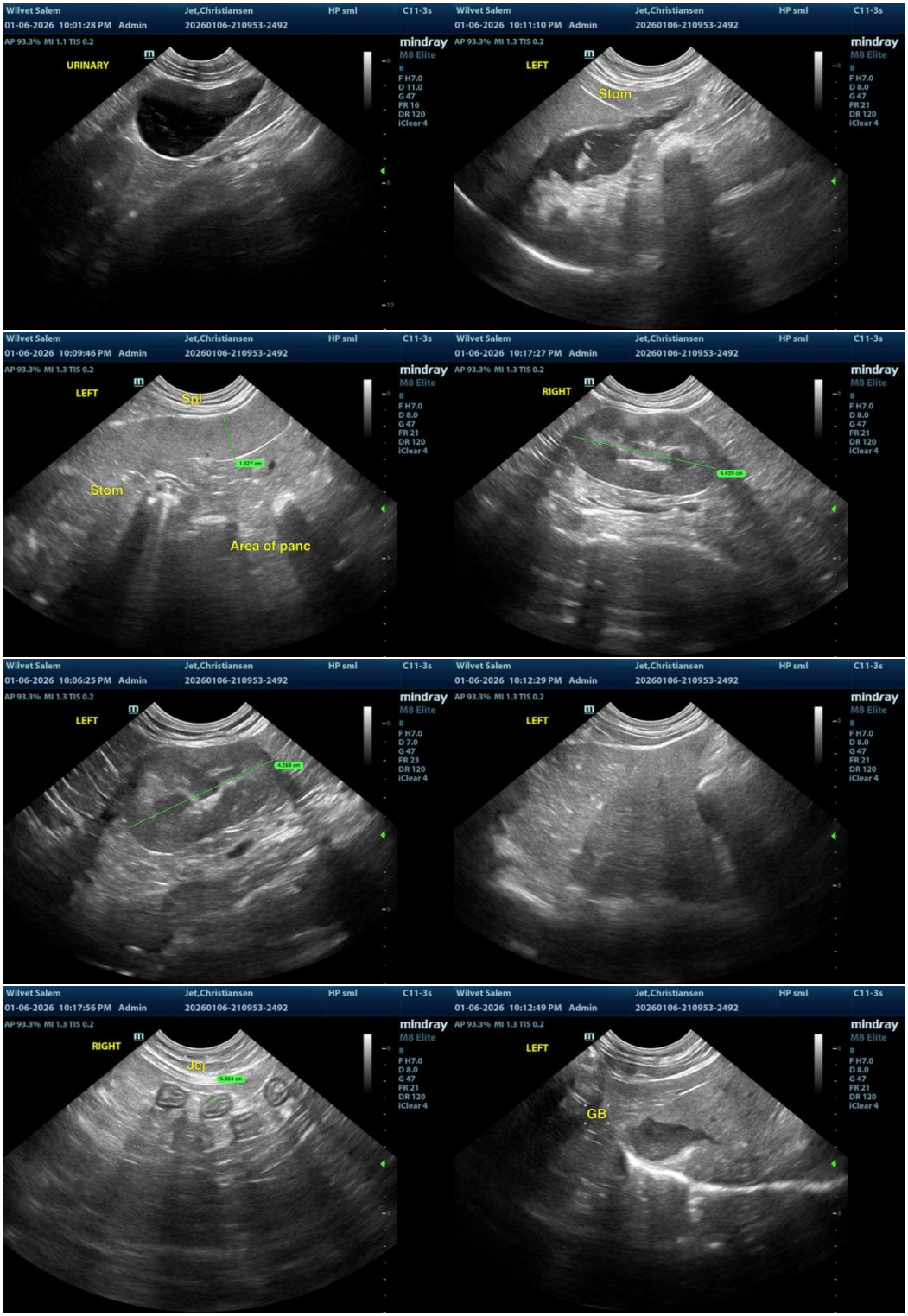

PATIENT

Jet Christiansen

SPECIES

Feline

BREED

Domestic Shorthair

SEX

Male, Neutered

AGE

9

WEIGHT

6.4 kg

INTERPRETED BY

R. McKenzie Daniel, DVM, DABVP (Canine and Feline)

IMAGING PERFORMED BY

Dr. Rachel Gray

HOSPITAL NAME

Wilvet Salem

REFERRING VET

Dr. Rachel Gray

INVOICE

10497

DATE

1/6/25

The information and recommendations provided are based on the images presented by the referring veterinarian/sonographer. No evaluation can be communicated regarding pathology that was not visible in the image/video clips provided.

Thank you for this referral. If the clinical or image interpretation does not parallel your findings or if I can be of any further assistance, please contact me.

R. McKenzie Daniel, DVM, DABVP (Canine/Feline Practice)
info@sonopath.com