



**PATIENT**

Oskar Field

**SPECIES**

Canine

**BREED**

Boxer

**SEX**

Neutered Male

**AGE**

10 Years

**WEIGHT**

81.6 Pounds

**INTERPRETED BY**

R. McKenzie Daniel,  
DVM, DABVP  
(Canine and Feline)

**IMAGING  
PERFORMED BY**

Amy Mayhew, LVT

**HOSPITAL NAME**

SVS Imaging MI

**REFERRING VET**

Dr. Kupraszewicz-  
Bell VC

**INVOICE**

20398

**DATE**

1/5/23

**PRESENTING CLINICAL SIGNS**

History: Lethargy, decreased appetite, diarrhea. P as had a decreased appetite, will skip meals. Drinking a lot more than usual. Seems reactive to stomach when O tries to feel it. Has been pacing a lot. Had a solid stool today but has otherwise been runny. No dietary changes.

Abnormal PE/Chem/CBC/UA Results: Radiographs- One population of intestines. No dilation or plication noted. Liver appears small. Gastric axis cranially (to the left). No masses or fluid noted. No bony changes noted. Mild bronchointerstitial pattern noted. VHS 10.5. \ CBC/Chem- NEU 15.35, TP 8, Glob 4.5, Chol 351, ALP 146, Amylase 2313, Lipase 293

**ULTRASONOGRAPHIC EXAMINATION OF THE ABDOMEN**

**Urinary System**

The urinary bladder was nondistended. Anechoic urine was present in the lumen with no calculi or sediment. No evidence of inflammatory or neoplastic changes were noted. Suspect mild ventral displacement of the urinary bladder neck, proximal urethra and residual prostate secondary to the undifferentiated mass. The residual prostate was overtly normal, measuring 1.1 cm in diameter. Peripheral mild hyperechoic omentum was noted around the mass, along with evidence of intermittent scant free fluid.

The right kidney was mildly prominent in size compared to the left with maintained symmetrical renal margination. Severe hydronephrosis was noted, exhibited by replacement of discernable medullary parenchyma with anechoic fluid. Intact cortex parenchyma was noted. Evidence of significant right hydroureter exiting the right kidney was present, along with mild distal right hydroureter at the level of the ureteral papilla with suspect distal right ureter luminal soft tissue echo at the level of the right ureteral papilla. Distal right ureter measured 1.0 cm in diameter. The right kidney measured 9.0 cm in length.

Normal size and margination were present in the left kidney. A normal 1:3 cortex / medulla ratio was maintained. The medulla and cortices were uniform in texture with some increased echogenicity and loss of corticomodullary symmetry and definition expected for the age of the patient. No evidence of pelvic dilation was present. The left kidney measured 7.6 cm in length.

**Adrenal Glands**

The left adrenal gland was uniform in size and contour with a uniformly hypoechoic parenchyma. The left adrenal gland measured 0.73 cm width at the caudal pole.

The right adrenal gland was uniform in size and contour with a uniformly hypoechoic parenchyma. The right adrenal gland measured 0.63 cm width at the caudal pole.

**Spleen**

The spleen exhibited a finely textured and homogenous parenchyma which was hyperechoic to the liver and renal cortical parenchyma. The capsule was smooth and regular without apparent expansion. The splenic vasculature at the hilus was normal in volume with no evidence of congestion or thrombosis. Acute to chronic inflammatory, neoplastic, or benign parenchyma changes were not noted.

**Liver**

The liver was subjectively normal in size, structure, and contour. The liver parenchyma was mildly nonuniform and hypoechoic to the spleen with a moderate coarse echotexture and subjective mild to



**PATIENT** benign parenchymal remodeling. The hepatic and portal vasculature were normal in appearance without signs of congestion.

Oskar Field

The gallbladder was non-distended in size anechoic content and mild nonorganized echogenic sludge. No evidence of gallbladder or peripheral gallbladder inflammation. The cystic and common bile ducts were normal.

**SPECIES**

Canine

***Gastrointestinal***

**BREED**

The visualized gastric walls were sonographically normal. The lumen of the stomach contained moderate variably echogenic to progressively shadowing ingesta.

Boxer

The small intestine presented intact wall layering with 1:3 muscularis/mucosa ratio. Minor segmental nonshadowing intestinal ingesta/chyme was present.

**SEX**

Neutered Male

Normal visible colon wall layers were present with apparent formed feces in lumen.

***Pancreas***

**AGE**

10 Years

The pancreas was indistinctly visualized yet without overt evidence of pathology or sonographically evident/active inflammation.

***Free Abdomen***

**WEIGHT**

81.6 Pounds

A large irregular mixed echogenic undifferentiated mass was noted in the caudal abdomen in the area of the iliac trifurcation, potentially extending into the pelvic inlet, measuring potentially 8-9 cm in diameter. Concurrent focal to intermittent, mildly swollen, homogenous medial iliac lymphadenopathy was present, an example of lymph node size measured 2.4 cm x 1.7 cm.

**INTERPRETED BY**

R. McKenzie Daniel,  
DVM, DABVP  
(Canine and Feline)

**ULTRASONOGRAPHIC FINDINGS**

- Undifferentiated caudal abdominal mass, potentially extending into the area of the pelvic inlet
- Associated prominent to mildly swollen medial iliac lymphadenopathy
- Right kidney, severe hydronephrosis with concurrent variable to likely generalized right hydroureter
- Sonographically normal left kidney
- Mild hepatic parenchymal remodeling- subjectively benign
- Mild gallbladder debris (non-mucocele)
- Sonographically unremarkable gastrointestinal tract with gastric and mild segmental intestinal ingesta

**IMAGING PERFORMED BY**

Amy Mayhew, LVT

**HOSPITAL NAME**

SVS Imaging MI

**REFERRING VET**

Dr. Kupraszewicz-  
Bell VC

**INTERPRETATION OF THE FINDINGS & FURTHER RECOMMENDATIONS**

**INVOICE**

20398

Although sampling is required for further assessment, the undifferentiated caudal abdominal mass is sonographically consistent with neoplastic criteria. The mass appears to be obstructing or possibly invading the area of the distal right ureter, resulting in hydroureter and severe right hydronephrosis. Concern for regional metastatic medial iliac lymphadenopathy or possible regional omental seeding is warranted. FNA cytology of the mass vs abdominal CT for further clarification may be considered. Three view chest radiographs are recommended. Monitoring for evidence of gastric emptying is recommended if evidence of nonobstructive gastric stasis.

**DATE**

1/5/23



**PATIENT**

Oskar Field

**SPECIES**

Canine

**BREED**

Boxer

**SEX**

Neutered Male

**AGE**

10 Years

**WEIGHT**

81.6 Pounds

**INTERPRETED BY**

R. McKenzie Daniel, DVM, DABVP (Canine and Feline)

**IMAGING PERFORMED BY**

Amy Mayhew, LVT

**HOSPITAL NAME**

SVS Imaging MI

**REFERRING VET**

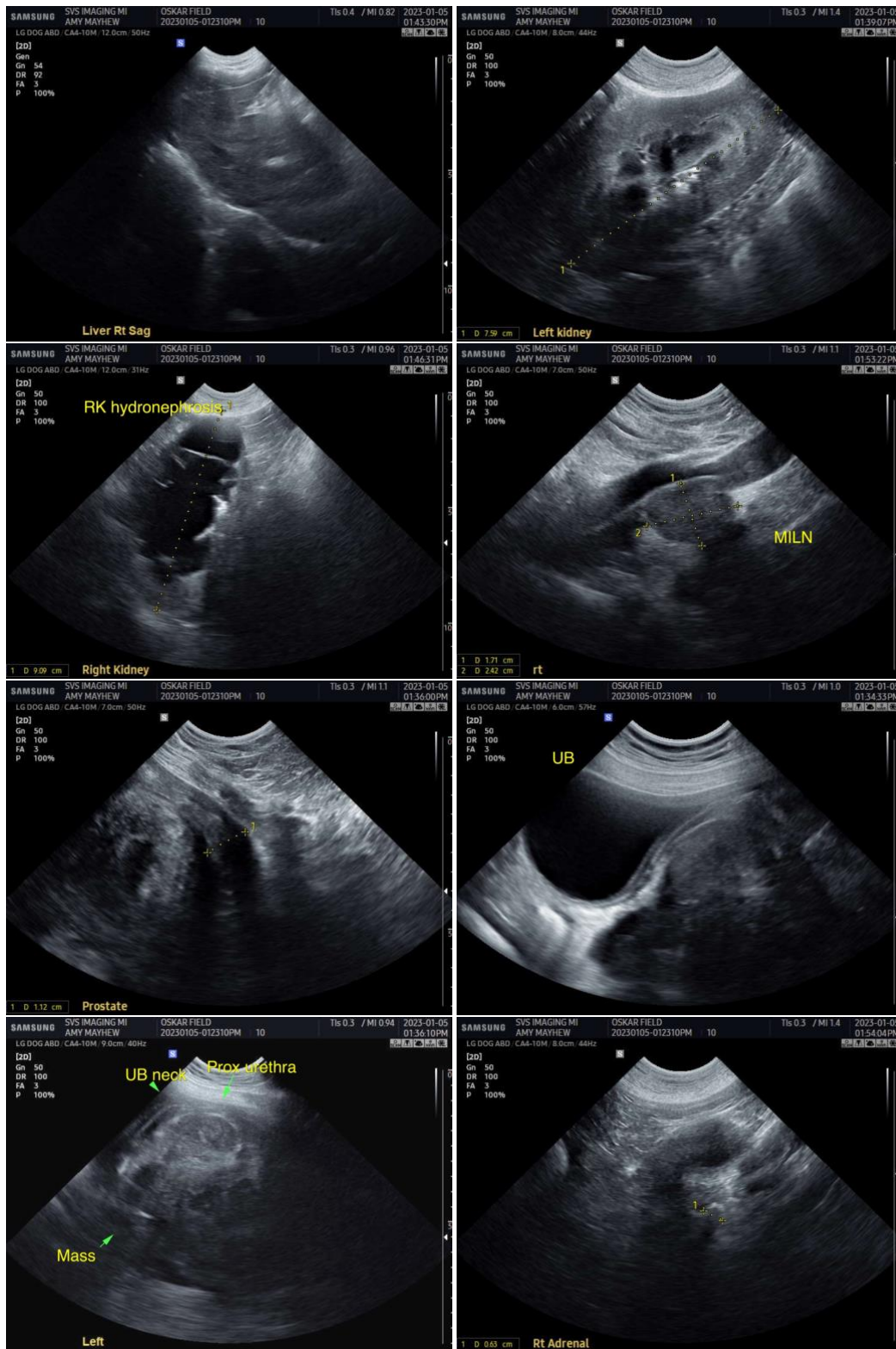
Dr. Kupraszewicz-Bell VC

**INVOICE**

20398

**DATE**

1/5/23





## PATIENT

Oskar Field

## SPECIES

Canine

## BREED

Boxer

## SEX

Neutered Male

## AGE

10 Years

## WEIGHT

81.6 Pounds

## INTERPRETED BY

R. McKenzie Daniel,  
DVM, DABVP  
(Canine and Feline)

## IMAGING PERFORMED BY

Amy Mayhew, LVT

## HOSPITAL NAME

SVS Imaging MI

## REFERRING VET

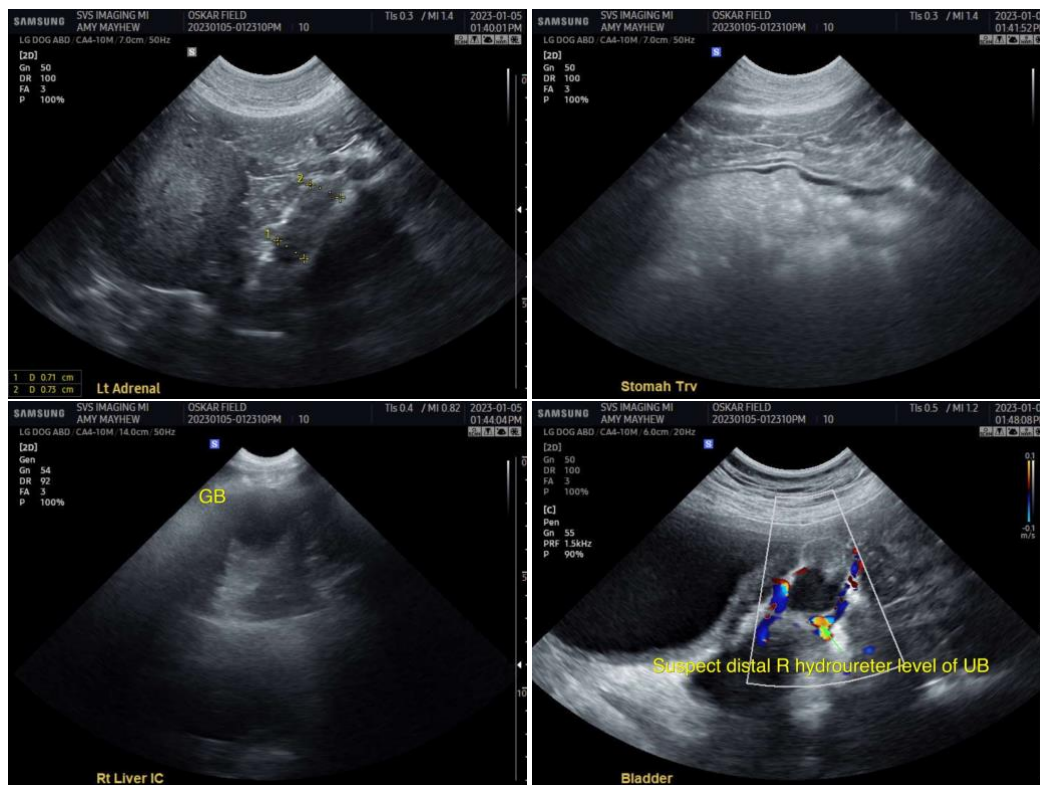
Dr. Kupraszewicz-  
Bell VC

## INVOICE

20398

## DATE

1/5/23



The information and recommendations provided are based on the images presented by the referring veterinarian. No evaluation can be communicated regarding pathology that was not visible in the image/video clips provided.

Thank you for this referral. If the clinical or image interpretation does not parallel your findings or if I can be of any further assistance please contact me.

**R. McKenzie Daniel, DVM, DABVP (Canine / Feline Practice)**  
info@SonoPath.com