


PATIENT

Bailey Kranendonk

SPECIES

Canine

BREED

Cocker X

SEX

MN

AGE

11 years

WEIGHT

24.2 kg

INTERPRETED BY

 R. McKenzie Daniel,
 DVM, DABVP

**IMAGING
 PERFORMED BY**

Crystal Hill

HOSPITAL NAME

 Burlington Lakeshore
 VH

REFERRING VET

Dr. Aziz

INVOICE

12954

DATE

1/4/22

PRESENTING CLINICAL SIGNS

Grade 3 heart murmur, Generalized cardiomegaly. Interstitial to alveolar pulmonary pattern consistent with cardiogenic pulmonary edema.

Abnormal PE/Chem/CBC/UA Results: Please see attached radiographs and bloodwork.

ULTRASONOGRAPHIC EXAMINATION OF THE HEART

CANINE CARDIAC PARAMETERS	MR VMAX (m/s)	TR VMAX (m/s)	LA/AO (Boon method)	LA/AO (Heart Base; Swe)	FS (%)	EF (%)	EPSS (cm)
NORMAL PARAMETER	4.5-5.5	<2.7	1.3	<1.6	28-40	40-100	<0.6
PATIENT	5.2	2.6	2.45	2.4	35.2	68	0.65
CANINE CARDIAC PARAMETERS	HR (BPM)	AV VMAX (m/s)	PV MAX (m/s)	BODY WEIGHT (kg)	LA 2D short axis Base view (cm)	LVIDd Avg; 2D and m- mode short axis (cm)	LVIDs Avg; 2D and m- mode short axis (cm)
NORMAL PARAMETER	50-100	0.7-1.7	0.7-1.6	BELOW	BELOW	BELOW	BELOW
PATIENT	100	1.8	1.1		6.3	5.4	

Cardiac Presentation

The echocardiogram in this patient demonstrated severely enlarged **left atrial** size based on 3 different LA measurement methods. Deviation of the interatrial septum towards the right atrium consistent with elevated left atrial pressure was present. Doppler indicated measurable eccentric insufficiency. The cranial and caudal **mitral** valve leaflets presented vegetative thickening consistent with endocardiosis. No overt evidence of valvular prolapse or chordae tendineae rupture was noted. Doppler indicated measurable insufficiency. The **left ventricle** presented thicknesses with linear contour with increased left ventricle volume. The **myocardium** presented normal echogenicity without subjective evidence of significant fibrotic or ischemic disease. **Contractility** of the ventricular walls was adequate and in normal range for this patient evidenced by the fractional shortening measurement and subjective evaluation of the different regions of the myocardium. The **left ventricular outflow** tract demonstrated normal laminar flow and subjective structural integrity. The **right atrium** and auricle revealed normal size, structure and content. No evidence of masses was noted or chamber overload. **Tricuspid** valvular assessment demonstrated adequate linear morphology. Mild tricuspid valve Insufficiency was present on color doppler. The **right ventricle** was of normal size (1/3 diameter of LV), chordae structure, myocardial echogenicity and thickness. **Pulmonic** tract assessment revealed normal valve structure, laminar flow, and diameter (approx. 1:1 pa/ao ratio). No visible **pericardial** or free pleura fluid was noted. No echographically detectable



PATIENT

Bailey Kranendonk

evidence of infiltrative disease was visible. The cranial **mediastinum and pericardial regions** were free of masses in the visible window.

ULTRASONOGRAPHIC FINDINGS

SPECIES

Canine

Primary Findings

- Chronic mitral valve disease (ACVIM Stage-C)
- Mild TR - estimated pulmonary pressure gradient (approximately 26 mmHg) consistent with mild elevated pulmonary pressure yet not overt clinical pulmonary hypertension

BREED

Cocker X

INTERPRETATION OF THE FINDINGS & FURTHER RECOMMENDATIONS

SEX

MN

The degree of left atrium enlargement indicates that the risk going forward for complication remains elevated as consistent with cardiogenic pulmonary edema. Pimobendan 0.3 mg/kg PO BID, Lasix at the lowest effective dose (1-2.0 mg/kg PO BID), are recommended. Enalapril or Benazepril 0.5 mg/kg is warranted if blood pressure is >130, yet not recommended if blood pressure is <130. Continued monitoring of renal parameters and resting respiration rate going forward is advised. Monitoring of thoracic radiographs for resolved or persistent pulmonary edema is suggested. Hydrocodone may prove beneficial if clinically indicated or if consistent cough. Recheck echocardiogram is suggested in 4-6 months, sooner if continued clinical signs consistent with left-sided heart disease persist or progress.

AGE

11 years

WEIGHT

24.2 kg

INTERPRETED BY

R. McKenzie Daniel,
DVM, DABVP

IMAGING PERFORMED BY

Crystal Hill

HOSPITAL NAME

Burlington Lakeshore
VH

REFERRING VET

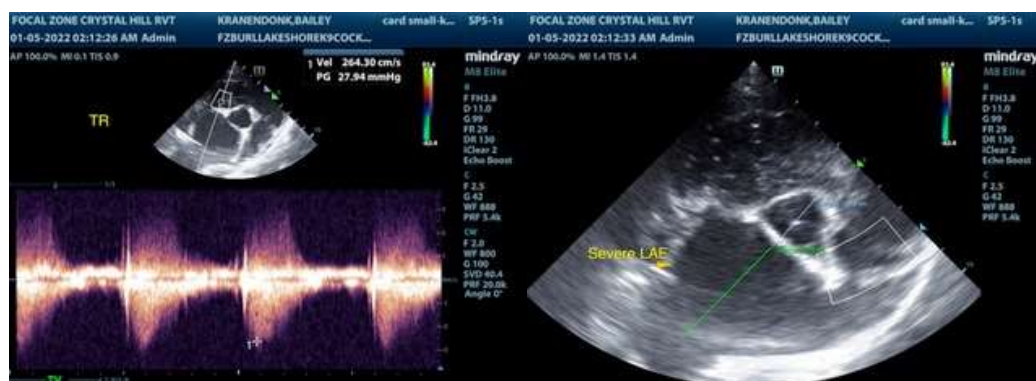
Dr. Aziz

INVOICE

12954

DATE

1/4/22





PATIENT

Bailey Kranendonk

SPECIES

Canine

BREED

Cocker X

SEX

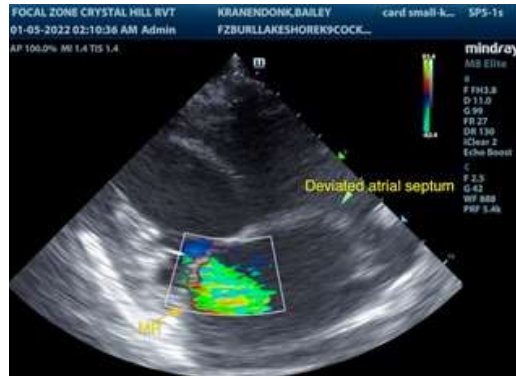
MN

AGE

11 years

WEIGHT

24.2 kg



The information and recommendations provided are based on the images presented by the referring veterinarian. No evaluation can be communicated regarding pathology that was not visible in the image/video clips provided.

Thank you for this referral. If the clinical or image interpretation does not parallel your findings or if I can be of any further assistance please contact me.

INTERPRETED BY

R. McKenzie Daniel,
DVM, DABVP

R. McKenzie Daniel, DVM, DABVP (Canine / Feline Practice)
info@SonoPath.com

IMAGING PERFORMED BY

Crystal Hill

HOSPITAL NAME

Burlington Lakeshore
VH

REFERRING VET

Dr. Aziz

INVOICE

12954

DATE

1/4/22