**PATIENT**

Indie Sinnett

SPECIES

Feline

BREED

DSH

SEX

FS

AGE

8 years

WEIGHT

11 lbs.

INTERPRETED BYR. McKenzie Daniel,
DVM, DABVP (Canine
and Feline)**IMAGING
PERFORMED BY**

Rachel Runnells, RVT

HOSPITAL NAME

SVS Imaging KC

REFERRING VET

Dr. Sarah Burkindine

INVOICE

16033

DATE

1/31/23

PRESENTING CLINICAL SIGNS

Weight loss - 4 lb since summer, intermittent inappetence. Is blind from histoplasmosis several years ago.

Abnormal PE/Chem/CBC/UA Results: Tachycardia; BUN-81; Creat-5.4; SDMA-22.1; Amylase 2549; WBC-21.3; neuts 10437; lymphs 10437.

ULTRASONOGRAPHIC EXAMINATION OF THE ABDOMEN**Urinary System**

The urinary bladder was non-distended with anechoic urine present in the lumen with no evidence of inflammatory or neoplastic changes was noted. The urethra exhibited normal structure and tone to a depth of 2.0 cm.

The area of the aortic trifurcation was free of pathology.

The left kidney exhibited low-end of normal for size measuring 3.3 cm length with asymmetrical margination. Moderate loss of corticomedullary border demarcation was present with subjective reduced medullary volume. Mild to moderate left kidney pyelectasia was present with increased echogenicity of the renal sinus. No evidence of left retroperitoneal free fluid or neoplastic criteria was evident.

The right kidney was subnormal in size with asymmetrical margination and moderate to marked loss of corticomedullary border demarcation. Reduce medullary volume was noted in the right kidney with pinpoint dystrophic medullary mineral and no evidence of right kidney pyelectasia or right retroperitoneal effusion. The right kidney measured 2.7 cm in length.

Adrenal Glands

The left adrenal gland was uniform in size and contour with a uniformly hypoechoic parenchyma. The left adrenal gland measured 0.57 cm width. The right adrenal gland was uniform in size and contour with a uniformly hypoechoic parenchyma. The right adrenal gland measured 0.32 cm width.

Spleen

The spleen exhibited a finely textured and homogenous parenchyma which was hyperechoic to the liver and renal cortical parenchyma. The capsule was smooth and regular without apparent expansion. The splenic vasculature at the hilus was normal in volume with no evidence of congestion or thrombosis. Acute to chronic inflammatory, neoplastic, or benign parenchyma changes were not noted.

Liver/ Gallbladder

The liver was subjectively normal in size, structure, and contour. The liver parenchyma was uniform and hypoechoic to the spleen with a mild coarse echotexture. The hepatic and portal vasculature were normal in appearance without signs of congestion. The gallbladder was non-distended in size with thin walls and primarily anechoic luminal content. The cystic and common bile ducts were normal.

Transdiaphragmatic view revealed a mild comet tail lung pattern, which is echogenic sound wave interface with microconsolidations within the caudal lung field. The lung field should not be visualized by sonogram unless pathology is present. Chest radiographs are recommended to rule out

**PATIENT**

Indie Sinnett

alveolar/lung disease such as neoplasia, thromboembolic disease, chronic inflammatory disease with microconsolidation.

Gastrointestinal**SPECIES**

Feline

The stomach presented intact wall layering with a normal wall layer ratio. Minor retained nonshadowing chyme was present.

The small intestine presented intact wall layering with 1:3 muscularis/mucosa ratio. The lumen of the small intestine was empty with no signs of ileus, obstruction, or foreign material.

BREED

DSH

Normal visible colon wall layers were present with apparent formed feces in lumen.

SEX

FS

Pancreas

The parenchyma of the left limb, body, and right limb of the pancreas presented isoechoic to the adjacent omental fat. A normal curvilinear capsule contour of the pancreas was present. The visible pancreatic duct was normal. No signs of active inflammation or neoplastic disease were evident.

AGE

8 years

Free Abdomen

No overt lymphadenopathy or peritoneal effusion was present.

WEIGHT

11 lbs.

ULTRASONOGRAPHIC FINDINGS

- Left kidney moderate chronic nephropathy with mild to moderate pyelectasia
- Right kidney moderate to marked chronic nephropathy with subnormal size
- Overtly normal gastrointestinal tract / pancreas
- Nonspecific mild transdiaphragmatic comet tail artifact

INTERPRETED BY

R. McKenzie Daniel,
DVM, DABVP (Canine
and Feline)

INTERPRETATION OF THE FINDINGS & FURTHER RECOMMENDATIONS

Sonographically, the appearance of the kidneys is consistent with chronic nephropathy / CRD as opposed to acute kidney injury or insult. Chronic dysplasia, nonspecific chronic nephritis i.e., interstitial nephritis, pyelonephritis, or other chronic nephropathy possible. Full urinary workup including urinalysis, as well as additional renal staging to include screening C/S and baseline UPC level is suggested. Empirically, CKD therapy with monitoring of systemic BP is warranted.

IMAGING PERFORMED BY

Rachel Runnells, RVT

HOSPITAL NAME

SVS Imaging KC

A GI panel to include PLI/TLI/Cobalamin/Folate, as well as three view chest radiographs and neurological / musculoskeletal examination, are recommended to assess for or rule out occult disease which may cause weight loss. A guarded to very guarded potential long-term prognosis is indicated, given the current degree of azotemia and pending additional urinary workup.

REFERRING VET

Dr. Sarah Burkindine

INVOICE

16033

DATE

1/31/23



PATIENT

Indie Sinnett

SPECIES

Feline

BREED

DSH

SEX

FS

AGE

8 years

WEIGHT

11 lbs.

INTERPRETED BY

R. McKenzie Daniel,
DVM, DABVP (Canine
and Feline)

**IMAGING
PERFORMED BY**

Rachel Runnells, RVT

HOSPITAL NAME

SVS Imaging KC

REFERRING VET

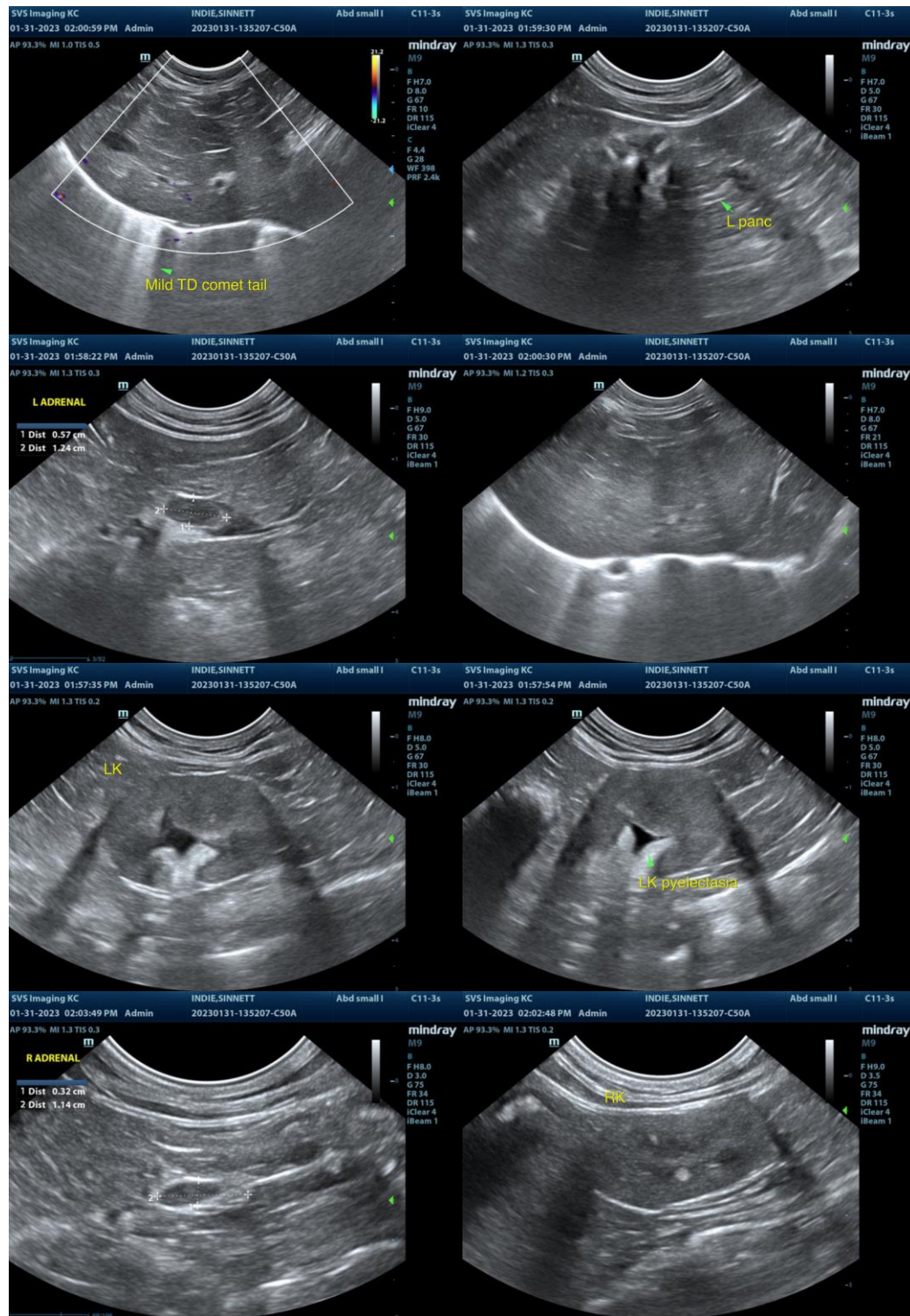
Dr. Sarah Burkindine

INVOICE

16033

DATE

1/31/23



IMAGING PERFORMED BY

SVS Mobile Imaging KC 816-401-5010
svsimagingkc@gmail.com



Clinical Sonography & Telectology

EDUCATIONAL TELECONSULTATION SERVICES™

1-800-838-4268 info@sonopath.com SonoPath.com

PATIENT

Indie Sinnett

SPECIES

Feline

BREED

DSH

SEX

FS

AGE

8 years

WEIGHT

11 lbs.

INTERPRETED BY

R. McKenzie Daniel,
DVM, DABVP (Canine
and Feline)

**IMAGING
PERFORMED BY**

Rachel Runnells, RVT

HOSPITAL NAME

SVS Imaging KC

REFERRING VET

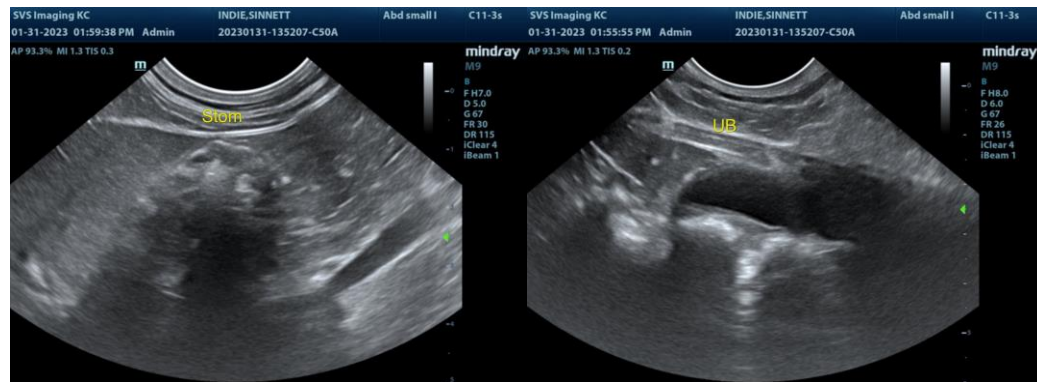
Dr. Sarah Burkindine

INVOICE

16033

DATE

1/31/23



The information and recommendations provided are based on the images presented by the referring veterinarian/sonographer. No evaluation can be communicated regarding pathology that was not visible in the image/video clips provided.

Thank you for this referral. If the clinical or image interpretation does not parallel your findings or if I can be of any further assistance please contact me.

R. McKenzie Daniel, DVM, DABVP (Canine / Feline Practice)
info@SonoPath.com