



PATIENT

Yue Milligan

SPECIES

Feline

BREED

Tortoise Shell

SEX

Spayed Female

AGE

2 Years

WEIGHT

12.2 Lbs.

INTERPRETED BY

R. McKenzie Daniel,
DVM, DABVP
(Canine and Feline)

IMAGING PERFORMED BY

Amanda Crook- SDEP
Certified
Sonographer/Jasmine
Palacios SDEP
Attendee

HOSPITAL NAME

Rivers Edge PMC

REFERRING VET

Dr. David Gray

INVOICE

13704

DATE

1/21/22

PRESENTING CLINICAL SIGNS

History: These are follow up images for urinary bladder ultrasound from last week -- UPDATE: the patient's age was incorrect in our computer -- please note that she is 2, not 10!
Abnormal PE/Chem/CBC/UA Results:

LIMITED ULTRASONOGRAPHIC EXAMINATION

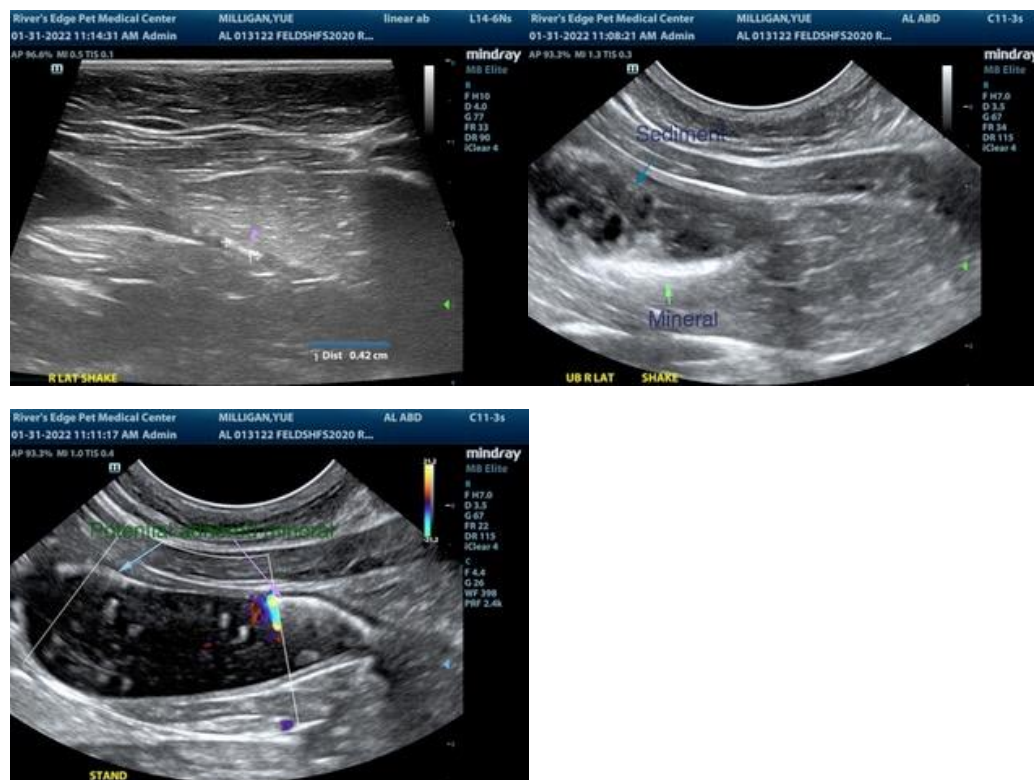
The urinary bladder was normal in size and tone. Previously noted moderate dependent to nondependent subjectively mobile to potentially adhered hyperechoic sediment/mucus and mild mineral, subject mild static cystitis pattern.

ULTRASONOGRAPHIC FINDINGS

- The urinary bladder exhibited similar presentation compared to the previous ultrasound with more subjective mobile sediment and mineral pattern compared to the previous ultrasound. Suspect some degree of likely minor to mild chronic interstitial cystitis.

INTERPRETATION OF THE FINDINGS & FURTHER RECOMMENDATIONS

Urine culture on sterile urine sample (if not done) recommended to assess for or rule out underlying urinary tract infection. Empirical therapy for feline idiopathic cystitis/FLUTD which may include previously mentioned medications urinary dissolution diet, etc. is recommended with sonographic monitoring of the urinary bladder if clinically indicated.



The information and recommendations provided are based on the images presented by the referring veterinarian. No evaluation can be communicated regarding pathology that was not visible in the image/video clips provided.



PATIENT

Yue Milligan

Thank you for this referral. If the clinical or image interpretation does not parallel your findings or if I can be of any further assistance please contact me.

SPECIES

Feline

R. McKenzie Daniel, DVM, DABVP (Canine / Feline Practice)
info@SonoPath.com

BREED

Tortoise Shell

SEX

Spayed Female

AGE

2 Years

WEIGHT

12.2 Lbs.

INTERPRETED BY

R. McKenzie Daniel,
DVM, DABVP
(Canine and Feline)

**IMAGING
PERFORMED BY**

Amanda Crook - SDEP
Certified
Sonographer/Jasmine
Palacios SDEP
Attendee

HOSPITAL NAME

Rivers Edge PMC

REFERRING VET

Dr. David Gray

INVOICE

13704

DATE

1/21/22