

## PATIENT

Jeffery Veras

## SPECIES

Canine

## BREED

Pitbull Mix

## SEX

MN

## AGE

5yr

## WEIGHT

26.7kg

## INTERPRETED BY

R. McKenzie Daniel,  
DVM, DABVP  
(Canine and Feline)

## IMAGING PERFORMED BY

Dr Gira

## HOSPITAL NAME

Petzoic VH

## REFERRING VET

Dr Poffenroth

## INVOICE

23730

## DATE

01/30/2026

## PRESENTING CLINICAL SIGNS

- History of urinary incontinence. Stable on PPA currently (started recently)

Abnormal PE/Chem/CBC/UA Results: NA

## ULTRASONOGRAPHIC EXAMINATION OF THE ABDOMEN

### Urinary System

The urinary bladder, trigone, cystourethral junction, and visible pelvic urethra to a depth of 3 cm exhibited normal thickness and tone. Anechoic urine was present in the lumen with no evidence of urine/lumen sediment, mineral, or calculi. The ureteral papillae were normal. The ureters were not visible which is normal. No evidence of inflammatory or neoplastic changes was noted.

Normal size and margination were present in the kidneys. A normal 1:3 cortex / medulla ratio and normal corticomedullary definition were maintained. The echogenicity of the cortex was similar to or slightly less than normal liver parenchyma while the medulla echogenicity was hypoechoic to the cortex with no evidence of pelvic dilation. The left kidney measured 7.0 cm in length. The right kidney measured 7.9 cm in length.

The area of the aortic trifurcation was free of pathology.

The residual prostate appeared normal and free of pathology measuring 1.3 cm in diameter.

### Adrenal Glands

The left adrenal gland was uniform in size and contour with a uniformly hypoechoic parenchyma. The left adrenal gland measured 0.57 cm width at the caudal pole. The right adrenal gland was uniform in size and contour with a uniformly hypoechoic parenchyma. The right adrenal gland measured 0.47 cm width at the caudal pole.

### Spleen

The spleen exhibited a finely textured and homogenous parenchyma which was hyperechoic to the liver and renal cortical parenchyma. The capsule was smooth and regular without apparent expansion. The splenic vasculature at the hilus was normal in volume with no evidence of congestion or thrombosis. Acute to chronic inflammatory, neoplastic, or benign parenchyma changes were not noted.

### Liver/Gallbladder

The liver was subjectively normal in size, structure, and contour. The liver parenchyma was uniform and hypoechoic to the spleen with a mild coarse echotexture. Normal vascular volume. The hepatic and portal vasculature were normal in appearance without signs of congestion. The gallbladder was non-distended in size with thin walls and primarily anechoic luminal content. The cystic and common bile ducts were normal.

### Gastrointestinal

The stomach presented intact wall layering with a normal wall layer ratio. The lumen of the stomach was empty with no signs of ileus, obstruction or foreign material.



## PATIENT

Jeffery Veras

The small intestine presented intact wall layering with 1:3 muscularis/mucosa ratio. The lumen of the small intestine was empty with no signs of mechanical/metabolic ileus, obstruction or foreign material.

Normal visible colon wall layers were present with apparent formed feces in lumen.

## SPECIES

Canine

### *Pancreas*

The parenchyma of the left limb, body and right limb of the pancreas presented isoechoic to the adjacent omental fat. A normal curvilinear capsule contour of the pancreas was present. The visible pancreatic duct was normal. No signs of active inflammation or neoplastic disease was evident.

## BREED

Pitbull Mix

### *Free Abdomen*

No evidence of peritoneal effusion was present.

## SEX

MN

The visualized jejunal lymph nodes were sonographically normal without inflammatory or neoplastic criteria.

## ULTRASONOGRAPHIC FINDINGS

## AGE

5yr

### *Primary*

- Normal urinary bladder, residual prostate and visible proximal urethra
- Normal bilateral kidneys

## WEIGHT

26.7kg

## INTERPRETATION OF THE FINDINGS & FURTHER RECOMMENDATIONS

No evidence of upper or lower urinary tract pathology. Continued empirical therapy for incontinence is recommended.

## INTERPRETED BY

R. McKenzie Daniel,  
DVM, DABVP  
(Canine and Feline)

## IMAGING PERFORMED BY

Dr Gira

## HOSPITAL NAME

Petzoic VH

## REFERRING VET

Dr Poffenroth

## INVOICE

23730

## DATE

01/30/2026



**PATIENT**

Jeffery Veras

**SPECIES**

Canine

**BREED**

Pitbull Mix

**SEX**

MN

**AGE**

5yr

**WEIGHT**

26.7kg

**INTERPRETED BY**

R. McKenzie Daniel,  
DVM, DABVP  
(Canine and Feline)

**IMAGING PERFORMED BY**

Dr Gira

**HOSPITAL NAME**

Petzoic VH

**REFERRING VET**

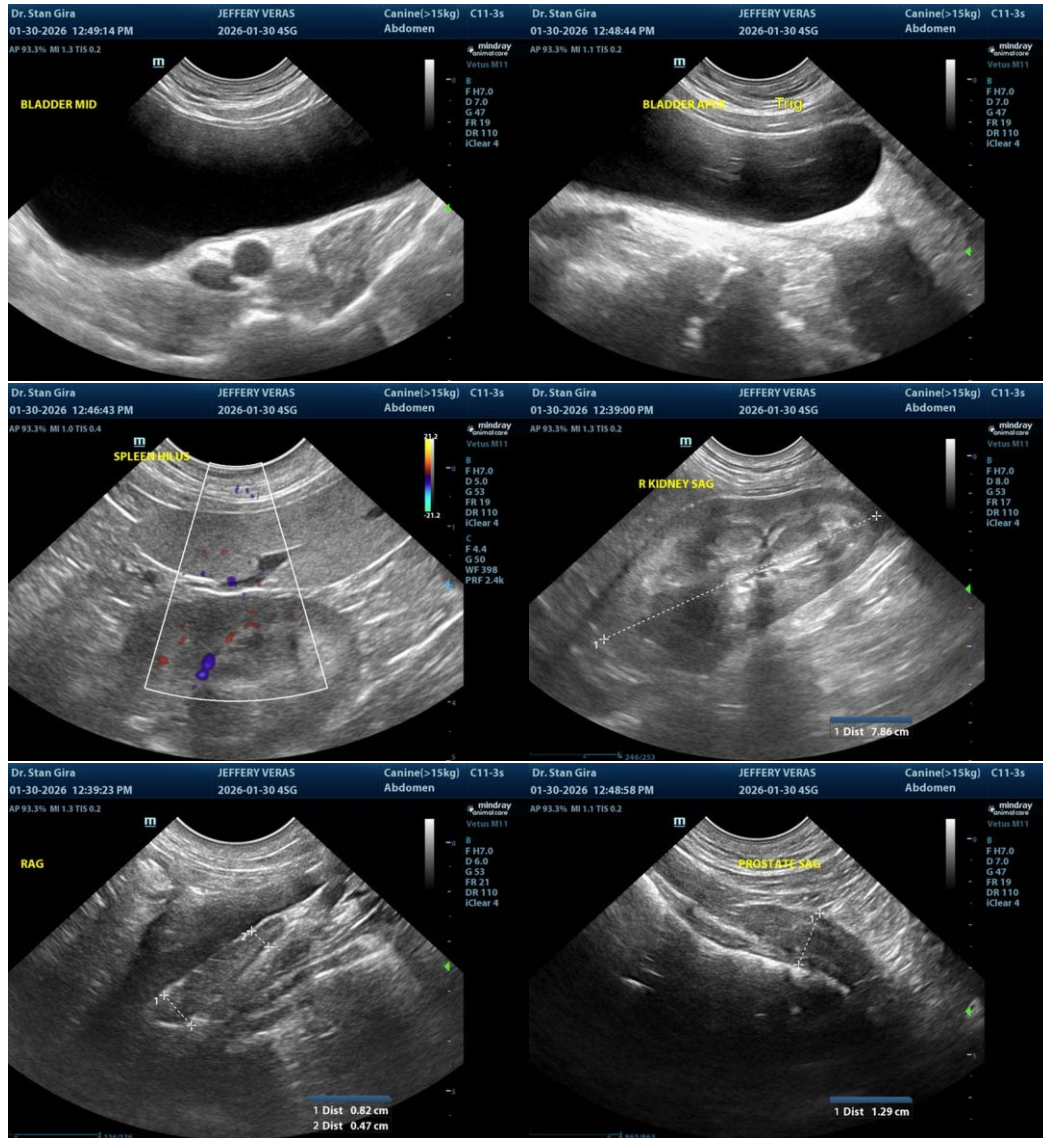
Dr Poffenroth

**INVOICE**

23730

**DATE**

01/30/2026





**PATIENT**

Jeffery Veras

**SPECIES**

Canine

**BREED**

Pitbull Mix

**SEX**

MN

**AGE**

5yr

**WEIGHT**

26.7kg

**INTERPRETED BY**

R. McKenzie Daniel,  
DVM, DABVP  
(Canine and Feline)

**IMAGING PERFORMED BY**

Dr Gira

**HOSPITAL NAME**

Petzoic VH

**REFERRING VET**

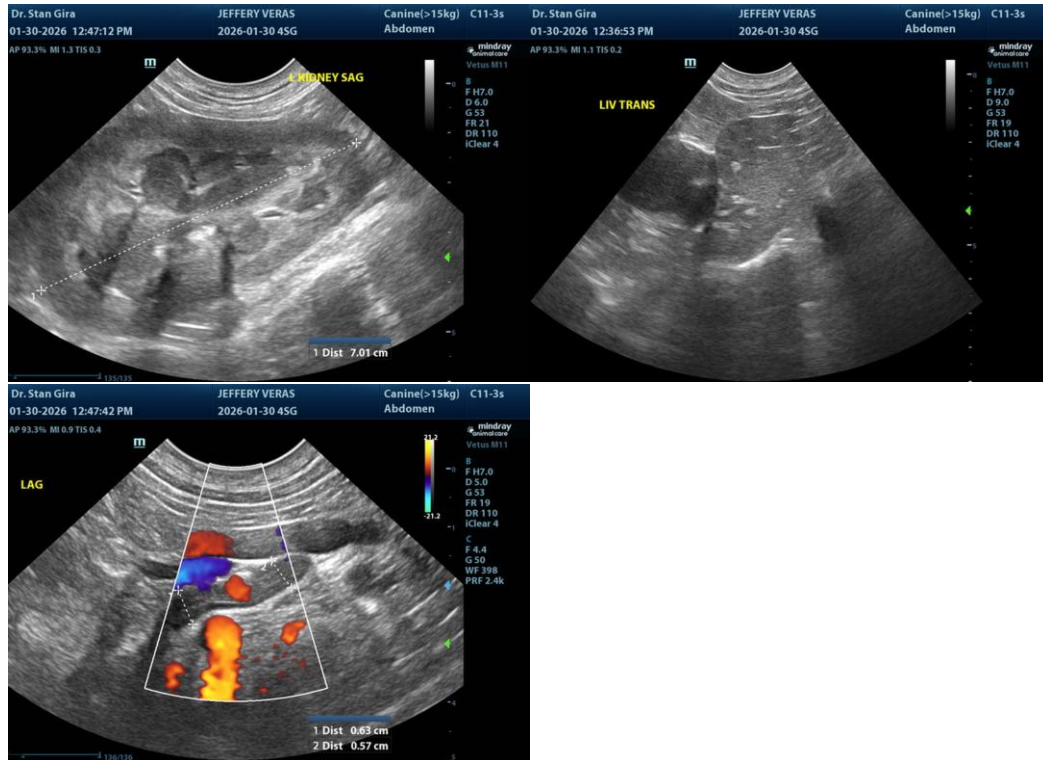
Dr Poffenroth

**INVOICE**

23730

**DATE**

01/30/2026



The information and recommendations provided are based on the images presented by the referring veterinarian/sonographer. No evaluation can be communicated regarding pathology that was not visible in the image/video clips provided.

Thank you for this referral. If the clinical or image interpretation does not parallel your findings or if I can be of any further assistance, please contact me.

R. McKenzie Daniel, DVM, DABVP (Canine/Feline Practice)  
[info@sonopath.com](mailto:info@sonopath.com)