



PATIENT

Eve Hall

PRESENTING CLINICAL SIGNS

- Recent labwork showed elevated pro-BNP. No mention of cardiac concern from PE findings i.e. arrhythmia or murmur or clinical signs at home.

SPECIES

Feline

Abnormal PE/Chem/CBC/UA Results: Elevated pro-BNP 171 BP 143mmHg on avg with doppler.

ULTRASONOGRAPHIC EXAMINATION OF THE HEART

BREED

DSH

SEX

FS

AGE

6.5yr

WEIGHT

9.6

FELINE CARDIAC PARAMETERS	BODY WEIGHT	HR (BPM)	IVSd (cm)	LVIDd (cm)	LVWd (cm)	FS (%)	EF (%)
NORMAL PARAMETER	-----	150-240	0.3-0.6	1.0-2.1	0.25-0.6	35-67	80-100
PATIENT	9.6	NM	0.43	1.36	0.44	50	82
FELINE CARDIAC PARAMETERS	LA/AO M-Mode	LA/AO HEART BASE (Sisson)	LAD LA MAX 4 Chamber		LVOT VEL. (m/s)	RVOT VEL. (m/s)	IVRT (m/)
NORMAL PARAMETER	<1.5	1.6	0.7-1.7		<1.6	<1.3	40-60
PATIENT	--	1.3	1.3		1.0	0.7	NM

Sisson D et al. JVIM 1991; 5: 232, Jacobs et al. Am J Vet Res 1985; 46:1705

INTERPRETED BY

R. McKenzie Daniel, DVM, DABVP (Canine and Feline)

Cardiac Presentation

The echocardiogram in this patient demonstrated normal left atrial size based on 2 separate LA measurements. The cranial and caudal mitral valve leaflets presented normal linear structure and kinetics. No overt MR present on Doppler. The left ventricle presented normal thicknesses with linear contour and was not dilated nor restricted. The myocardium presented normal echogenicity without subjective evidence of significant fibrotic or ischemic disease. The contractility of the ventricular walls was adequate and in normal range for this patient evidenced by the fractional shortening measurement and subjective evaluation of the different regions and angles of the myocardium. The left ventricular outflow tract demonstrated normal laminar flow and subjective structural integrity. Normal measured LVOT velocity was present. The right atrium and auricle revealed normal size, structure and content. No evidence of masses was noted or chamber overload. Tricuspid valvular assessment demonstrated adequate linear morphology and kinetics. No overt TR present on Doppler. The right ventricle was of normal size (1/3 diameter of LV), chordae structure, myocardial echogenicity and thickness. Pulmonic tract assessment revealed normal valve structure, laminar flow, and diameter (approx.1:1 pa/ao ratio). Normal measured RVOT velocity was present. No visible pericardial or free pleura fluid was noted or extra cardiac pathology in the visible planes. The cranial mediastinum and pericardial regions were free of masses in the visible window.

IMAGING PERFORMED BY

Sorbo

HOSPITAL NAME

JM Pet Resort & Veterinary Clinic

REFERRING VET

Sorbo

INVOICE 23721

DATE
01/30/2026

ULTRASONOGRAPHIC FINDINGS

Primary



PATIENT

Eve Hall

- Normal echocardiogram

INTERPRETATION OF THE FINDINGS & FURTHER RECOMMENDATIONS

SPECIES

No evidence of structural or functional cardiomyopathy.

Feline

BREED

DSH

SEX

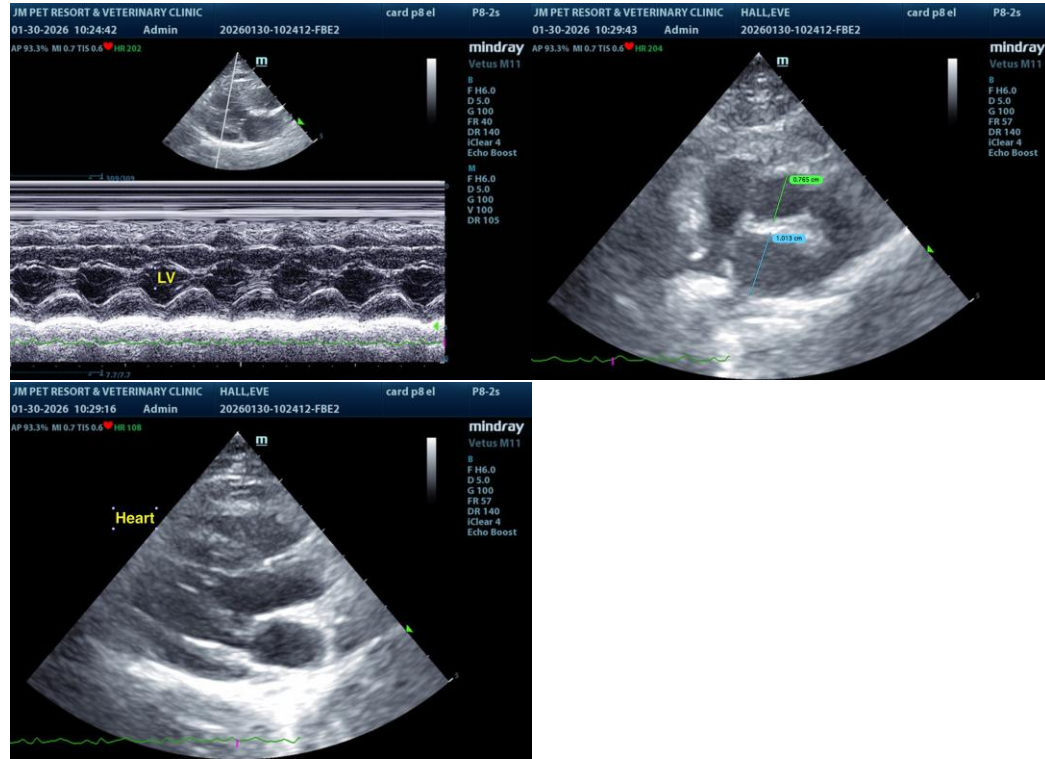
FS

AGE

6.5yr

WEIGHT

9.6



INTERPRETED BY

R. McKenzie Daniel,
DVM, DABVP
(Canine and Feline)

IMAGING PERFORMED BY

Sorbo

HOSPITAL NAME

JM Pet Resort &
Veterinary Clinic

REFERRING VET

Sorbo

INVOICE

23721

DATE

01/30/2026

The information and recommendations provided are based on the images presented by the referring veterinarian/sonographer. No evaluation can be communicated regarding pathology that was not visible in the image/video clips provided.

Thank you for this referral. If the clinical or image interpretation does not parallel your findings or if I can be of any further assistance, please contact me.

R. McKenzie Daniel, DVM, DABVP (Canine/Feline Practice)
info@sonopath.com