



PATIENT

Stella Alvaro

SPECIES

Feline

BREED

DSH

SEX

Spayed Female

AGE

9 Years

WEIGHT

7.7 pounds

INTERPRETED BY

R. McKenzie Daniel,
DVM, DABVP (Canine
/ Feline Practice)

IMAGING PERFORMED BY

Dr. Rodriguez

HOSPITAL NAME

Foxfield Veterinary
Services

REFERRING VET

Dr. Rodriguez

INVOICE

13449

DATE

01/29/26

PRESENTING CLINICAL SIGNS

- Straining to urinate/hematuria

ULTRASONOGRAPHIC EXAMINATION OF THE ABDOMEN

Urinary System

The urinary bladder, trigone, cystourethral junction, and visible pelvic urethra to a depth of 2.0 cm exhibited normal thickness and tone. Anechoic urine was present in the lumen with mild nondependent particulate urine sediment. The ureteral papillae were normal. The ureters were not visible which is normal. No evidence of inflammatory or neoplastic change were noted.

Normal size and margination was present in the kidneys. A normal 1:3 cortex / medulla ratio and normal corticomedullary definition were maintained. The echogenicity of the cortex was similar to or slightly less than normal liver parenchyma while the medulla echogenicity was hypoechoic to the cortex with no evidence of pyelectasia. The left kidney measured 3.7 cm in length. The right kidney measured 3.5 cm in length.

Adrenal Glands

The left adrenal gland was uniform in size and contour with a uniformly hypoechoic parenchyma. The left adrenal gland measured 0.40 cm width.

The right adrenal gland was uniform in size and contour with a uniformly hypoechoic parenchyma. The right adrenal gland measured 0.36 cm width.

Spleen

The spleen exhibited a finely textured and homogenous parenchyma which was hyperechoic to the liver and renal cortical parenchyma. The capsule was smooth and regular without apparent expansion. The splenic vasculature at the hilus was normal in volume with no evidence of congestion or thrombosis. Acute to chronic inflammatory, neoplastic, or benign parenchyma changes were not noted.

Liver & Gallbladder

The liver was subjectively normal in size, structure, and contour. The liver parenchyma was uniform and hypoechoic to the spleen with a mild coarse echotexture. The hepatic and portal vasculature were normal in appearance without signs of congestion.

The gallbladder was non-distended in size with thin walls and primarily anechoic luminal content. The cystic and common bile ducts were normal.

Gastrointestinal

The stomach presented intact wall layering with a normal wall layer ratio. The lumen of the stomach contained echogenic, moderate nonshadowing ingesta without signs of obstruction or foreign material.

The small intestine presented intact wall layering with 1:3 muscularis/mucosa ratio. Segmental nonshadowing ingesta/chyme was present.

Normal visible colon wall layers were present with apparent formed feces in lumen.



PATIENT

Pancreas

Stella Alvaro

The parenchyma of the left limb, body and right limb of the pancreas presented isoechoic to the adjacent omental fat. A normal curvilinear capsule contour of the pancreas was present. The visible pancreatic duct was normal. No signs of active inflammation or neoplastic disease was evident.

SPECIES

Feline

Free Abdomen

BREED

DSH

No overt lymphadenopathy or peritoneal effusion was present.

SEX

Spayed Female

ULTRASONOGRAPHIC FINDINGS

- Sonographically normal urinary bladder and visible proximal urethra with mild urine sediment.
- Normal kidneys.
- Gastrointestinal ingesta- consistent with food echogenicity.

AGE

9 Years

INTERPRETATION OF THE FINDINGS & FURTHER RECOMMENDATIONS

No evidence of lower urinary tract pathology, i.e. masses, calculi, etc. Correlation with pending lab work, urinalysis and culture/sensitivity if evidence of inflammatory sediment is recommended. Supportive care for potential mild idiopathic cystitis may be considered.

WEIGHT

7.7 pounds

INTERPRETED BY

R. McKenzie Daniel, DVM, DABVP (Canine / Feline Practice)

IMAGING PERFORMED BY

Dr. Rodriguez

HOSPITAL NAME

Foxfield Veterinary Services

REFERRING VET

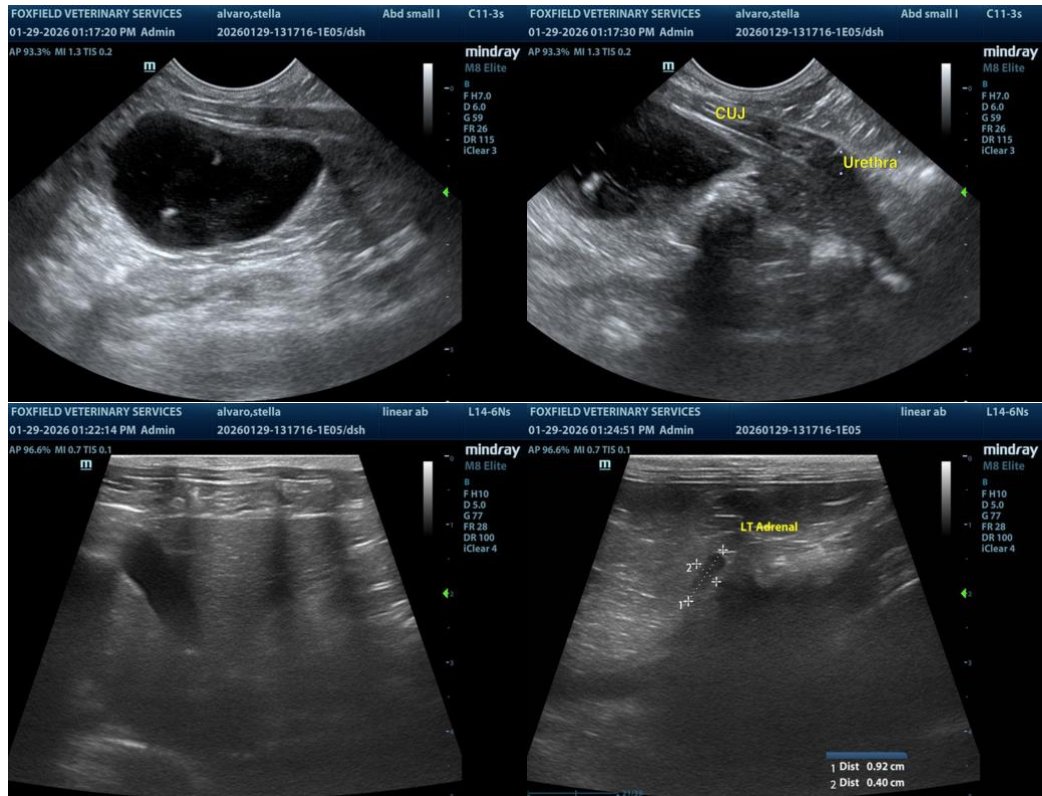
Dr. Rodriguez

INVOICE

13449

DATE

01/29/26





PATIENT

Stella Alvaro

SPECIES

Feline

BREED

DSH

SEX

Spayed Female

AGE

9 Years

WEIGHT

7.7 pounds

INTERPRETED BY

R. McKenzie Daniel,
DVM, DABVP (Canine
/ Feline Practice)

**IMAGING
PERFORMED BY**

Dr. Rodriguez

HOSPITAL NAME

Foxfield Veterinary
Services

REFERRING VET

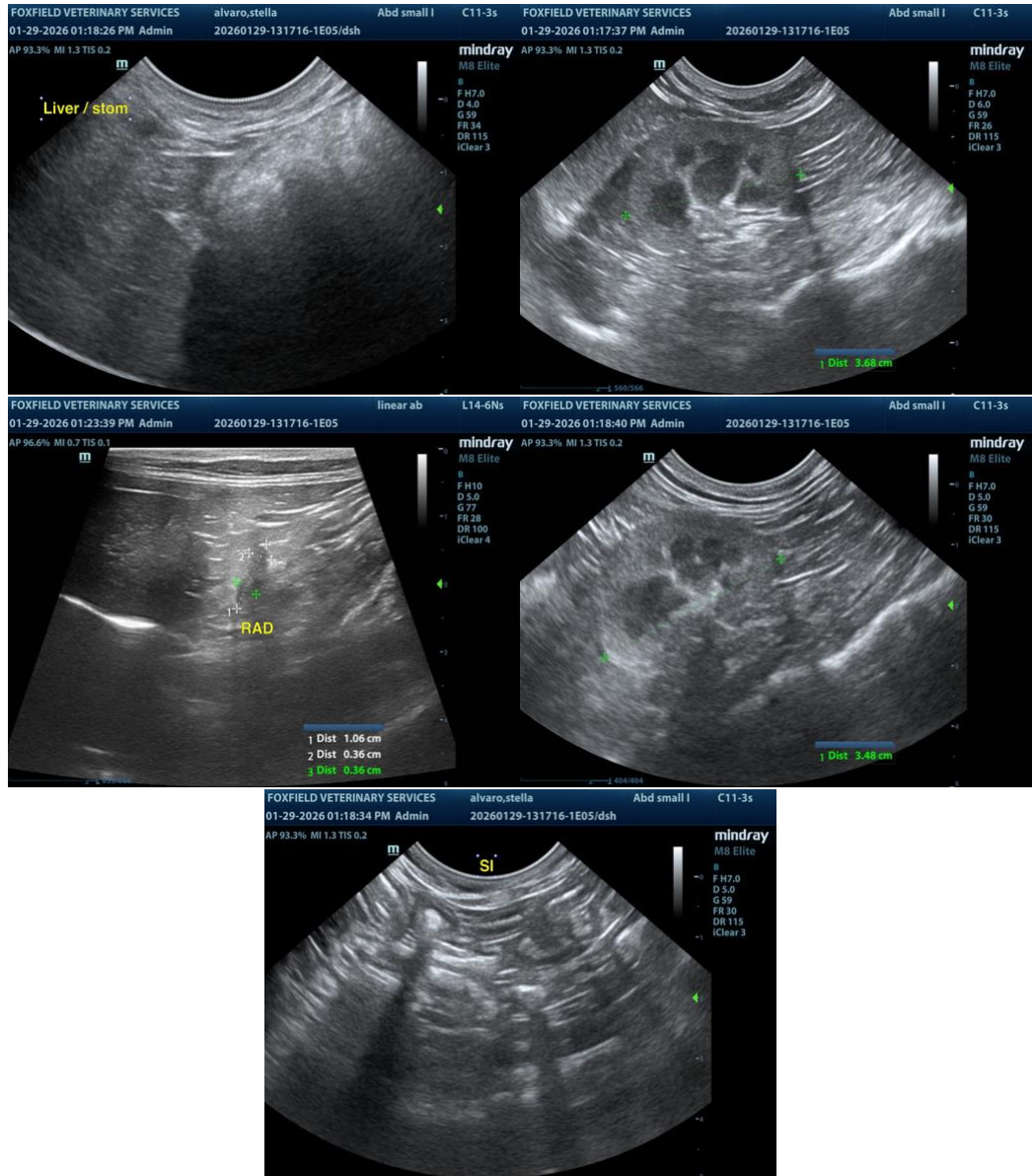
Dr. Rodriguez

INVOICE

13449

DATE

01/29/26



The information and recommendations provided are based on the images presented by the referring veterinarian/sonographer. No evaluation can be communicated regarding pathology that was not visible in the image/video clips provided.

Thank you for this referral. If the clinical or image interpretation does not parallel your findings or if I can be of any further assistance, please contact me.

R. McKenzie Daniel, DVM, DABVP (Canine / Feline Practice)

info@SonoPath.com