

**PATIENT PRESENTING CLINICAL SIGNS**

Bailey Haswell

History:

**SPECIES**

Canine

- Rads indicate heart enlargement
- ecg shows right axis deviation
- current meds: Torb/Midaz

**BREED**

Lab

Abnormal PE/Chem/CBC/UA Results: SDMA 16, Na 163; Anaplasma (+)

**SEX**

FS

**ULTRASONOGRAPHIC EXAMINATION OF THE HEART**

**AGE**

3y, 3m

**WEIGHT**

72.5 lbs.

CANINE CARDIAC PARAMETERS	MR VMAX (m/s)	TR VMAX (m/s)	LA/AO (M-Mode)	LA/AO (Heart Base; Swe)	FS (%)	EF (%)	EPSS (cm)
NORMAL PARAMETER	4.5-5.5	<2.7	1.3	Up to 1.6	28-40	40-100	<0.6
PATIENT	-	-	1.3	1.3	37	67	0.3
CANINE CARDIAC PARAMETERS	HR (BPM)	AV VMAX (m/s)	PV MAX (m/s)	BODY WEIGHT (lbs)	LAD LA MAX4 Chamber	LVIDd Avg; 2D and m-mode short axis (cm)	LVIDs Avg; 2D and m-mode short axis (cm)
NORMAL PARAMETER	50-100	0.7-1.7	0.7-1.6				
PATIENT	139	1.2	1.0	72.5	3.4	3.8	-

**INTERPRETED BY**

R. McKenzie Daniel,  
DVM, DABVP  
(Canine and Feline)

**IMAGING PERFORMED BY**

Shari Reffi, CVT

**HOSPITAL NAME**

Smithfield AH

**REFERRING VET**

Dr. Boe

**INVOICE**

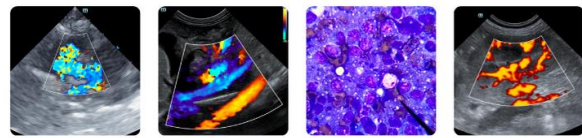
10601

**DATE**

1/29/26

**Cardiac Presentation**

The echocardiogram in this patient demonstrated normal **left atrial** size based on 3 separate methods of LA evaluation. The cranial and caudal **mitral** valve leaflets presented normal linear structure, extension in systole, and union in diastole with normal kinesis. The **left ventricle** presented thicknesses with linear contour and was not dilated nor restricted. The **myocardium** presented normal echogenicity without subjective evidence of significant fibrotic or ischemic disease. **Contractility** of the ventricular walls was adequate and in normal range for this patient evidenced by the fractional shortening measurement and subjective evaluation of the different regions of the myocardium. The **left ventricular outflow** tract demonstrated normal laminar flow and subjective structural integrity. The **right atrium** and auricle revealed normal size, structure and content. No evidence of masses was noted. **Tricuspid** valvular assessment demonstrated adequate linear morphology and kinesis. The **right ventricle** was of normal size (1/3 diameter of LV), chordae structure, myocardial echogenicity and thickness. **Pulmonary outflow** tract assessment revealed normal valve structure, laminar flow, and diameter (approx. 1:1 pa/ao ratio). No visible **pericardial** or free pleura fluid was noted. The cranial **mediastinum and pericardial and extra-cardiac regions** were free of masses in the visible window.



**PATIENT**

Bailey Haswell

**SPECIES**

Canine

**BREED**

Lab

**SEX**

FS

**AGE**

3y, 3m

**WEIGHT**

72.5 lbs.

**INTERPRETED BY**

R. McKenzie Daniel,  
 DVM, DABVP  
 (Canine and Feline)

**IMAGING PERFORMED BY**

Shari Reffi, CVT

**HOSPITAL NAME**

Smithfield AH

**REFERRING VET**

Dr. Boe

**INVOICE**

10601

**DATE**

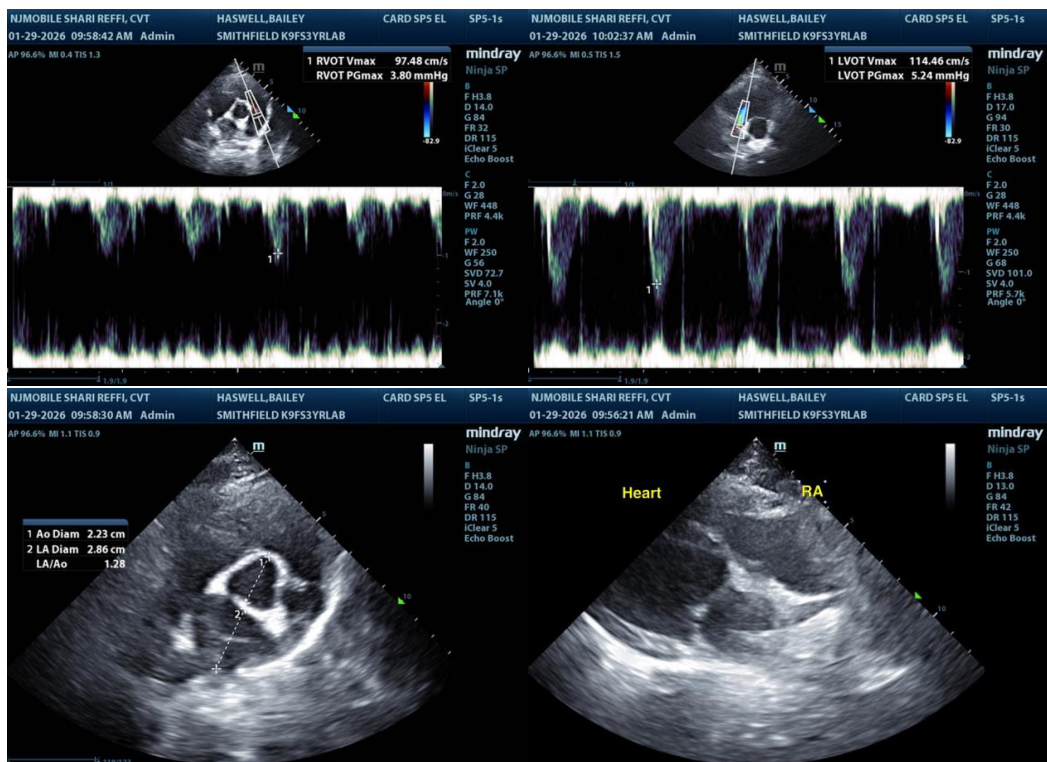
1/29/26

**ULTRASONOGRAPHIC FINDINGS**

- Normal cardiac structure / function

**INTERPRETATION OF THE FINDINGS & FURTHER RECOMMENDATIONS**

There is no evidence of clinical issues such as left or right heart chamber enlargement, LV systolic dysfunction, DCM criteria, valvular insufficiencies, or stenotic disease. There is no indication for cardiac medications. There are no anesthetic contraindications.



The information and recommendations provided are based on the images presented by the referring veterinarian/sonographer. No evaluation can be communicated regarding pathology that was not visible in the image/video clips provided.

Thank you for this referral. If the clinical or image interpretation does not parallel your findings or if I can be of any further assistance, please contact me.

R. McKenzie Daniel, DVM, DABVP (Canine / Feline Practice)  
[info@sonopath.com](mailto:info@sonopath.com)