

**PATIENT**

Cookie Giza

SPECIES

Canine

BREED

Schnauzer

SEX

SF

AGE

6 years

WEIGHT

24 lbs.

INTERPRETED BYR. McKenzie Daniel,
DVM, DABVP
(Canine and Feline)**IMAGING
PERFORMED BY**

Sarah Pender, CVT

HOSPITAL NAME

SVS Imaging QC

REFERRING VET

Dr. Hartmann

INVOICE

13212

DATE

1/28/22

PRESENTING CLINICAL SIGNS

V/D

Abnormal PE/Chem/CBC/UA Results: History of pancreatitis in 2019. BW is unremarkable today.
Rad - splenomegally.

ULTRASONOGRAPHIC EXAMINATION OF THE ABDOMEN**Urinary System**

The urinary bladder, trigone, and cystourethral junction exhibited normal thickness and tone. Anechoic urine was present in the lumen with no uroliths or sediment. The ureteral papillae were normal. The ureters were not visible which is normal. No evidence of inflammatory or neoplastic changes was noted.

The area of the aortic trifurcation was free of pathology.

Normal size and margination were present in the kidneys. A normal 1:3 cortex / medulla ratio and normal corticomedullary definition were maintained. The echogenicity of the cortex was similar to or slightly less than normal liver parenchyma while the medulla echogenicity was hypoechoic to the cortex with no evidence of pelvic dilation. The left kidney measured 4.9 cm in length. The right kidney measured 5.5 cm in length.

Adrenal Glands

The left adrenal gland was uniform in size and contour with a uniformly hypoechoic parenchyma. The left adrenal gland measured 0.58 cm width at the caudal pole and 0.50 cm width at the cranial pole. The right adrenal gland was uniform in size and contour with a uniformly hypoechoic parenchyma. The right adrenal gland measured 0.53 cm width at the caudal pole and 0.45 cm width at the cranial pole.

Spleen

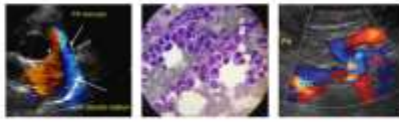The spleen exhibited a finely textured and homogenous parenchyma which was hyperechoic to the liver and renal cortical parenchyma. The capsule was smooth and regular without apparent expansion. The splenic vasculature at the hilus was normal in volume with no evidence of congestion or thrombosis. Acute to chronic inflammatory, neoplastic, or benign parenchyma changes were not noted.

Liver/ Gallbladder

The liver was subjectively normal in size, structure, and contour. The liver parenchyma was uniform and hypoechoic to the spleen with a mild coarse echotexture. The hepatic and portal vasculature were normal in appearance without signs of congestion. The gallbladder was non-distended in size with thin walls and primarily anechoic luminal content. The cystic and common bile ducts were normal.

Gastrointestinal

The visualized gastric walls presented intact wall layering with a normal wall layer ratio. The lumen of the stomach contained mild to potential moderate echogenic, ingesta and chyme exhibiting subtle progressive distal acoustic shadowing, along with luminal gas. No evidence of mechanical pyloric

**PATIENT**

Cookie Giza

outflow obstruction or overt foreign material was noted. The ventral gastric body wall width measured 0.37 cm.

SPECIES

Canine

The small intestine presented intact wall layering with 1:3 muscularis/mucosa ratio. The lumen of the small intestine was empty with no signs of ileus, obstruction, or foreign material. The jejunum wall width measured 0.28 cm.

Normal visible colon wall layers were present with apparent formed feces in lumen.

BREED

Schnauzer

Pancreas

The pancreas was normal in size and contour with isoechoic to heterogeneous parenchyma compared to adjacent omentum. No signs of active inflammation or neoplasia.

SEX

SF

Free Abdomen

No overt lymphadenopathy or peritoneal effusion was present.

AGE

6 years

ULTRASONOGRAPHIC FINDINGS***Primary Findings***

- Mild gastric ingesta / chyme with mild luminal gas
- Sonographically unremarkable small bowel and colon
- Mild heterogeneous pancreas
- Normal spleen

WEIGHT

24 lbs.

INTERPRETED BY

R. McKenzie Daniel,
DVM, DABVP
(Canine and Feline)

INTERPRETATION OF THE FINDINGS & FURTHER RECOMMENDATIONS

No evidence of significant visceral, specifically gastrointestinal or pancreatic, pathology was noted. The mildly heterogeneous pancreas may indicate patient variant, mild remodeling owing to previous inflammation with potential for low-grade to chronic pancreatitis which may present as essentially sonographically normal. Likewise, the possibility of inflammatory gastroenteropathy without evidence of mural changes cannot be excluded. Dietary indiscretion / intolerance, occult parasitism, or less likely Addison's Disease may also be possible. If persistent gastrointestinal signs, a GI panel to include PLI/TLI/Cobalamin/Folate as well as resting cortisol level would be warranted.

IMAGING PERFORMED BY

Sarah Pender, CVT

HOSPITAL NAME

SVS Imaging QC

REFERRING VET

Dr. Hartmann

Empirically, a limited antigen or hydrolyzed diet trial with potential long term dietary therapy, prophylactic deworming (Panacur 50 mg/kg SID x 5 consecutive days with repeat protocol in 3 weeks even if fecal testing is negative), high colony count probiotic (Provable or Visbiome), antibiotic trial and as needed gastrointestinal support with assessment of clinical response may prove beneficial. Intestinal biopsies may be indicated if GI signs continue despite empirical therapy.

INVOICE

13212

DATE

1/28/22



PATIENT

Cookie Giza

SPECIES

Canine

BREED

Schnauzer

SEX

SF

AGE

6 years

WEIGHT

24 lbs.

INTERPRETED BY

R. McKenzie Daniel,
DVM, DABVP
(Canine and Feline)

IMAGING PERFORMED BY

Sarah Pender, CVT

HOSPITAL NAME

SVS Imaging QC

REFERRING VET

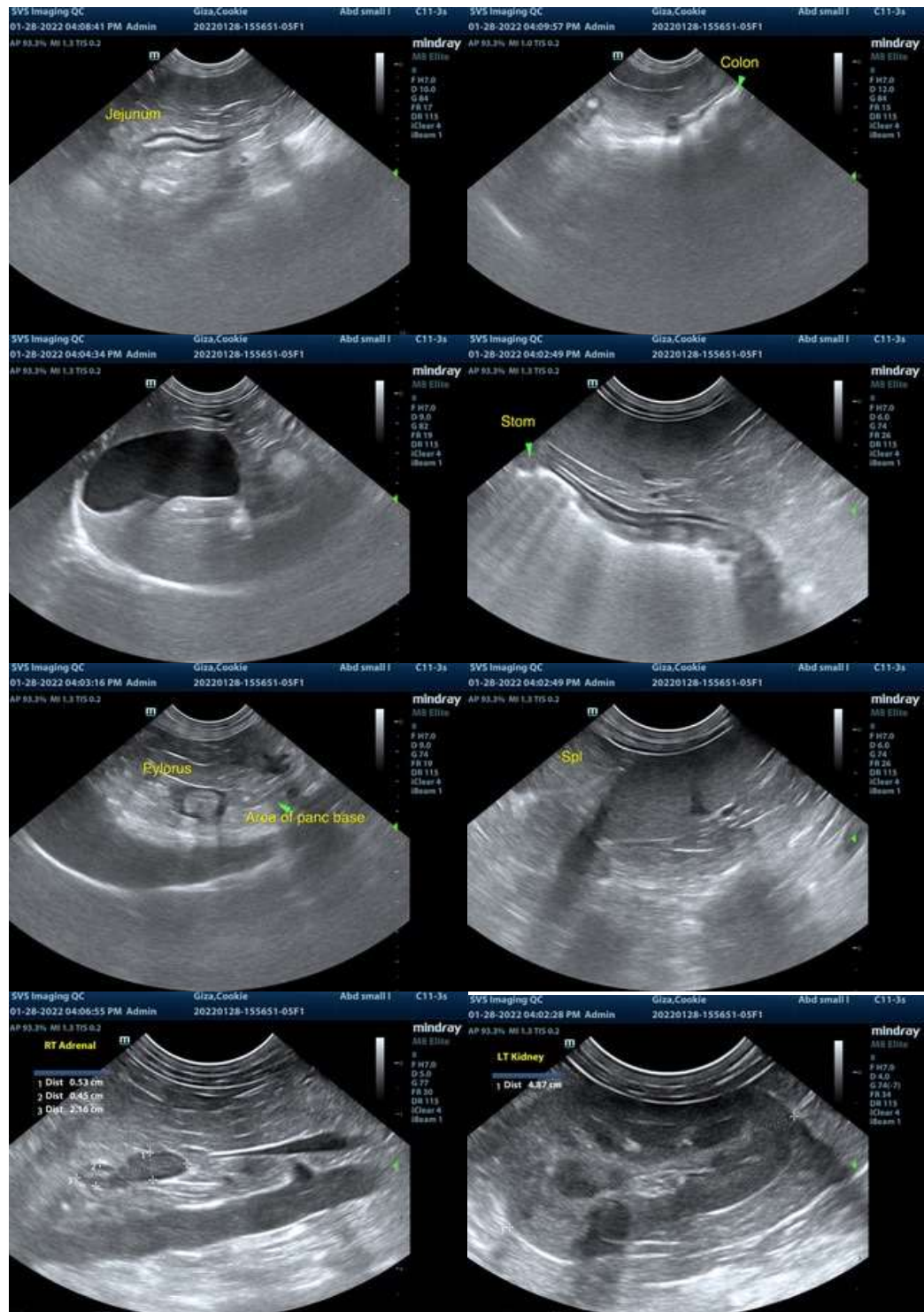
Dr. Hartmann

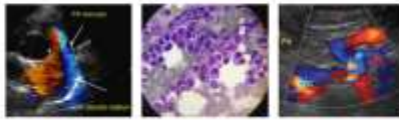INVOICE

13212

DATE

1/28/22





PATIENT

Cookie Giza

SPECIES

Canine

BREED

Schnauzer

SEX

SF

AGE

6 years

WEIGHT

24 lbs.

INTERPRETED BY

R. McKenzie Daniel,
DVM, DABVP
(Canine and Feline)

IMAGING PERFORMED BY

Sarah Pender, CVT

HOSPITAL NAME

SVS Imaging QC

REFERRING VET

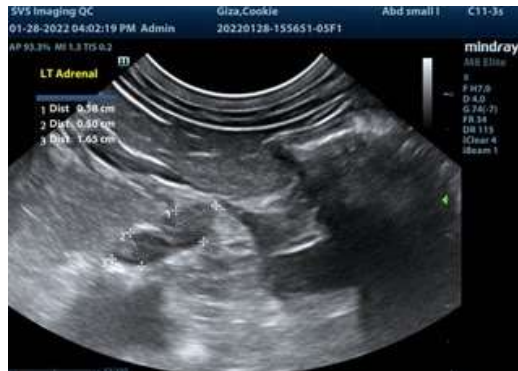Dr. Hartmann

INVOICE

13212

DATE

1/28/22



The information and recommendations provided are based on the images presented by the referring veterinarian/sonographer. No evaluation can be communicated regarding pathology that was not visible in the image/video clips provided.

Thank you for this referral. If the clinical or image interpretation does not parallel your findings or if I can be of any further assistance please contact me.

R. McKenzie Daniel, DVM, DABVP (Canine / Feline Practice)
info@SonoPath.com