



**PATIENT PRESENTING CLINICAL SIGNS**

Sophie Boudreau

History:

**SPECIES**

Canine

- Abdominal pain (cranial area)
- Xray Splenomegaly
- Meds: Levothyroxine

**BREED**

Labrador Mix

Abnormal PE/Chem/CBC/UA Results: pending.

**SEX**

Female Spayed

**AGE**

10y

**WEIGHT**

N/A

**ULTRASONOGRAPHIC EXAMINATION OF THE HEART & ABDOMEN**

CANINE CARDIAC PARAMETERS	MR VMAX (m/s)	TR VMAX (m/s)	LA/AO (M-Mode)	LA/AO (Heart Base; Swe)	FS (%)	EF (%)	EPSS (cm)
NORMAL PARAMETER	4.5-5.5	<2.7	1.3	Up to 1.6	28-40	40-100	<0.6
PATIENT	--	--	--	1.1	46	79	0.3
CANINE CARDIAC PARAMETERS	HR (BPM)	AV VMAX (m/s)	PV MAX (m/s)	BODY WEIGHT (kg)	LAD LA MAX 4 Chamber	LVIDd Avg; 2D and m-mode short axis (cm)	LVIDs Avg; 2D and m-mode short axis (cm)
NORMAL PARAMETER	50-100	0.7-1.7	0.7-1.6				
PATIENT	NM	2.0	1.1	--	3.6	3.3	--

**INTERPRETED BY**

R. McKenzie Daniel, DVM, DABVP (Canine and Feline)

**IMAGING PERFORMED BY**

Becca Hamilton

**HOSPITAL NAME**

All Creatured Denville

**REFERRING VET**

Dr. Silas

**INVOICE**

13136

**DATE**

1/27/26

**Cardiac Presentation**

The echocardiogram in this patient demonstrated normal **left atrial** size based on 2 separate methods of LA evaluation. The cranial and caudal **mitral** valve leaflets presented normal linear structure, extension in systole, and union in diastole with normal kinesis. The **left ventricle** presented thicknesses with linear contour and was not dilated nor restricted. The **myocardium** presented normal echogenicity without subjective evidence of significant fibrotic or ischemic disease. **Contractility** of the ventricular walls was adequate and in normal range for this patient evidenced by the fractional shortening measurement and subjective evaluation of the different regions of the myocardium. The **left ventricular outflow** tract demonstrated normal laminar flow and subjective structural integrity. The **right atrium** and auricle revealed normal size, structure and content. No evidence of masses was noted. **Tricuspid** valvular assessment demonstrated adequate linear morphology and kinesis. The **right ventricle** was of normal size (1/3 diameter of LV), chordae structure, myocardial echogenicity and thickness. **Pulmonary outflow** tract assessment revealed normal valve structure, laminar flow, and diameter (approx.1:1 pa/ao ratio). No visible **pericardial** or free pleura fluid was noted. The cranial **mediastinum and pericardial and extra-cardiac** regions were free of masses in the visible window.



**PATIENT**

Sophie Boudreau

**SPECIES**

Canine

**BREED**

Labrador Mix

**SEX**

Female Spayed

**AGE**

10y

**WEIGHT**

N/A

**INTERPRETED BY**

R. McKenzie Daniel,  
 DVM, DABVP  
 (Canine and Feline)

**IMAGING PERFORMED BY**

Becca Hamilton

**HOSPITAL NAME**

All Creatured Denville

**REFERRING VET**

Dr. Silas

**INVOICE**

13136

**DATE**

1/27/26

**Urinary System**

The urinary bladder, trigone, cystourethral junction, and visible pelvic urethra to a depth of 3.0 cm exhibited normal thickness and tone. Anechoic urine was present in the lumen with no uroliths or sediment. The ureteral papillae were normal. The ureters were not visible which is normal. No evidence of inflammatory or neoplastic changes were noted.

The area of the aortic trifurcation was free of pathology.

Normal size and margination was present in the kidneys. A normal 1:3 cortex / medulla ratio was maintained. The medulla and cortices were uniform in texture with some increased echogenicity and mild loss of corticomedullary symmetry and definition expected for the age of the patient. No evidence of pelvic dilation was present. The left kidney measured 6.4 cm in length. The right kidney measured 6.4 cm in length.

**Adrenal Glands**

The left adrenal gland was uniform in size and contour with a uniformly hypoechoic parenchyma. The left adrenal gland measured 0.55 cm width at the caudal pole. The right adrenal gland was uniform in size and contour with a uniformly hypoechoic parenchyma. The right adrenal gland measured 0.62 cm width at the caudal pole.

**Spleen**

The spleen exhibited a finely textured and homogenous parenchyma which was hyperechoic to the liver and renal cortical parenchyma. Normal vascularity present. The capsule was smooth and regular without apparent expansion. The splenic vasculature at the hilus was normal in volume with no evidence of congestion or thrombosis. Acute to chronic inflammatory, neoplastic, or benign parenchyma changes were not noted.

**Liver**

The liver presented subjective mildly enlarged in size. The parenchyma of the liver was subjectively normal in echogenicity compared to the spleen and renal cortices. The liver parenchyma was uniform with a mildly coarse echotexture. The capsule of the liver was symmetrically rounded to mildly swollen in margination. The hepatic and portal vasculature were normal in appearance without signs of congestion. The gallbladder was non distended in size with mild, non-organized, echogenic, nonmineralized biliary sludge. The cystic duct and common bile ducts were normal without evidence of dilation.

**Gastrointestinal**

The stomach presented intact wall layering with a normal wall layer ratio. The lumen of the stomach was empty with no signs of ileus, obstruction or foreign material.

The small intestine presented intact wall layering with 1:3 muscularis/mucosa ratio. The lumen of the small intestine was empty with no signs of ileus, obstruction or foreign material.

Normal visible colon wall layers were present with apparent formed feces in lumen.



**PATIENT**

Sophie Boudreau

**SPECIES**

Canine

**BREED**

Labrador Mix

**SEX**

Female Spayed

**AGE**

10y

**WEIGHT**

N/A

**INTERPRETED BY**

R. McKenzie Daniel,  
 DVM, DABVP  
 (Canine and Feline)

**IMAGING PERFORMED BY**

Becca Hamilton

**HOSPITAL NAME**

All Creatured Denville

**REFERRING VET**

Dr. Silas

**INVOICE**

13136

**DATE**

1/27/26

**Pancreas**

The parenchyma of the left limb, body and right limb of the pancreas presented isoechoic to the adjacent omental fat. A normal curvilinear capsule contour of the pancreas was present. The visible pancreatic duct was normal. No signs of active inflammation or neoplastic disease was evident.

**Free Abdomen**

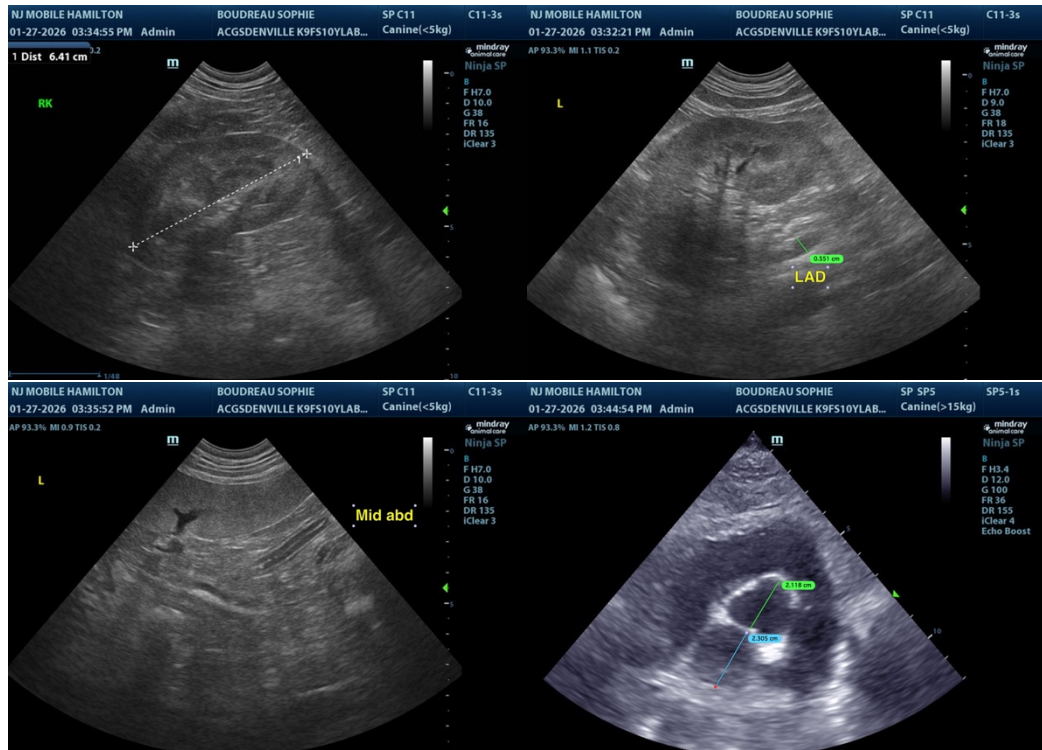
No overt lymphadenopathy or peritoneal effusion was present.

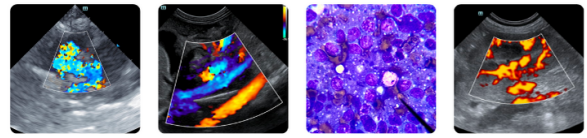
**ULTRASONOGRAPHIC FINDINGS**

- Normal echocardiogram
- Mild age-related renal changes
- Subjective mild hepatomegaly – benign
- Mild, non-organized gallbladder debris (non-mucocele)
- Normal spleen

**INTERPRETATION OF THE FINDINGS & FURTHER RECOMMENDATIONS**

No evidence of cardiac or abdominal viscera pathology with largely mild geriatric abdomen. The mild hepatomegaly is nonspecific yet consistent with benign criteria and may suggest vacuolar changes or non-obstructive cholestasis. Correlation with pending lab work, primarily to assess for evidence of hepatic inflammation is recommended. A definitive cause of abdominal pain was not obvious. No evidence of abdominal masses or neoplastic criteria.





**PATIENT**

Sophie Boudreau

**SPECIES**

Canine

**BREED**

Labrador Mix

**SEX**

Female Spayed

**AGE**

10y

**WEIGHT**

N/A

**INTERPRETED BY**

R. McKenzie Daniel,  
 DVM, DABVP  
 (Canine and Feline)

**IMAGING PERFORMED BY**

Becca Hamilton

**HOSPITAL NAME**

All Creatured Denville

**REFERRING VET**

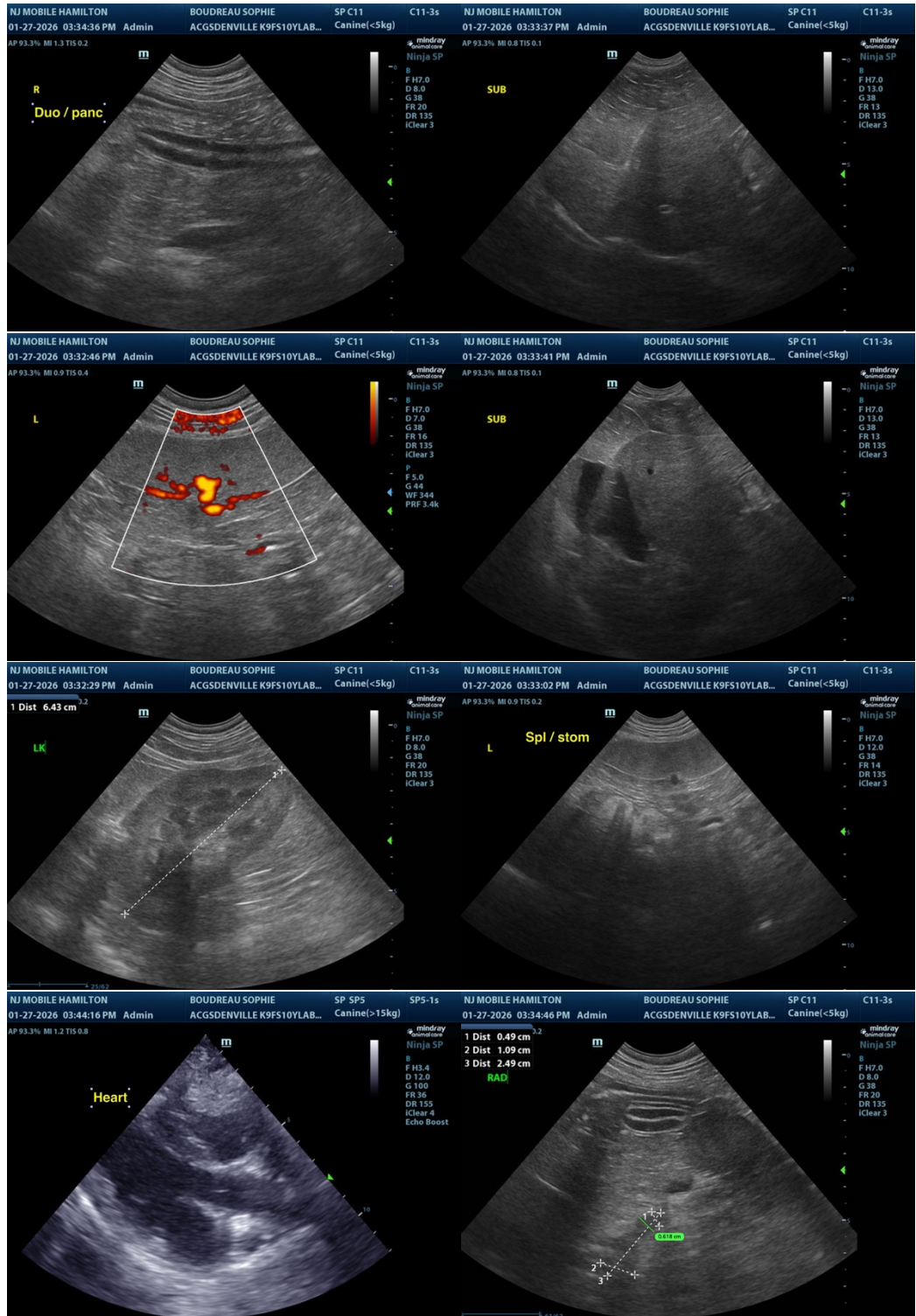
Dr. Silas

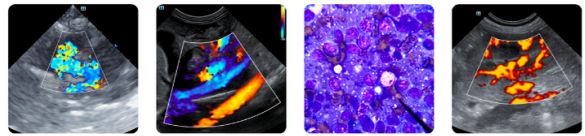
**INVOICE**

13136

**DATE**

1/27/26





**PATIENT**

Sophie Boudreau

**SPECIES**

Canine

**BREED**

Labrador Mix

**SEX**

Female Spayed

**AGE**

10y

**WEIGHT**

N/A

**INTERPRETED BY**

R. McKenzie Daniel,  
DVM, DABVP  
(Canine and Feline)

**IMAGING  
PERFORMED BY**

Becca Hamilton

**HOSPITAL NAME**

All Created Denville

**REFERRING VET**

Dr. Silas

**INVOICE**

13136

**DATE**

1/27/26

The information and recommendations provided are based on the images presented by the referring veterinarian/sonographer. No evaluation can be communicated regarding pathology that was not visible in the image/video clips provided.

Thank you for this referral. If the clinical or image interpretation does not parallel your findings or if I can be of any further assistance, please contact me.

R. McKenzie Daniel, DVM, DABVP (Canine / Feline Practice)

[info@sonopath.com](mailto:info@sonopath.com)