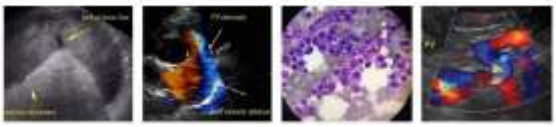

PATIENT

Sydney Cooney

SPECIES

Canine

BREED

Shepherd

SEX

FS

AGE

11 years

WEIGHT

83 lbs.

INTERPRETED BY

R. McKenzie Daniel, DVM, DABVP

IMAGING PERFORMED BY

Crystal Hill

HOSPITAL NAME

Dog and Cat Clinic of Niagara

REFERRING VET

Dr. Aziz

INVOICE

13194

DATE

1/27/22

PRESENTING CLINICAL SIGNS

Second opinion, urinating blood and not resolving on antibiotics. Has been on and is still on Clavamox and Meloxadin. Recurrent UTI
Abnormal PE/Chem/CBC/UA Results: increased creatinine 350(44-159) and increased urea 11.9(2.5-9.6). U/A - Ery 250/ul, leuks 500/ul, no bacteria seen, struvite crystals 6-20/hpf, specific grav 1.040.

ULTRASONOGRAPHIC EXAMINATION OF THE ABDOMEN

Urinary System

The bladder exhibited moderate distention yet subjective normal tone. Anechoic urine with very minor, nondependent, particulate sediment was present. The cystourethral junction and proximal urethra exhibited mild dilation with retained urine. Ill-visualized, nonhomogeneous to pinpoint hyperechoic echo was present within the deep proximal urethral lumen, measuring potentially 4.0-5.0 cm in diameter and 1.3 cm width.

The area of the aortic trifurcation was free of pathology.

Normal size and margination were present in the left kidney. A normal 1:3 cortex / medulla ratio was maintained. The medulla and cortices were uniform in texture with some increased echogenicity and mild to moderate loss of corticomedullary symmetry and definition expected for the age of the patient. Mild hydronephrosis exhibiting mild pelvic urine distention extending mildly into the lateral diverticuli was present. The left kidney measured 8.2 cm in length.

Normal size and margination were present in the right kidney. A normal 1:3 cortex / medulla ratio was maintained. The medulla and cortices were uniform in texture with some increased echogenicity and moderate loss of corticomedullary symmetry and definition expected for the age of the patient. Mild lateral diverticuli fluid dilation was present. The right kidney measured 8.6 cm in length.

Adrenal Glands

The left adrenal gland was uniform in size and contour with a uniformly hypoechoic parenchyma. The left adrenal gland measured 2.9 cm length x 0.91 cm width at the caudal pole. The right adrenal gland was Indistinctly visualized, subjectively measuring 0.95 cm width at the caudal pole.

Spleen

The spleen exhibited generalized enlargement with medial folding of the cranial spleen. A primarily finely textured parenchyma which was hyperechoic to the liver and renal cortical parenchyma was present. Intermittent hyperechoic non-expansive nodules were present in the spleen. The capsule was smooth and regular without apparent expansion. The splenic vasculature at the hilus was normal in volume with no evidence of congestion or thrombosis. The parenchymal heterogeneity is likely consistent with benign changes such as extramedullary hematopoiesis or age-related remodeling with minor potential for inflammatory or neoplastic disease.

Liver/ Gallbladder

The liver was subjectively normal in size, structure, and contour. The liver parenchyma was mildly nonuniform and hypoechoic to the spleen with a moderate coarse echotexture and subjective mild to

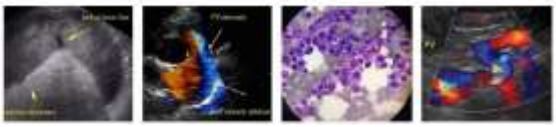

PATIENT

Sydney Cooney

SPECIES

Canine

BREED

Shepherd

SEX

FS

AGE

11 years

WEIGHT

83 lbs.

INTERPRETED BY

R. McKenzie Daniel, DVM, DABVP

IMAGING PERFORMED BY

Crystal Hill

HOSPITAL NAME

Dog and Cat Clinic of Niagara

REFERRING VET

Dr. Aziz

INVOICE

13194

DATE

1/27/22

benign parenchymal remodeling. The hepatic and portal vasculature were normal in appearance without signs of congestion. The gallbladder was non-distended in size with mild gallbladder debris. The cystic and common bile ducts were normal.

Gastrointestinal

The stomach presented intact wall layering with a normal wall layer ratio. The lumen of the stomach was empty with no signs of ileus, obstruction, or foreign material.

The small intestine presented intact wall layering with 1:3 muscularis/mucosa ratio. The lumen of the small intestine was empty with no signs of ileus, obstruction, or foreign material.

Normal visible colon wall layers were present with apparent formed feces in lumen.

Pancreas

The parenchyma of the left limb, body, and right limb of the pancreas presented isoechoic to the adjacent omental fat. A normal curvilinear capsule contour of the pancreas was present. The visible pancreatic duct was normal. No signs of active inflammation or neoplastic disease were evident.

Free Abdomen

No overt lymphadenopathy or peritoneal effusion was present.

ULTRASONOGRAPHIC FINDINGS

Primary Findings

- Proximal urethral mass
- Distended urinary bladder
- Bilateral chronic renal changes with mild left kidney and possible mild right kidney hydronephrosis
- Mild splenomegaly with intermittent subjectively benign nodules - hyperplasia, hematopoiesis, breed associated hypersplenism, with probable benign myelolipomas, potential for splenic neoplasia is considered a less likely differential diagnosis
- Hepatic parenchymal remodeling, minor gallbladder debris (non-mucocele)

INTERPRETATION OF THE FINDINGS & FURTHER RECOMMENDATIONS

The proximal urethral mass is most consistent with neoplastic process, with transitional cell carcinoma considered a top differential diagnosis. This is suspected to be owing somewhat to urinary outflow obstruction with secondary distended urinary bladder and concurrent potential mild bilateral hydronephrosis. Screening BRAF Assay may be considered. Referral for further clarification, potential stent placement, and oncology consultation may be considered.

SonoPath
Clinical Sonography & Telecytology
EDUCATIONAL TELECONSULTATION SERVICES™
1-800-838-4268 info@sonopath.com SonoPath.com

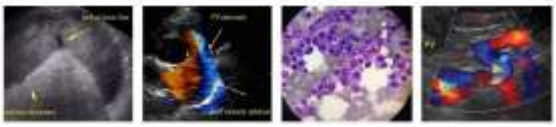

THE FOCAL ZONE
IMAGING PERFORMED BY
289-808-2608 info@thefocalzone.com

PATIENT

Sydney Cooney

SPECIES

Canine

BREED

Shepherd

SEX

FS

AGE

11 years

WEIGHT

83 lbs.

INTERPRETED BY

R. McKenzie Daniel, DVM, DABVP

IMAGING PERFORMED BY

Crystal Hill

HOSPITAL NAME

Dog and Cat Clinic of Niagara

REFERRING VET

Dr. Aziz

INVOICE

13194

DATE

1/27/22

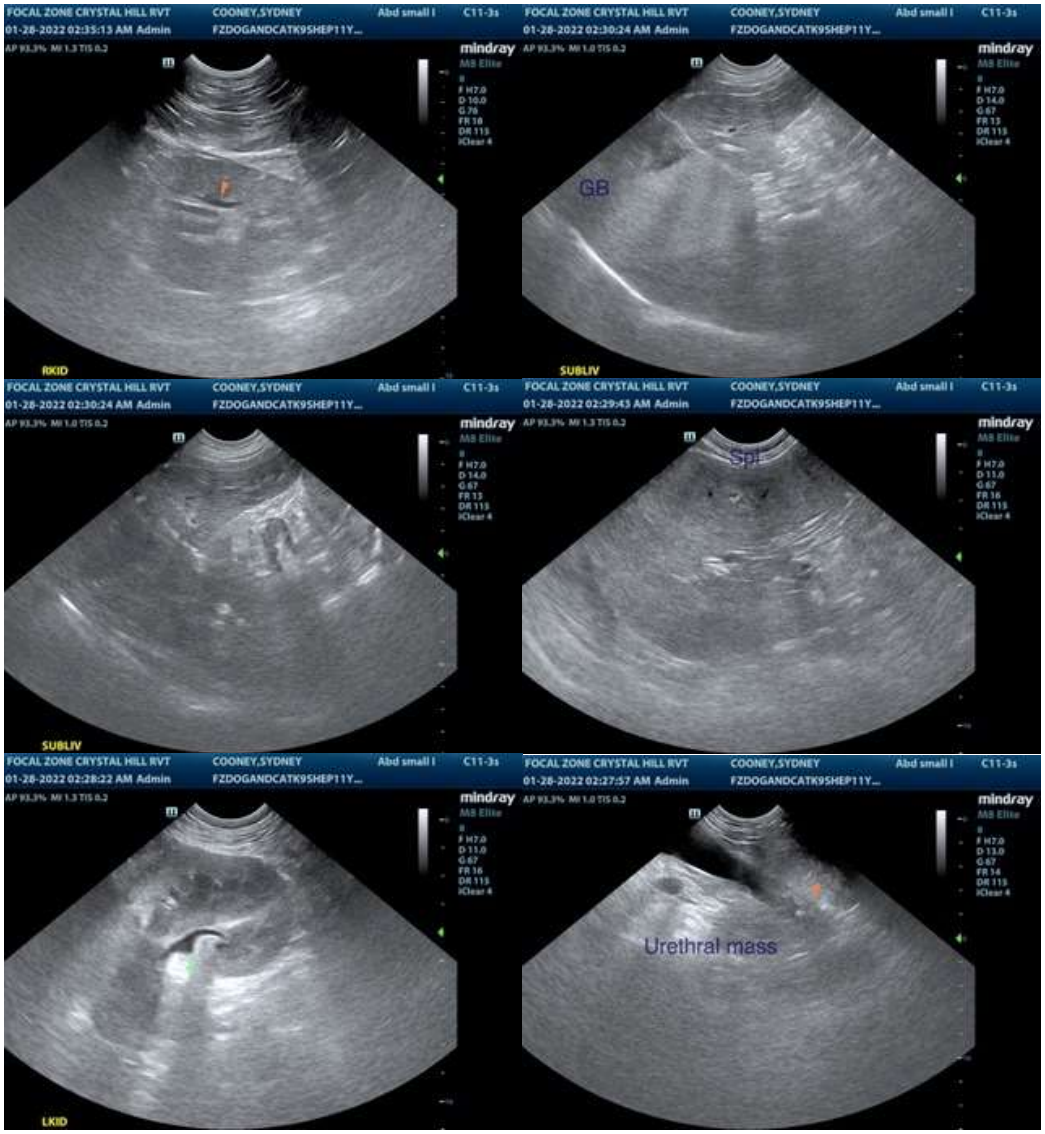

SonoPath
Clinical Sonography & Telecytology
EDUCATIONAL TELECONSULTATION SERVICES™
1-800-838-4268 info@sonopath.com SonoPath.com

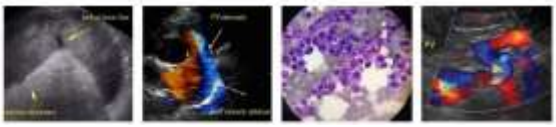

THE FOCAL ZONE
IMAGING PERFORMED BY
289-808-2608 info@thefocalzone.com

PATIENT

Sydney Cooney

SPECIES

Canine

BREED

Shepherd

SEX

FS

AGE

11 years

WEIGHT

83 lbs.

INTERPRETED BY

R. McKenzie Daniel, DVM, DABVP

IMAGING PERFORMED BY

Crystal Hill

HOSPITAL NAME

Dog and Cat Clinic of Niagara

REFERRING VET

Dr. Aziz

INVOICE

13194

DATE

1/27/22

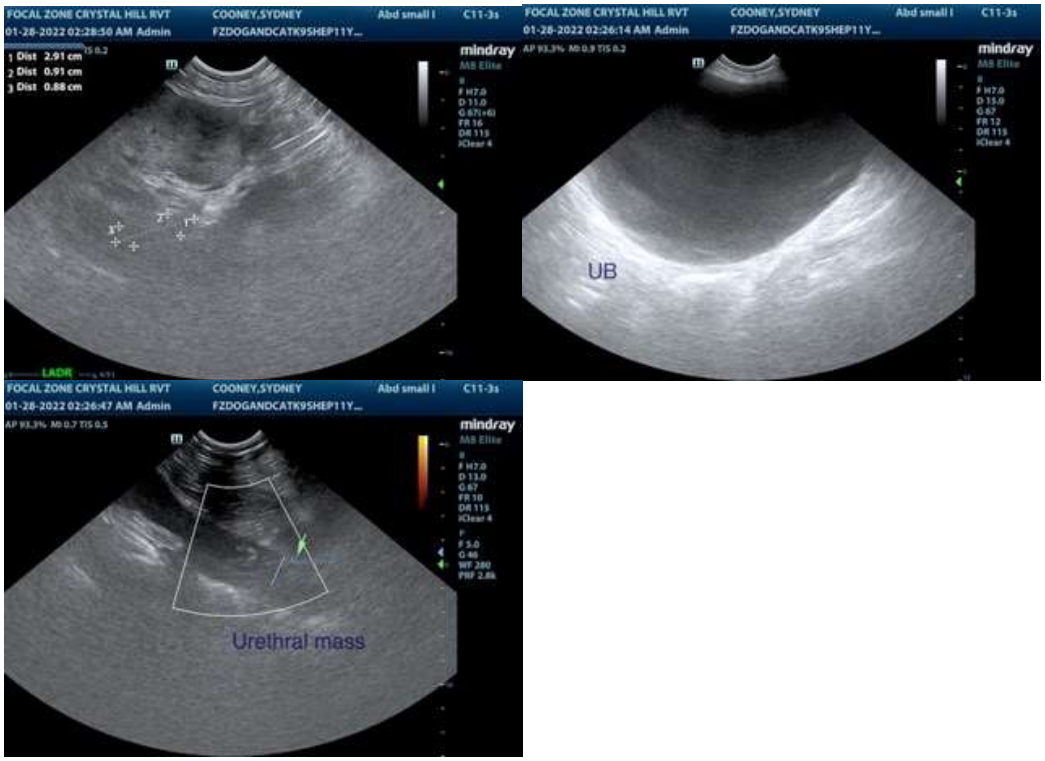

The information and recommendations provided are based on the images presented by the referring veterinarian/sonographer. No evaluation can be communicated regarding pathology that was not visible in the image/video clips provided.

Thank you for this referral. If the clinical or image interpretation does not parallel your findings or if I can be of any further assistance please contact me.

R. McKenzie Daniel, DVM, DABVP (Canine / Feline Practice)
info@SonoPath.com