



PATIENT

Reign Dimaggio

PRESENTING CLINICAL SIGNS

History: bloody diarrhea and vomiting

SPECIES

Canine

ULTRASONOGRAPHIC EXAMINATION OF THE ABDOMEN

Urinary System

The urinary bladder, trigone, cystourethral junction, and visible pelvic urethra to a depth of – cm exhibited normal thickness and tone. Anechoic urine was present in the lumen with no uroliths or sediment. The ureteral papillae were normal. The ureters were not visible which is normal. No evidence of inflammatory or neoplastic changes were noted.

BREED

Bichon Frise

Normal size and margination was present in the kidneys. A normal 1:3 cortex / medulla ratio and normal corticomedullary definition were maintained. The echogenicity of the cortex was similar to or slightly less than normal liver parenchyma while the medulla echogenicity was hypoechoic to the cortex with no evidence of pelvic dilation. The left kidney measured 3.7 cm in length. The right kidney measured 3.3 cm in length.

SEX

Neutered Male

AGE

1 Years

Adrenal Glands

The left adrenal gland was uniform in size and contour with a uniformly hypoechoic parenchyma. The left adrenal gland measured 0.44 cm width at the caudal pole and 0.50 cm width at the cranial pole.

WEIGHT

11.9 Lbs.

The right adrenal gland was uniform in size and contour with a uniformly hypoechoic parenchyma. The right adrenal gland measured 0.54 cm width at the caudal pole and 0.55 cm width at the cranial pole.

Spleen

The spleen exhibited a finely textured and homogenous parenchyma which was hyperechoic to the liver and renal cortical parenchyma. The capsule was smooth and regular without apparent expansion. The splenic vasculature at the hilus was normal in volume with no evidence of congestion or thrombosis. Acute to chronic inflammatory, neoplastic, or benign parenchyma changes were not noted.

INTERPRETED BY

R. McKenzie Daniel,
DVM, DABVP
(Canine and Feline)

Liver

The liver was subjectively normal in size, structure, and contour. The liver parenchyma was uniform and hypoechoic to the spleen with a mild coarse echotexture. The hepatic and portal vasculature were normal in appearance without signs of congestion. The gallbladder was non-distended in size with thin walls and primarily anechoic luminal content. The cystic and common bile ducts were normal.

IMAGING PERFORMED BY

Jenn

HOSPITAL NAME

Rockaway AH

Gastrointestinal

The stomach presented intact wall layering with a normal wall layer ratio. Minor retained nonshadowing ingesta/chyme was present. The gastric body wall measured 0.22 cm.

REFERRING VET

Dr. Maniar

The small intestine presented intact wall layering with 1:3 muscularis/mucosa ratio. The lumen of the small intestine was empty with no signs of ileus, obstruction or foreign material. The duodenum wall measured 0.28 cm. The jejunum wall measured 0.25 cm.

INVOICE

13645

The colon revealed intact yet subjective mild prominent wall layering with semi formed feces.

DATE

1/27/22

Pancreas



PATIENT

Reign Dimaggio

The parenchyma of the left limb, body and right limb of the pancreas presented isoechoic to the adjacent omental fat. A normal curvilinear capsule contour of the pancreas was present. The visible pancreatic duct was normal. No signs of active inflammation or neoplastic disease was evident.

SPECIES

Canine

Free Abdomen

No overt lymphadenopathy or peritoneal effusion was present.

BREED

Bichon Frise

ULTRASONOGRAPHIC FINDINGS

- Gastroenterocolitis pattern with potential mild gastric hypomotility

SEX

Neutered Male

INTERPRETATION OF THE FINDINGS & FURTHER RECOMMENDATIONS

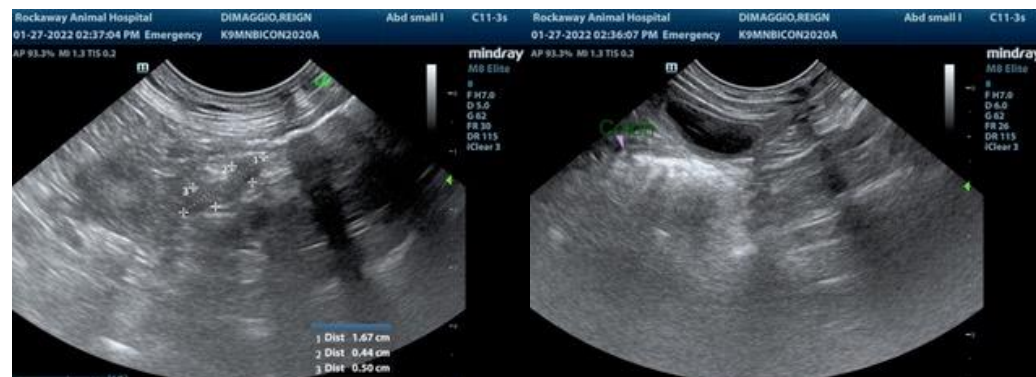
No overt evidence of significant visceral, specifically gastrointestinal pathology. Conservative therapy for acute gastroenteritis or hemorrhagic gastroenteritis should prove beneficial. Dietary indiscretion/food intolerance, occult parasitism, structurally insignificant gastroenterocolic disease may be considered if persistent gastrointestinal signs are noted. Resting cortisol to rule out occult Addison's disease may be considered if clinically indicated.

AGE

1 Years

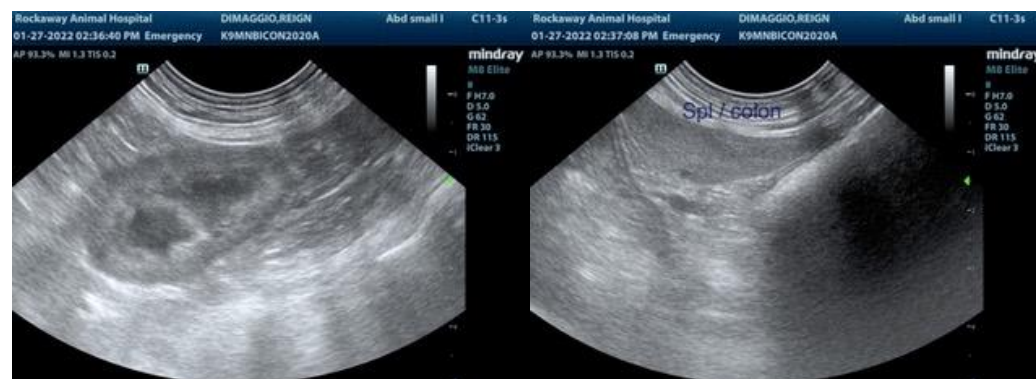
WEIGHT

11.9 Lbs.



INTERPRETED BY

R. McKenzie Daniel,
DVM, DABVP
(Canine and Feline)



IMAGING PERFORMED BY

Jenn

HOSPITAL NAME

Rockway AH

REFERRING VET

Dr. Maniar

INVOICE

13645

DATE

1/27/22



PATIENT

Reign Dimaggio

SPECIES

Canine

BREED

Bichon Frise

SEX

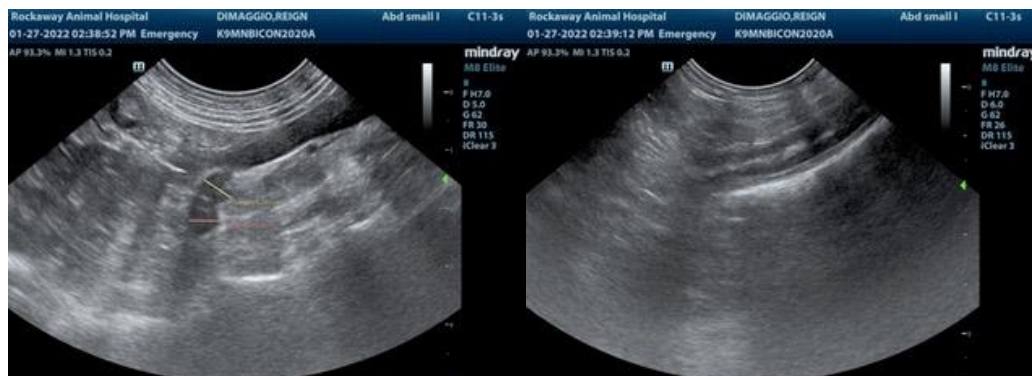
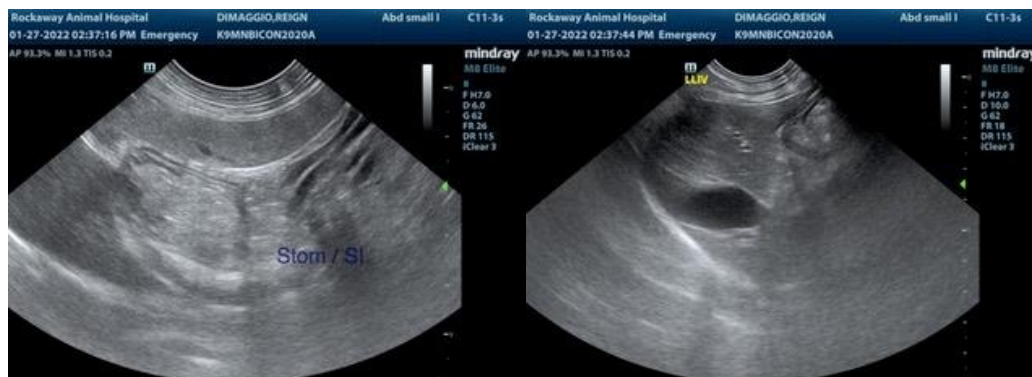
Neutered Male

AGE

1 Years

WEIGHT

11.9 Lbs.



INTERPRETED BY

R. McKenzie Daniel,
DVM, DABVP
(Canine and Feline)

IMAGING PERFORMED BY

Jenn

HOSPITAL NAME

Rockaway AH

REFERRING VET

Dr. Maniar

INVOICE

13645

DATE

1/27/22

The information and recommendations provided are based on the images presented by the referring veterinarian. No evaluation can be communicated regarding pathology that was not visible in the image/video clips provided.

Thank you for this referral. If the clinical or image interpretation does not parallel your findings or if I can be of any further assistance please contact me.

R. McKenzie Daniel, DVM, DABVP (Canine / Feline Practice)
info@SonoPath.com