



PATIENT PRESENTING CLINICAL SIGNS

Ginger Andrews History: one week of lethargy, inappetence and worsening ALT, A:P, bili, very jaundiced now meds: baytril, metronidazole, ursodiol, tramadol, just finished cerenia

SPECIES Abnormal PE/Chem/CBC/UA Results: please see attached labs

Canine **ULTRASONOGRAPHIC EXAMINATION OF THE ABDOMEN**

BREED *Urinary System*

Doodle The urinary bladder, trigone, cystourethral junction, and visible pelvic urethra to a depth of 3.0 cm exhibited normal thickness and tone. Anechoic urine was present in the lumen with no sediment or calculi. The ureteral papillae were normal. The ureters were not visible which is normal. No evidence of inflammatory or neoplastic changes were noted. Aortic trifurcation was normal.

SEX

Spayed Female Normal size and margination were present in the kidneys. A normal 1:3 cortex / medulla ratio and normal corticomedullary definition were maintained. The echogenicity of the cortex was similar to or slightly less than normal liver parenchyma while the medulla echogenicity was hypoechoic to the cortex with no evidence of pelvic dilation. The left kidney measured 6.9 cm in length. The right kidney measured 6.4 cm in length.

AGE

13 Years

Adrenal Glands

WEIGHT

32 kg

The left adrenal gland exhibited subjective mild subnormal size yet normal position, measuring 0.35 cm at the cranial pole and 0.42 cm at the caudal pole. This is nonspecific yet likely consistent with patient variant.

INTERPRETED BY

R. McKenzie Daniel, DVM,
DABVP (Canine and
Feline)

The right adrenal gland was uniform in size and contour with a uniformly hypoechoic parenchyma. The right adrenal gland measured 0.52 cm width at the caudal pole and 0.84 cm width at the cranial pole.

IMAGING

PERFORMED BY

Kelly Reschny

Spleen

The spleen exhibited a finely textured and homogenous parenchyma which was hyperechoic to the liver and renal cortical parenchyma. The capsule was smooth and regular without apparent expansion. The splenic vasculature at the hilus was normal in volume with no evidence of congestion or thrombosis. Acute to chronic inflammatory, neoplastic, or benign parenchyma changes were not noted.

HOSPITAL NAME

Hawkins AH

Liver

The liver exhibited subjective normal size with mild asymmetrical areas of caudal capsule asymmetry and generalized normal hepatic parenchyma echogenicity, exhibiting moderate coarse echotexture. Potential minor areas of parenchymal remodeling and mild increased prominence of portal vascular borders. No hepatic masses or nodules present.

REFERRING VET

Dr. Hawkins

The gallbladder exhibited normal subjective size without evidence of significant overdistention with primarily anechoic content with very mild nondependent particulate luminal debris. No evidence of gallbladder mineral. The area of the common bile duct was indistinctly visualized yet without evidence of common bile duct stasis, dilation or obstruction.

INVOICE

13644

Gastrointestinal

DATE

1/27/22

The stomach presented intact wall layering with a normal wall layer ratio. The lumen of the stomach was empty with no signs of ileus, obstruction or foreign material.



PATIENT

Ginger Andrews

The small intestine presented intact wall layering with 1:3 muscularis/mucosa ratio. The lumen of the small intestine was empty with no signs of ileus, obstruction or foreign material.

Normal visible colon wall layers were present with apparent formed feces in lumen.

SPECIES

Canine

Pancreas

The parenchyma of the left limb, body and right limb of the pancreas presented isoechoic to the adjacent omental fat. A normal curvilinear capsule contour of the pancreas was present. The visible pancreatic duct was normal. No signs of active inflammation or neoplastic disease was evident.

BREED

Doodle

ULTRASONOGRAPHIC FINDINGS

SEX

Spayed Female

- Hepatopathy
- Overtly normal gallbladder and area of the common bile duct- no overt post hepatic obstruction

AGE

13 Years

INTERPRETATION OF THE FINDINGS & FURTHER RECOMMENDATIONS

Although nonspecific, the appearance of the liver in conjunction with the liver enzymes are suggestive of nonspecific acute to subacute hepatitis (viral, bacterial), leptospirosis- potentially less likely given negative urine and blood PCR, toxins etc. Concurrent vacuolar hepatic changes, minor parenchymal remodeling and hepatic cholestasis suspected without overt evidence of posthepatic obstruction, occult hepatic neoplasia is considered a less likely differential diagnosis. Further assessment may include FNA cytology of the liver, assuming normal clotting status and if accessible. If evidence of hypoglycemia, xylitol toxicity could be considered yet glucose levels appear to be normal. Fasting a postprandial bile acid tests suggested to assess hepatic functionality.

WEIGHT

32 kg

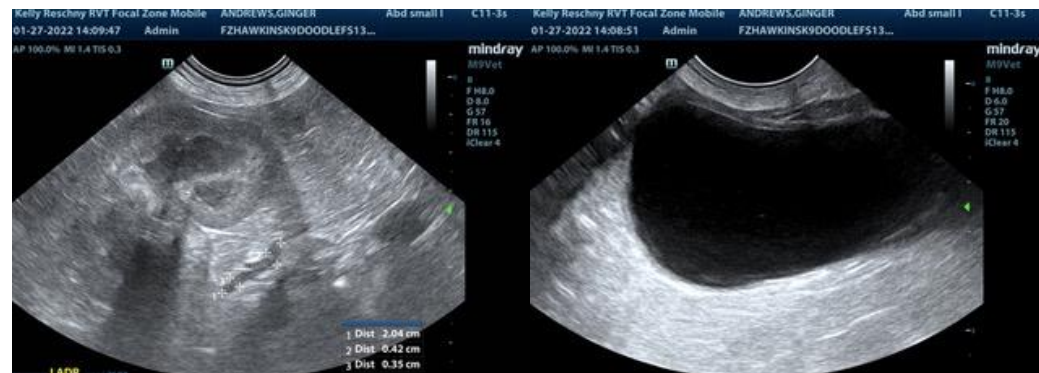INTERPRETED BY

R. McKenzie Daniel, DVM,
DABVP (Canine and
Feline)

Empirically, supportive care with IV fluids, hepatosupportive medications, including Denamarin and ursodiol, gastric protectants as well as empirical antibiotic protocol for acute hepatitis with assessment of hepatic response would be appropriate. Guarded prognosis depending additional diagnostics and in light of degree of hepatic enzyme elevations.

IMAGING PERFORMED BY

Kelly Reschny



HOSPITAL NAME

Hawkins AH

REFERRING VET

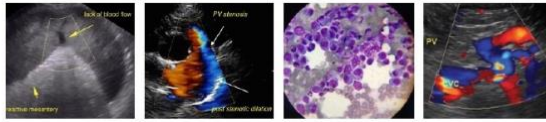
Dr. Hawkins

INVOICE

13644

DATE

1/27/22



PATIENT

Ginger Andrews

SPECIES

Canine

BREED

Doodle

SEX

Spayed Female

AGE

13 Years

WEIGHT

32 kg

INTERPRETED BY

R. McKenzie Daniel, DVM,
DABVP (Canine and
Feline)

**IMAGING
PERFORMED BY**

Kelly Reschny

HOSPITAL NAME

Hawkins AH

REFERRING VET

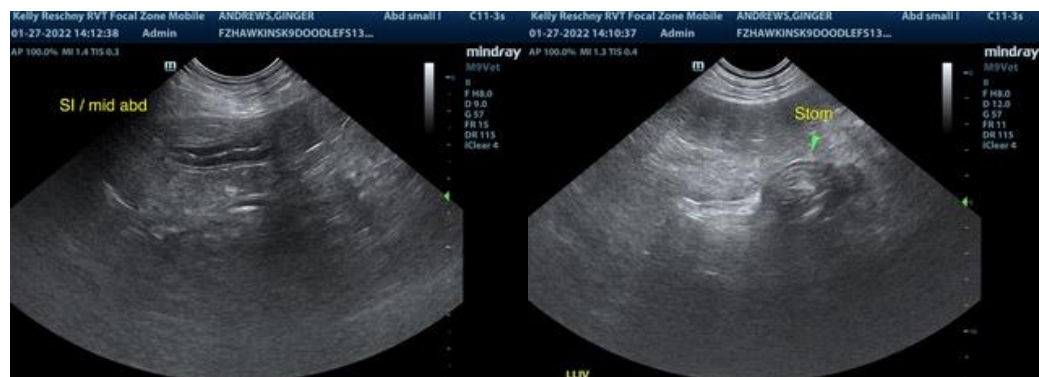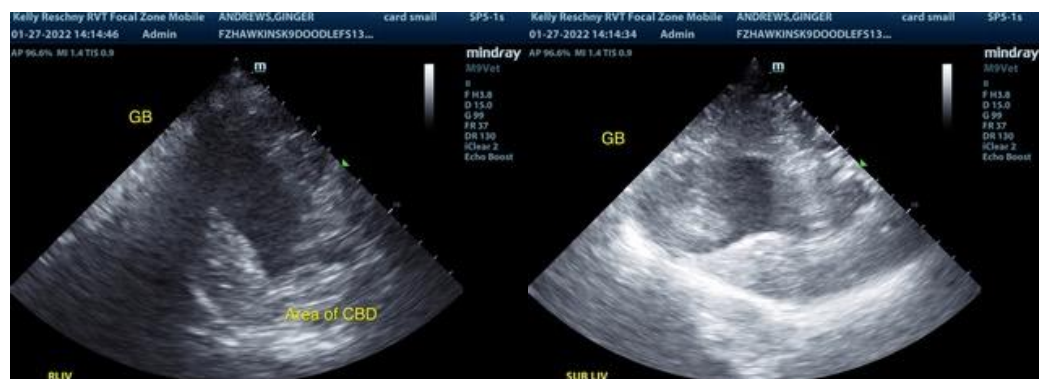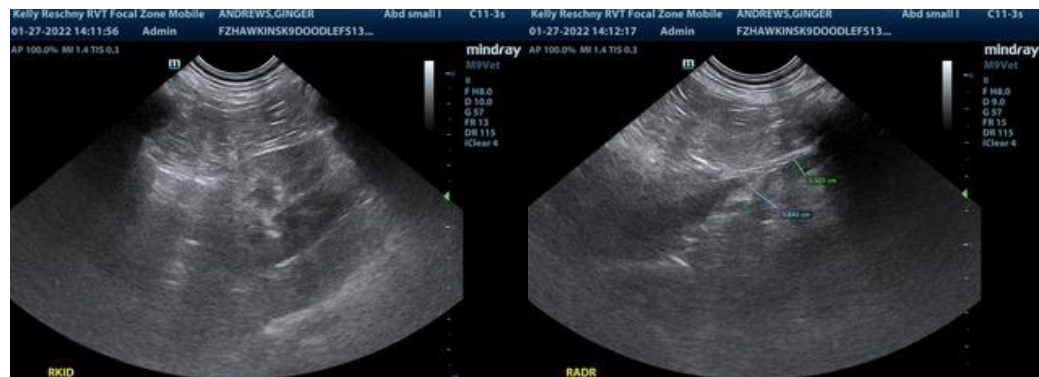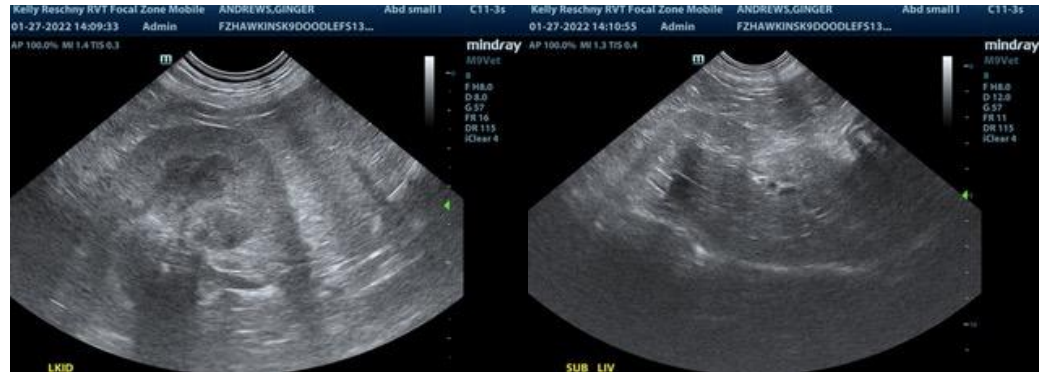Dr. Hawkins

INVOICE

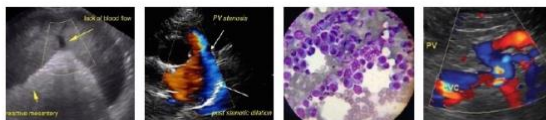
13644

DATE

1/27/22



The information and recommendations provided are based on the images presented by the



PATIENT

Ginger Andrews

SPECIES

Canine

BREED

Doodle

SEX

Spayed Female

AGE

13 Years

WEIGHT

32 kg

INTERPRETED BY

R. McKenzie Daniel, DVM,
DABVP (Canine and
Feline)

**IMAGING
PERFORMED BY**

Kelly Reschny

HOSPITAL NAME

Hawkins AH

REFERRING VET

Dr. Hawkins

INVOICE

13644

DATE

1/27/22

referring veterinarian. No evaluation can be communicated regarding pathology that was not visible in the image/video clips provided.

Thank you for this referral. If the clinical or image interpretation does not parallel your findings or if I can be of any further assistance please contact me.

R. McKenzie Daniel, DVM, DABVP (Canine / Feline Practice)
info@SonoPath.com