

PATIENT

Buddha Mulready

SPECIES

Feline

BREED

DLH

SEX

M/N

AGE

5 y, 8 mo

WEIGHT

13.3 lbs.

INTERPRETED BY

R. McKenzie Daniel, DVM,
 DABVP (Canine and Feline)

IMAGING PERFORMED BY

Pamela Harrigan, RDCS

HOSPITAL NAME

Anchor Animal
 Hospital

REFERRING VET

Nicole Mulready, DVM

INVOICE

15961

DATE

1/26/23

PRESENTING CLINICAL SIGNS

Occasional constipation episodes. No other clinical signs. Incidental increased proBNP on wellness bxw (124). Having bi-cavity exams. BP: 160,169, 170 mmHg. *Sedated with Gabapentin and Butorphanol.

ULTRASONOGRAPHIC EXAMINATION OF THE ABDOMEN

Urinary System

The urinary bladder, trigone, cystourethral junction, and visible pelvic urethra exhibited normal thickness and tone. Anechoic urine was present in the lumen with no uroliths or sediment. The ureteral papillae were normal. The ureters were not visible which is normal. No evidence of inflammatory or neoplastic changes was noted.

The area of the aortic trifurcation was free of pathology.

Normal size and margination were present in the kidneys. A normal 1:3 cortex / medulla ratio and normal corticomedullary definition were maintained. The echogenicity of the cortex was similar to or slightly less than normal liver parenchyma while the medulla echogenicity was hypoechoic to the cortex with no evidence of pelvic dilation. The left kidney measured 4.3 cm in length. The right kidney measured 4.4 cm in length.

Adrenal Glands

The left adrenal gland was uniform in size and contour with a uniformly hypoechoic parenchyma. The left adrenal gland measured 0.42 cm width. The right adrenal gland was uniform in size and contour with a uniformly hypoechoic parenchyma. The right adrenal gland measured 0.40 cm width.

Spleen

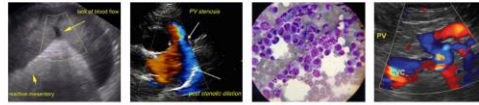
The spleen exhibited a finely textured and homogenous parenchyma which was hyperechoic to the liver and renal cortical parenchyma. The capsule was smooth and regular without apparent expansion. The splenic vasculature at the hilus was normal in volume with no evidence of congestion or thrombosis. Acute to chronic inflammatory, neoplastic, or benign parenchyma changes were not noted.

Liver/ Gallbladder

The liver was subjectively normal in size, structure, and contour. The liver parenchyma was uniform and hypoechoic to the spleen with a mild coarse echotexture. The hepatic and portal vasculature were normal in appearance without signs of congestion. The gallbladder was non-distended in size with thin walls and primarily anechoic luminal content. The cystic and common bile ducts were normal.

Gastrointestinal

The stomach presented intact wall layering with a normal wall layer ratio. The lumen of the stomach contained mild, nonshadowing ingesta along with luminal gas, probable recent meal ingestion without signs of gastric foreign material. No evidence of mechanical pyloric outflow obstruction was noted.



PATIENT

Buddha Mulready

SPECIES

Feline

BREED

DLH

SEX

M/N

AGE

5 y, 8 mo

WEIGHT

13.3 lbs.

The small intestine presented intact wall layering with 1:3 muscularis/mucosa ratio. The lumen of the small intestine was empty with no signs of ileus, obstruction, or foreign material.

Normal visible colon wall layers were present with apparent formed feces in lumen.

Pancreas

The parenchyma of the left limb, body, and right limb of the pancreas presented isoechoic to the adjacent omental fat. A normal curvilinear capsule contour of the pancreas was present. The visible pancreatic duct was normal. No signs of active inflammation or neoplastic disease were evident.

Free Abdomen

No omental masses, lymphadenopathy, or evidence of peritoneal effusion were noted.

ULTRASONOGRAPHIC FINDINGS

- Sonographically normal abdomen
- Normal gastrointestinal tract / colon with mild gastric ingesta - no evidence of constipation criteria

INTERPRETATION OF THE FINDINGS & FURTHER RECOMMENDATIONS

No sonographic evidence of significant visceral, specifically colonic, pathology. As-needed therapy for constipation if clinically indicated is suggested.

INTERPRETED BY

R. McKenzie Daniel, DVM,
 DABVP (Canine and Feline)

IMAGING PERFORMED BY

Pamela Harrigan, RDCS

HOSPITAL NAME

Anchor Animal
 Hospital

REFERRING VET

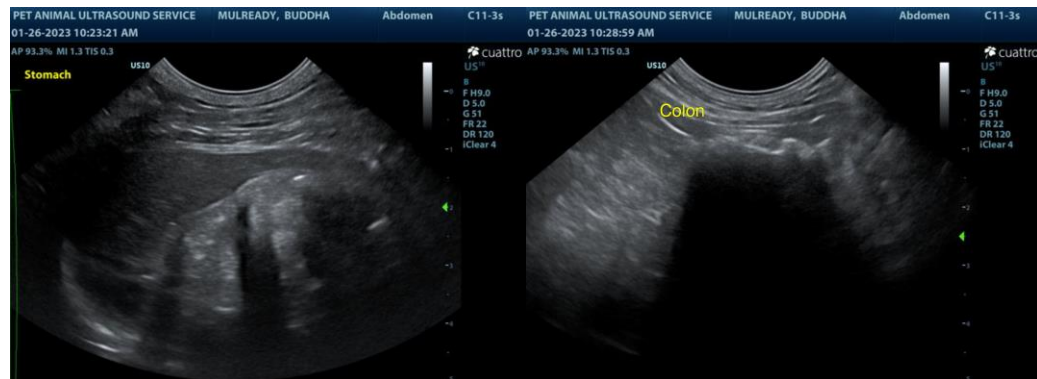
Nicole Mulready, DVM

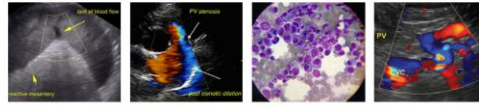
INVOICE

15961

DATE

1/26/23





PATIENT

Buddha Mulready

SPECIES

Feline

BREED

DLH

SEX

M/N

AGE

5 y, 8 mo

WEIGHT

13.3 lbs.

INTERPRETED BY

R. McKenzie Daniel, DVM,
 DABVP (Canine and Feline)

**IMAGING
 PERFORMED BY**

Pamela Harrigan, RDMS

HOSPITAL NAME

Anchor Animal
 Hospital

REFERRING VET

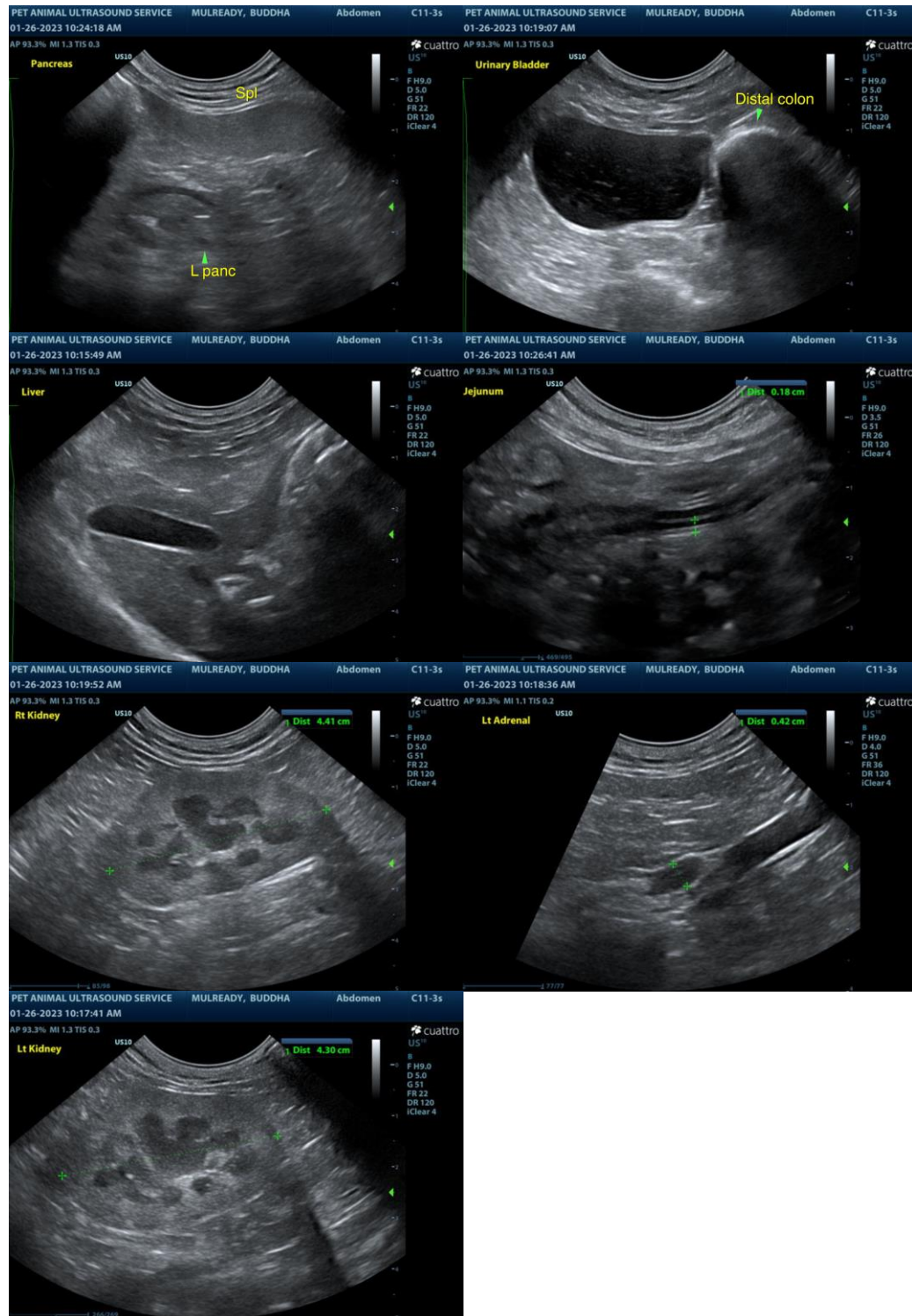
Nicole Mulready, DVM

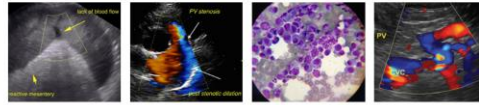
INVOICE

15961

DATE

1/26/23





PATIENT

Buddha Mulready

The information and recommendations provided are based on the images presented by the referring veterinarian/sonographer. No evaluation can be communicated regarding pathology that was not visible in the image/video clips provided.

SPECIES

Feline

Thank you for this referral. If the clinical or image interpretation does not parallel your findings or if I can be of any further assistance please contact me.

BREED

DLH

R. McKenzie Daniel, DVM, DABVP (Canine / Feline Practice)
info@SonoPath.com

SEX

M/N

AGE

5 y, 8 mo

WEIGHT

13.3 lbs.

INTERPRETED BY

R. McKenzie Daniel, DVM,
DABVP (Canine and Feline)

**IMAGING
PERFORMED BY**

Pamela Harrigan, RDMS

HOSPITAL NAME

Anchor Animal
Hospital

REFERRING VET

Nicole Mulready, DVM

INVOICE

15961

DATE

1/26/23