



**PATIENT**

Keira ODonohue

**SPECIES**

Canine

**BREED**

Siberian Husky

**SEX**

FS

**AGE**

11 years

**WEIGHT**

N/A

**INTERPRETED BY**

R. McKenzie Daniel,  
DVM, DABVP  
(Canine and Feline)

**IMAGING PERFORMED BY**

Diane McFadden

**HOSPITAL NAME**

Newton VH

**REFERRING VET**

Dr. Wyman-  
Greenwald

**INVOICE**

13150

**DATE**

1/26/22

**PRESENTING CLINICAL SIGNS**

hx of liver value elevation at rDVM. asymptomatic  
Abnormal PE/Chem/CBC/UA Results: May 2021: ALT 285, AST 56, A:LLKP 1509

**ULTRASONOGRAPHIC EXAMINATION OF THE ABDOMEN**

**Urinary System**

The urinary bladder, trigone, cystourethral junction, and visible pelvic urethra to a depth of 3.0 cm exhibited normal thickness and tone. Anechoic urine was present in the lumen with no uroliths or sediment. The ureteral papillae were normal. The ureters were not visible which is normal. No evidence of inflammatory or neoplastic changes was noted.

The area of the aortic trifurcation was free of pathology.

Normal size and margination were present in the kidneys. A normal 1:3 cortex / medulla ratio was maintained. The medulla and cortices were uniform in texture with some increased echogenicity and mild to moderate loss of corticomedullary symmetry and definition expected for the age of the patient. Areas of nonobstructive medullary mineral were noted in both kidneys. No evidence of pyelectasia was noted. The left kidney measured 6.6 cm in length. The right kidney measured 6.3 cm in length.

**Adrenal Glands**

The left adrenal gland was uniform in size and contour with a uniformly hypoechoic parenchyma. The left adrenal and 3.3 cm length x 0.65 cm width at the cranial pole. The right adrenal gland was uniform in size and contour with a uniformly hypoechoic parenchyma. The right adrenal gland measured 3.8 cm length x 0.66 cm width at the caudal pole.

**Spleen**

The spleen exhibited primarily finely textured parenchyma which was hyperechoic to the liver and renal cortical parenchyma. Mild generalized parenchyma heterogeneity was present without evidence of nodular changes. The capsule was smooth and regular without apparent expansion. The splenic vasculature at the hilus was normal in volume with no evidence of congestion or thrombosis. The parenchymal heterogeneity is likely consistent with benign changes such as extramedullary hematopoiesis or age-related remodeling with minor potential for inflammatory or neoplastic disease.

**Liver/ Gallbladder**

The liver exhibited generalized nonhomogeneous parenchyma with evidence of parenchymal remodeling. A large, expansive, mass appearing to derive from the caudal aspect of the liver extending into the cranial to mid-abdomen, measuring approximately 13.0 cm in diameter, was present. Subjectively, the mass appeared to exhibit similar echogenicity compared to adjacent hepatic parenchyma, yet extended into the area of the spleen with suspected splenic effacement. The gallbladder was non-distended in size with thin walls and primarily anechoic luminal content. The cystic and common bile ducts were normal.



**PATIENT**

Keira ODonohue

**SPECIES**

Canine

**BREED**

Siberian Husky

**SEX**

FS

**AGE**

11 years

**WEIGHT**

N/A

**INTERPRETED BY**

R. McKenzie Daniel,  
DVM, DABVP  
(Canine and Feline)

**IMAGING  
PERFORMED BY**

Diane McFadden

**HOSPITAL NAME**

Newton VH

**REFERRING VET**

Dr. Wyman-  
Greenwald

**INVOICE**

13150

**DATE**

1/26/22

***Gastrointestinal***

The stomach presented intact wall layering with a normal wall layer ratio. The lumen of the stomach was empty with no signs of ileus, obstruction, or foreign material.

The small intestine presented intact wall layering with 1:3 muscularis/mucosa ratio. The lumen of the small intestine was empty with no signs of ileus, obstruction, or foreign material.

Normal visible colon wall layers were present with apparent formed feces in lumen.

***Pancreas***

The parenchyma of the left limb, body, and right limb of the pancreas presented isoechoic to the adjacent omental fat. A normal curvilinear capsule contour of the pancreas was present. The visible pancreatic duct was normal. No signs of active inflammation or neoplastic disease were evident.

***Free Abdomen***

No overt lymphadenopathy or peritoneal effusion was present.

Rapid view of the heart revealed no evidence of pericardial masses or effusion in the visible window.

**ULTRASONOGRAPHIC FINDINGS**

***Primary Findings***

- Large, nonhomogeneous liver mass extending into cranial to mid-abdomen, hepatic parenchymal remodeling in non-associated liver
- Subjective mild age-related splenic parenchyma - subjectively benign
- Bilateral chronic renal changes with nonobstructive medullary mineral

**INTERPRETATION OF THE FINDINGS & FURTHER RECOMMENDATIONS**

A minor potential for primary splenic origin of the mass, given suspected effacement of the spleen and overall size of the mass, is considered a less likely differential diagnosis. Benign vs. neoplastic etiologies for the mass are possible although neoplasia is favored. Subjectively, the hepatic mass appears to be potentially amendable to surgical resection. Further assessment and surgical planning with abdominal CT could be considered if surgery is a potential option in this case. Hepatic parenchymal biopsies are recommended if surgery is elected. Sonographic monitoring of the mass with recheck sooner if clinical signs consistent with hepatic disease or potential gastrointestinal displacement secondary to the mass are noted, would be a more conservative approach.



**PATIENT**

Keira ODonohue

**SPECIES**

Canine

**BREED**

Siberian Husky

**SEX**

FS

**AGE**

11 years

**WEIGHT**

N/A

**INTERPRETED BY**

R. McKenzie Daniel,  
DVM, DABVP  
(Canine and Feline)

**IMAGING PERFORMED BY**

Diane McFadden

**HOSPITAL NAME**

Newton VH

**REFERRING VET**

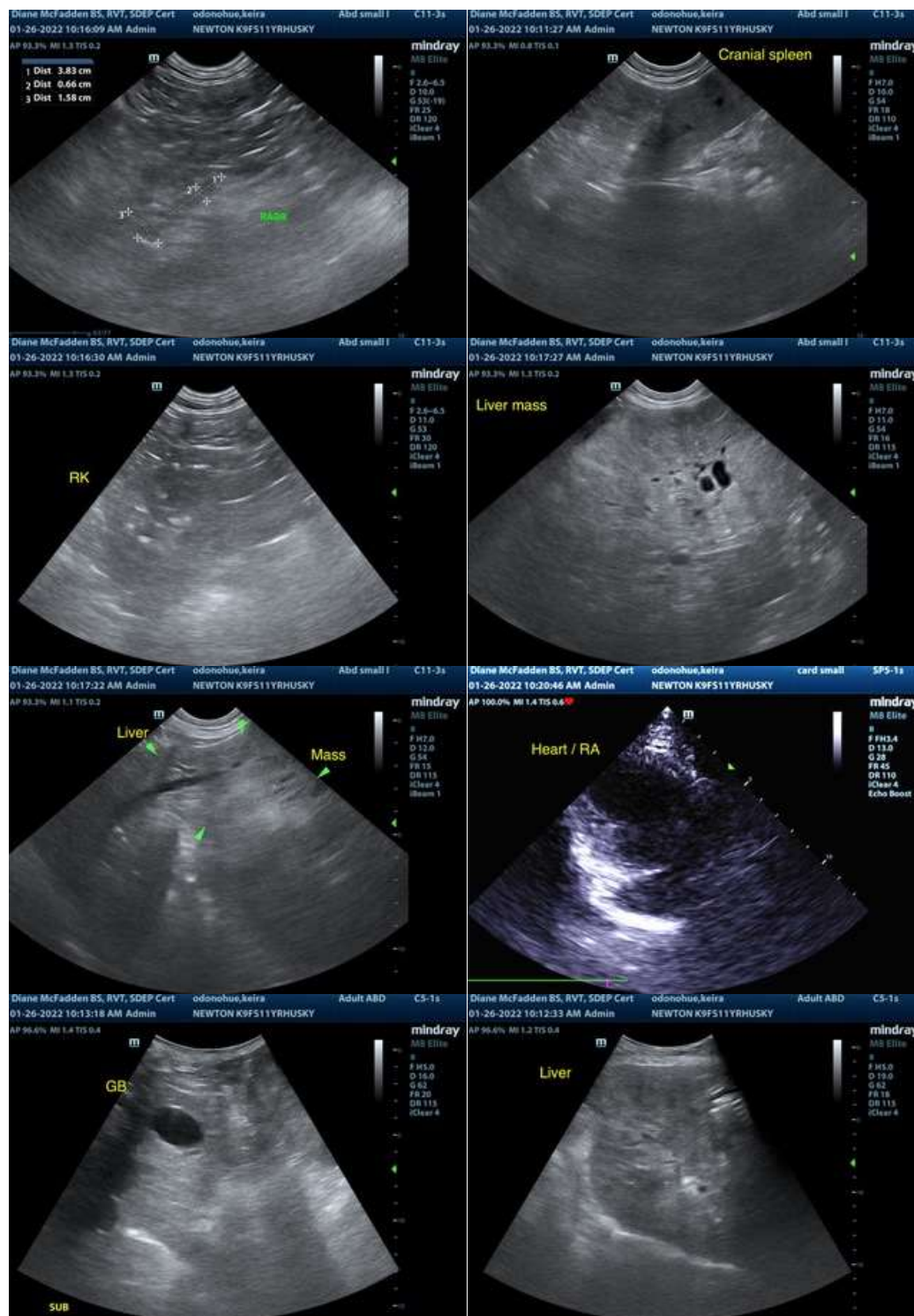
Dr. Wyman-Greenwald

**INVOICE**

13150

**DATE**

1/26/22





**PATIENT**

Keira ODonohue

**SPECIES**

Canine

**BREED**

Siberian Husky

**SEX**

FS

**AGE**

11 years

**WEIGHT**

N/A

**INTERPRETED BY**

R. McKenzie Daniel,  
DVM, DABVP  
(Canine and Feline)

**IMAGING PERFORMED BY**

Diane McFadden

**HOSPITAL NAME**

Newton VH

**REFERRING VET**

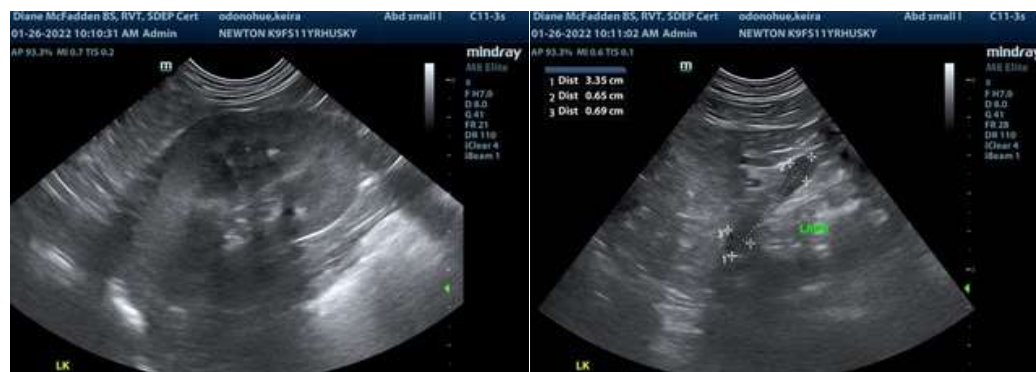Dr. Wyman-  
Greenwald

**INVOICE**

13150

**DATE**

1/26/22



The information and recommendations provided are based on the images presented by the referring veterinarian/sonographer. No evaluation can be communicated regarding pathology that was not visible in the image/video clips provided.

Thank you for this referral. If the clinical or image interpretation does not parallel your findings or if I can be of any further assistance please contact me.

**R. McKenzie Daniel, DVM, DABVP (Canine / Feline Practice)**  
info@SonoPath.com