



PATIENT

Desdeomona Durham

SPECIES

Feline

BREED

DSH

SEX

Spayed Female

AGE

1 Year

WEIGHT

7 Lbs.

INTERPRETED BY

R. McKenzie Daniel,
DVM, DABVP
(Canine and Feline)

**IMAGING
PERFORMED BY**

Rachel Runnells, RVT

HOSPITAL NAME

SVS Imaging KC

REFERRING VET

Dr. Snyder

INVOICE

13643

DATE

1/26/22

PRESENTING CLINICAL SIGNS

History: Spayed in November 2021. Was a stray before then. Since then has had intermittent vomiting. Cerenia gave temporary relief. Treated with Metronidazole - did not help much. Bloodwork prior to spay was normal. Radiographs taken at another hospital - lots of ingesta/fecal matter seen, but nothing else abnormal.

ULTRASONOGRAPHIC EXAMINATION OF THE ABDOMEN

Urinary System

The urinary bladder, trigone, cystourethral junction, and visible pelvic urethra to a depth of 2.0 cm exhibited normal thickness and tone. Anechoic urine was present in the lumen with no uroliths or sediment. The ureteral papillae were normal. The ureters were not visible which is normal. No evidence of inflammatory or neoplastic changes were noted. Aortic trifurcation was normal.

Normal size and margination was present in the kidneys. A normal 1:3 cortex / medulla ratio and normal corticomedullary definition were maintained. The echogenicity of the cortex was similar to or slightly less than normal liver parenchyma while the medulla echogenicity was hypoechoic to the cortex with no evidence of pelvic dilation. The left kidney measured 3.7 cm in length. The right kidney measured 3.8 cm in length.

Adrenal Glands

The left adrenal gland was uniform in size and contour with a uniformly hypoechoic parenchyma. The left adrenal gland measured 0.46 cm.

The right adrenal gland exhibited nonspecific mild prominent size, measuring 0.57 cm. No overt evidence of pathology in the right adrenal gland, likely patient variant.

Spleen

The spleen exhibited a finely textured and homogenous parenchyma which was hyperechoic to the liver and renal cortical parenchyma. The capsule was smooth and regular without apparent expansion. The splenic vasculature at the hilus was normal in volume with no evidence of congestion or thrombosis. Acute to chronic inflammatory, neoplastic, or benign parenchyma changes were not noted.

Liver

The liver was subjectively normal in size, structure, and contour. The liver parenchyma was uniform and hypoechoic to the spleen with a mild coarse echotexture. The hepatic and portal vasculature were normal in appearance without signs of congestion. The gallbladder was non-distended in size with thin walls and primarily anechoic luminal content. The cystic and common bile ducts were normal.

Gastrointestinal

The visualized gastric walls were sonographically normal. The lumen of the stomach contained moderate, exhibiting progressive distal acoustic shadowing ingesta without signs of obstruction or foreign material. The ventral gastric body wall measured 0.24 cm.

The small intestine exhibited wall layering and primarily maintained 1:3 muscularis to mucosa ratio with subjective propensity for mildly prominent muscularis layer yet without evidence of mural hypertrophy or loss of intestinal wall layering. The duodenum wall measured 0.30 cm. The jejunum wall measured



PATIENT

Desdeomona Durham

0.29 cm. The ileocolic wall measured 0.38 cm. Segmental jejunal chyme was present without evidence of mechanical or metabolic ileus.

Normal visible colon wall layers were present with apparent formed feces in lumen.

SPECIES

Feline

Pancreas

The left limb of the pancreas was normal in size and contour with subtle hypoechoic to heterogeneous parenchyma compared to adjacent omentum.

BREED

DSH

Free Abdomen

No evidence of lymphadenopathy or peritoneal effusion was present.

SEX

Spayed Female

ULTRASONOGRAPHIC FINDINGS

- Gastric ingesta
- Possible low-grade inflammatory enteropathy
- Subtle hypoechoic left pancreas

AGE

1 Year

INTERPRETATION OF THE FINDINGS & FURTHER RECOMMENDATIONS

WEIGHT

7 Lbs.

The appearance of the small intestine is compatible with infiltrative enteropathy. Primary considerations may include inflammatory infiltrative enteropathy such as IBD or neoplastic infiltrative enteropathy with round cells such as lymphoma or mast cell disease among potential etiologies. Dry form FIP may also present in this manner. Diagnosis would require biopsies for histology, obtained either via endoscopy or, ideally, full thickness biopsies via laparotomy. A GI Panel to include PLI/TLI/Cobalamin/Folate is recommended. If additional diagnostics are not elected, empirical medical therapy for IBD, which may include a canned limited antigen or hydrolyzed diet, cobalamin supplementation (250 mcg SQ once weekly for 4-6 weeks initially, then every 2-4 weeks), and Prednisolone at lowest effect dose to control clinical signs along with as needed gastrointestinal support would be reasonable. Minor potential for indistinct hairball density in the stomach cannot be definitively excluded, if previous history of hairballs.

INTERPRETED BY

R. McKenzie Daniel,
DVM, DABVP
(Canine and Feline)

IMAGING PERFORMED BY

Rachel Runnells, RVT

HOSPITAL NAME

SVS Imaging KC

REFERRING VET

Dr. Snyder

Subjectively, the small intestine exhibited subtle mural changes, which may suggest low-grade inflammatory enteropathy given the patients clinical signs or if evidence of weight loss. Dietary intolerance/food hypersensitivity, occult parasitism (if the patient is indoor/outdoor) may also be playing a role in the vomiting. Conservatively, limited protein or hydrolyzed diet with as needed gastrointestinal supportive care could be considered with assessment of the clinical response. Potential for low-grade pancreatic inflammation possible yet not definitive. Further assessment, including GI panel, to include PLI, TLI, cobalamin and folate may be considered. Sonographic reassessment of the gastrointestinal tract and pancreas, to assess for progressive inflammatory changes may be considered if clinical signs persist and/or nonresponsive to dietary and conservative therapy.

INVOICE

13643

DATE

1/26/22



PATIENT

Desdeomona Durham

SPECIES

Feline

BREED

DSH

SEX

Spayed Female

AGE

1 Year

WEIGHT

7 Lbs.

INTERPRETED BY

R. McKenzie Daniel,
DVM, DABVP
(Canine and Feline)

IMAGING PERFORMED BY

Rachel Runnells, RVT

HOSPITAL NAME

SVS Imaging KC

REFERRING VET

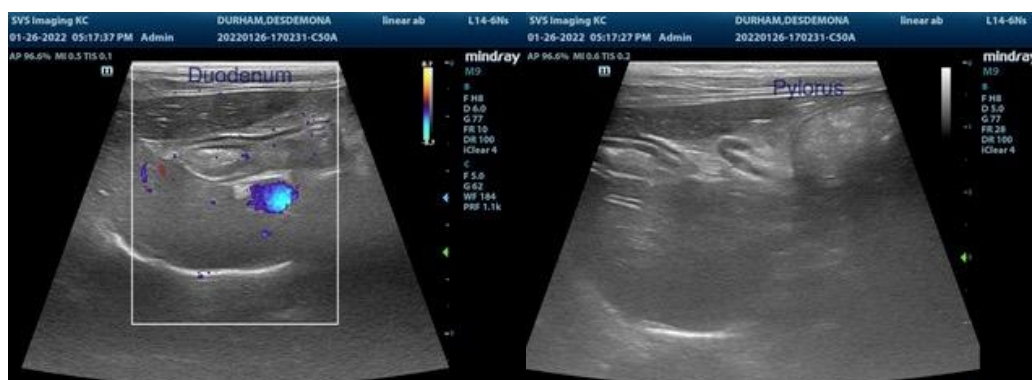
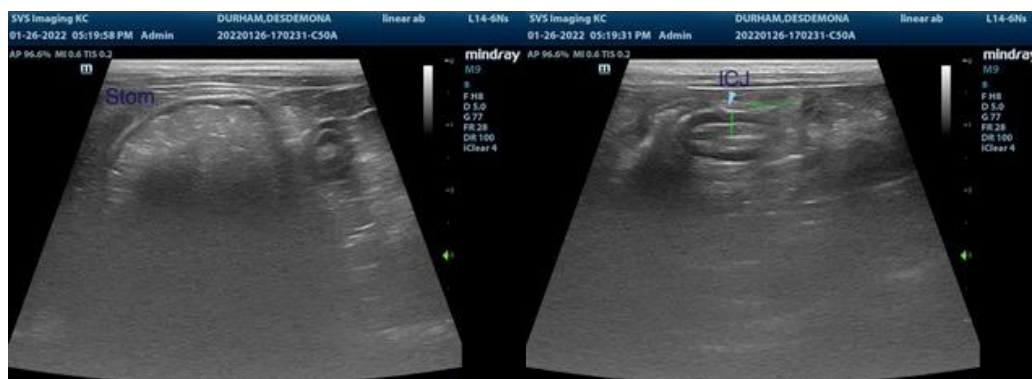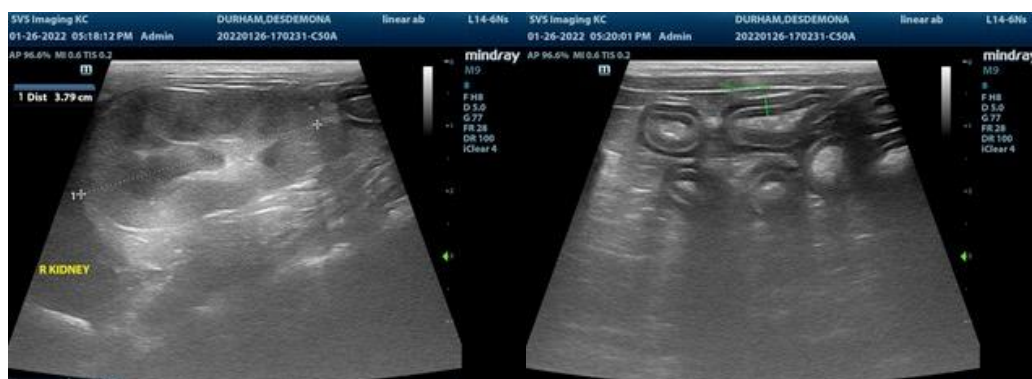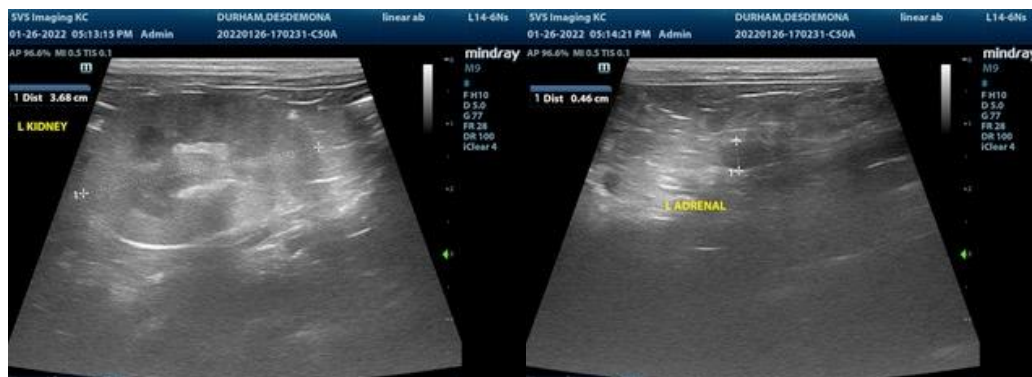Dr. Snyder

INVOICE

13643

DATE

1/26/22





PATIENT

Desdeomona Durham

SPECIES

Feline

BREED

DSH

SEX

Spayed Female

AGE

1 Year

WEIGHT

7 Lbs.

INTERPRETED BY

R. McKenzie Daniel,
DVM, DABVP
(Canine and Feline)

IMAGING PERFORMED BY

Rachel Runnells, RVT

HOSPITAL NAME

SVS Imaging KC

REFERRING VET

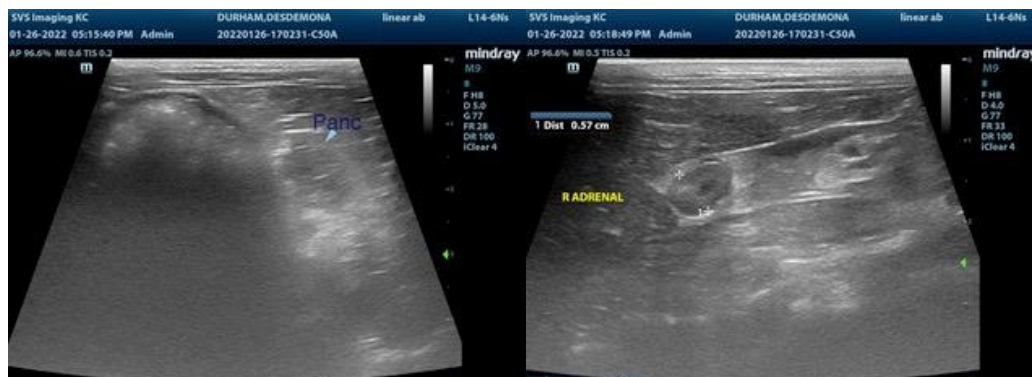Dr. Snyder

INVOICE

13643

DATE

1/26/22



The information and recommendations provided are based on the images presented by the referring veterinarian. No evaluation can be communicated regarding pathology that was not visible in the image/video clips provided.

Thank you for this referral. If the clinical or image interpretation does not parallel your findings or if I can be of any further assistance please contact me.

R. McKenzie Daniel, DVM, DABVP (Canine / Feline Practice)
info@SonoPath.com